

## Second Mesiobuccal and Distobuccal Canal in Maxillary Primary Second Molar. A Case Report

### Abstract:

Disparity in number of root canals were reported by different authors in permanent teeth but our knowledge is still at infancy about pulpal configuration of primary teeth, so the aim of this case report is to update our clinical proficiency in finding extra canals in maxillary primary second molar to prevent endodontic failure.

Usually upper primary molars is bounded with 3 canal i.e. Mesiobuccal, distobuccal and palatal. Occasionally one can find fourth and fifth canal i.e. Second mesiobuccal and second distobuccal canal respectively. So this case report summarises same.

**Key-words:** pulpectomy, endodontic failure, second mesiobuccals canal, second distobuccal canal.

### Introduction:

Caries is the most common etiological factor leading to pulpal involvement, which necessitates its treatment to preserve the integrity of dental tissues.[1] The main objective of doing pulpectomy in primary teeth is to relieve pain, disinfect the root canal, restore the function and prevent reinfection. Primary teeth have a thinner layer of mineralized tissue between the external and interior surfaces of teeth than permanent teeth, allowing bacteria to readily penetrate the pulp.[2] Thus, to achieve clean, disinfected, and 3-dimensionally obturated root canal systems, clear knowledge of the root morphology and canal anatomy is essential.

Many challenges faced during pulpectomy may be directly attributed to inadequate understanding of the canal morphology, Undetected extra roots or root canals due to the unique internal geometry of the pulp cavity and features which are not frequently found in permanent teeth, such as connections involving furcation and horizontal anastomosis. Root canal therapy in primary teeth is hence regarded as exceedingly complex in primary teeth.[2,4]

### A case report:

A 6-year-old female patient reported to the OPD; Department of Pediatric and Preventive Dentistry at I.T.S. Dental College Muradnagar Ghaziabad complaining of pain in her upper and lower back tooth region since 2 weeks. On examination it was observed that patient was having high caries index as there were multiple carious teeth involved. On subjecting to radiographic examination, it was observed that there was a radiolucency involving enamel dentin and pulp which was interpreted to chronic irreversible pulpitis.

Careful examination of the radiographs also revealed the possibility of more than 1 distal and mesial root canals.

<sup>1</sup>NAMAN PAHUJA, <sup>2</sup>SHIVANI MATHUR,  
<sup>3</sup>VINITA GOEL, <sup>4</sup>SAAKSHI GOEL

<sup>1-4</sup>Department of Pediatric and Preventive Dentistry,  
ITS CDSR Muradnagar, Ghaziabad

**Address for Correspondence:** Dr. Naman Pahuja

Postal address :

H. No. 913, Sector 15 Sonipat, Haryana 131001

Email : naman.pahuja23@gmail.com

**Received :** 13 July., 2022, **Published :** 31 March, 2023

**How to cite this article:** Pahuja, N. (2022). Second Mesiobuccal and Distobuccal Canal in Maxillary Primary Second Molar. A Case Report. UNIVERSITY JOURNAL OF DENTAL SCIENCES, 9(1). 48-51

### Access this article online

**Website:**  
www.ujds.in

**DOI:**  
<https://doi.org/10.21276/ujds.2023.9.1.9>

### Quick Response Code



The tooth was anesthetized, and access to the pulp chamber was achieved using a round diamond bur (no. 4; MANI Inc., Tochigi-ken, Japan). Clinical evaluation of chamber floor confirmed the presence of 5 root canal orifices, 2 located to the mesial, 2 distal AND 1 palatal. Patency of the canals was achieved using 10 number k files, working length estimation was done using IOPA. Biomechanical preparation was done using rotary nitiprotaper (Dentsply Maillefer, Ballaigues, Switzerland) with crown down technique, copious amount irrigation was done using 1 % sodium hypochlorite and canals were then dried with paper points followed by obturation using Metapex(Figure -1).

Post endodontic restoration was done with Glass Ionomer Cement followed by placement of stainless steel crown on the same visit (figure -2). Post operative instructions were given to the patient and was recalled after 3 days for follow-up.

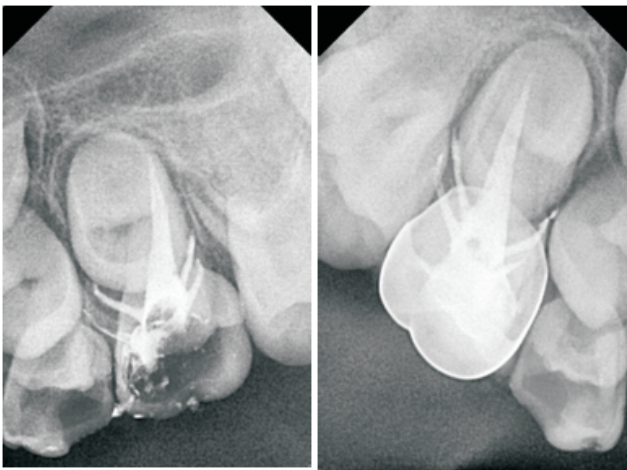


Figure 1

Figure 2

### Discussion:

Usually, maxillary deciduous second molars have 3 roots comprising of 3 to 4 canals. Failure of endodontic treatment has been attributed to an improper case selection, limitations of technique, root resorption, missed canal, inadequate chemical disinfection, overextended or an inadequate obturation and failure to provide an adequate coronal seal. This often leads to an exacerbation of infection and is visible as a radiolucency in the inter-radicular area.<sup>5</sup> The cited reasons are a thin dentinal floor, porous pulpal floor and accessory canals.

Accessory canals form pulpal-periodontal connections, transmitting infection from pulp to periodontium and vice versa leading to failure of the endodontic treatment and an

unpleasant experience for the child. Such canals remain untreated because of an inadequate anatomical knowledge, unfamiliar nature and an inadequate access. It is hence important to ascertain the nature of these elusive canals for a successful endodontic therapy.

A practical pulpectomy technique for the primary teeth should include the following:

- 1) Fast procedure with short treatment time and minimal number of appointments.
- 2) Effective debridement of the root canal without weakening the tooth structure or endangering the underlying permanent teeth.
- 3) Minimal procedural complications.
- 4) Maintaining tooth function until it is naturally exfoliated.[8]

Negotiation and thorough instrumentation of bizarre and tortuous canals encased in roots programmed for physiological resorption are the main challenges for pulpectomy.[9]

Mechanical preparation of primary teeth utilizing Ni-Ti rotary files was first done by Barr et al.[10] They concluded that the use of Ni-Ti rotary files for root canal preparation in primary teeth was cost effective, faster, and resulted in consistently uniform and predictable fillings. Several investigators have reported the advantages of preparation with rotary Ni-Ti instruments over the manual method for both experienced and inexperienced operators.[8] Silva et al. reported that Ni-Ti rotary preparation for extracted teeth was faster than hand preparation but the canals were not as clean.[12]

It has been reported that instruments with progressive tapers can shape canals more quickly than constant taper instruments.[14] In the ProTaper system, the shaping files (S) have an increasing taper in the coronal direction, whereas the finishing files (F) have a decreasing taper. It has been claimed that the increasing taper instruments have enhanced flexibility in the middle region and at the tip, and that the decreasing taper instruments provide a larger taper in the important apical region but make them stiff.[13]

Shashikiran et al. also compared the Ni-Ti rotary PROFILE and K files hand instrumentation on root canal preparation of primary and permanent molars for their efficacy in preparation time, instrumentation failure, and shaping the

canals. They concluded that PROFLE 0.04 taper 29 series prepared canal rapidly than conventional K files.[15]

In this tooth metaphex was pushed beyond the canal in one of the canals present. Extension of the material beyond the apex has, been advocated by some authors due to benefits of calcium hydroxide. Souza et al suggested that the action of calcium hydroxide beyond the apex may be fourfold

- 1) Anti-inflammatory activity
- 2) Neutralization of acid products: alkaline pH neutralizes the lactic acid secreted by osteoclasts
- 3) Activation of alkaline phosphatase which is postulated to play an important role in hard tissue formation.
- 4) Antibacterial action<sup>[6]</sup>

Sahli proposed that the necrotizing ability of calcium hydroxide may destroy any epithelium present thereby allowing a connective tissue invagination into the lesion with ultimate healing [7]

Wither spoon et al stated that failure to locate all canal systems of a tooth contributes significantly to unsuccessful endodontic treatment, all measures available to the clinician to maximize canal identification should be used.[11]

### Conclusion:

Anatomic variation in the number of roots and root canals can occur in any tooth. Although such cases occur infrequently, dentists should be aware of them when considering endodontic treatment. Examination of clear radiographs taken from different angles and careful evaluation of the internal anatomy of teeth are essential for successful treatment. Root canal treatment is likely to fail if extra roots or root canals are not detected.

### References:

1. Reddy NV, Daneswari V, Patil R, et al. Three-dimensional assessment of root canal morphology of human deciduous molars using cone beam computed tomography: an in vitro study. *Ind J PedodRehabil* 2018;3(1):36–41. DOI: 10.4103/ijpr.ijpr\_21\_17.
2. Yang R, Yang C, Liu Y, et al. Evaluate root and canal morphology of primary mandibular second molars in Chinese individuals by using cone-beam computed tomography. *J Formos Med Assoc* 2013;112(7):390–395. DOI: 10.1016/j.jfma.2012.10.008

3. Ozcan G, Sekerci AE, Cantekin K, et al. Evaluation of root canal morphology of human primary molars by using CBCT and comprehensive review of the literature. *Acta OdontolScand* 2016;74(4):250–258. DOI: 10.3109/00016357.2015.1104721.
4. Tannure PN, Barcelos R, Portela MB et al. Histopathologic and SEM analysis of primary teeth with pulpectomy failure. *Oral Surg Oral Med Oral Pathol Oral RadiolEndod* 2009; 108: e29–e33.
5. Paras LG, Rapp R, Piesco NP et al. An investigation of accessory foramina in furcation areas of human primary molars: part 1. SEM observations of frequency, size and location of accessory foramina in the internal and external furcation areas. *J Clin Pediatr Dent* 1993a; 17: 65–69.
6. Kalaskar R, Tiku A, Damle SG. Periapical repair and apical closure of a pulpless tooth using calcium hydroxide. A case report. *J Ind Soc Ped Prev Dent*. 2004;22:158-161.
7. Sahli CC. Radiographic and histological study of a case of apexification in a human molar. *Rev EspEndodonia*. 1989;7:101-106.
8. Nagaratna P.J., Shashikiran N.D., Subbareddy V.V. In vitro comparison of Ni Ti rotary instruments and stainless steel hand instruments in root canal preparations of primary and permanent molar. *J. Indian Soc. Pedod. Prev. Dent*. 2006;24:186–191.
9. Ahmed H. Anatomical challenges, electronic working length determination and current developments in root canal preparation of primary molar teeth. *Int. Endod. J*. 2013;46:1011–1022.
10. Barr E.S., Kleier D.J., Barr N.V. Use of nickel-titanium rotary files for root canal preparation in primary teeth. *Pediatr. Dent*. 2000;22(1):77–78. PMID: 10730297
11. Witherspoon DE, Small JC, Regan JD. Missed canal systems are the most likely basis for endodontic retreatment of molars. *Tex Dent J*. 2013 Feb;130(2):127–39. PMID: 23930451.
12. Silva L.A., Leonardo M.R., Nelson-Filho P., Tanomaru J.M. Comparison of rotary and manual instrumentation techniques on cleaning capacity and instrumentation time in deciduous molars. *J. Dent. Child*. 2004;71:45–47.
13. Bergmans L., Van Cleynenbreugel J., Beullens M., Wevers M., Van Meerbeek B., Lambrechts P. Progressive versus constant tapered shaft design using NiTi rotary instruments. *Int. Endod. J*. 2003;36:288–295

14. Veltri M., Mollo A., Mantovani L., Pini P., Balleri P., Grandini S. A comparative study of Endo flare-Hero Shaper and MtwoNiTi instruments in the preparation of curved root canals. *Int. Endod. J.* 2005;38:610–616.
15. Shashikiran N.D. In vitro comparison of Ni Ti rotary instruments and stainless steel hand instruments in root canal preparation of primary and permanent molars. *J. Indian Soc. Pedod. Prev. Dent.* 2006;24:186–191.