

# Multiple Treatment Modalities for Management of Missing Molars : A Case Series

**Abstract:**

Cases with missing molars do need a well-executed treatment plan and a thorough knowledge of biomechanics to treat which usually leads to its prosthetic rehabilitation instead of orthodontic management by the orthodontists. Its orthodontic management is not only time consuming but also requires patience and proper treatment strategy involving right choice of appliance and auxiliaries to achieve the best possible results. Here in this case series we have tried to show different treatment modalities in cases with missing permanent molars leading to ideal post treatment outcomes.

**Key-words:** .....

**Introduction:**

The need for tooth extractions during orthodontic therapy is determined not only by the presence or absence of space in the dental arches, but also by the compromised teeth, desired final dental relation, and patient compliance.[1] The first molar has been identified as the tooth in the permanent dentition with the highest risk of caries.[2] The removal of such teeth, that were assumed to be the most susceptible to caries, has been thought to reduce the incidence of decay in the rest of the teeth.[3]

Teeth that have been extensively restored will enter the restorative loop and may need to be removed in the long run, thus it is better to opt for 1st molar extractions. Cases involving the extraction of permanent first molars are assumed to be more technically challenging to treat, because even a good outcome is a compromise in certain aspects. The operator's preference for premolar extraction cases or a lack of experience with molar extraction cases could explain why first molar cases are avoided.[4]

Most common associated problems after the removal of 1<sup>st</sup> molars are tipping of two neighboring teeth, supra eruption of the antagonist, dual drift (vertical, horizontal), space reduction

by tipping, or total space closure. Also pneumatization of the sinus and reduction in the width of the alveolar ridge is commonly observed.[5]

Space regaining or space closure are two treatment alternatives open to the orthodontist in the event of missing first molars. The space could be regained for implant placement, auto transplantation and prosthetic rehabilitation, while the other related malocclusions can be corrected by closing the space.[5,6] Space regaining is indicated when the wisdom tooth is absent so that the upper 2<sup>nd</sup> molar is not left without an antagonist.[6]

**<sup>1</sup>KALPIT SHAHA, <sup>2</sup>MANISH GOYAL, <sup>3</sup>MUKESH KUMAR, <sup>4</sup>HARIPRIYA NONGTHOMBAM, <sup>5</sup>PARUL PRIYA**

<sup>1-4</sup>Department of Orthodontics and Dentofacial Orthopaedics, Teerthanker Mahaveer Dental College, Moradabad

**Address for Correspondence:** Dr. Kalpit Shaha  
Department of Orthodontics and Dentofacial Orthopaedics,  
Teerthanker Mahaveer Dental College, Moradabad  
Postal Add. : B/805, Green Orchid Apartments, New  
Moradabad, Moradabad, Uttar Pradesh, India 244001  
Email : drkalpishaha@gmail.com

**Received :** 22 June, 2021, **Published :** 31 Dec., 2022

**How to cite this article:** Shaha, K., Goyal, M., Kumar, M., Nongthombam, H., & Priya, P. (2022). Multiple Treatment Modalities for Management of Missing Molars – A Case Series. UNIVERSITY JOURNAL OF DENTAL SCIENCES, 8(4).

Access this article online	
<b>Website:</b> www.ujds.in	<b>Quick Response Code</b> 
<b>DOI:</b> https://doi.org/10.21276/ujds.2022.8.4.12	

The main advantage of space closure with prosthetic rehabilitation resides in the fact that the whole treatment can be finished immediately after completion of orthodontics. The option of replacing the first molar with the second molar for closure of the orthodontic space is appealing because it avoids the patient's reliance on a permanent restoration.<sup>3</sup> When possible, it must be systematically preferred because better long term outcomes can be achieved.

In this article, four case reports are presented in which first molars were already extracted or were decided to be extracted for orthodontic treatment.

### CASE 1

A 17-year-old female patient reported forwardly placed teeth in front region of her upper jaw. Intraoral examination depicted an end on molar relationship with class I canine relation on right side and a Class I molar relation with class I canine relation on left side, 6 mm of overjet and 5 mm of an overbite. The patient had congenitally missing 15 and 25, retained 65, root canal treated 46, proclined upper and lower anteriors, spacing in upper anteriors and crowding in lower anteriors (Fig. 1).

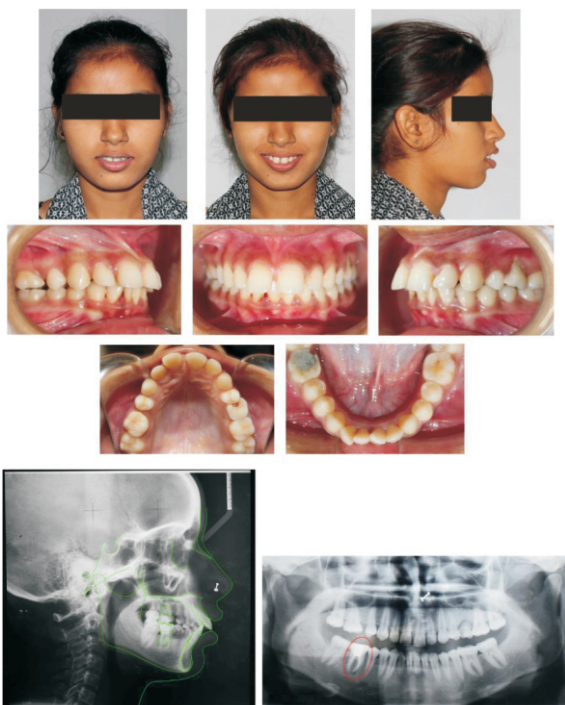

Fig. 1 17-year-old female with retained deciduous upper left second molar (65) and congenitally missing upper second premolars (15,25).

The panoramic radiograph clearly shows the presence of a periapical abscess i.r.t. 46. So, we decided to extract 46 and replace it with an implant since the 3<sup>rd</sup> molar was missing and we couldn't opt for protraction of the second molar. Also, we planned extraction of 65 and 35. Our objectives were to achieve class II molar and class I canine relationship on right side. Maintain class I molar and canine relationship on left side so as to finish the case in Class II subdivision on the right side.

The patient was then advised extraction of 65 and pre-adjusted edgewise appliance (0.022"x0.028" slot MBT prescription, 3M Unitek) was bonded in upper arch. Leveling and alignment was initiated with 0.014" NiTi archwire followed by SS wires of increasing thickness. After 2 months of leveling and alignment, extraction of 35 was done followed by lower bonding. Leveling and alignment was initiated with 0.012" NiTi archwire. After 8 months, E-chain was given on 0.017 x 0.025" rectangular SS wire for space closure on the upper left side. The space from extraction of 35 was utilized to decrowd the mandibular anteriors while the space from 65 was used for retraction so as to end in class I molar relationship. Also, NiTi open coil spring was inserted on the 0.017 x 0.025" SS lower arch wire in the fourth quadrant to gain space for implant prosthesis in the region of 46 which was inadvertently lost during leveling and alignment (Fig 2).

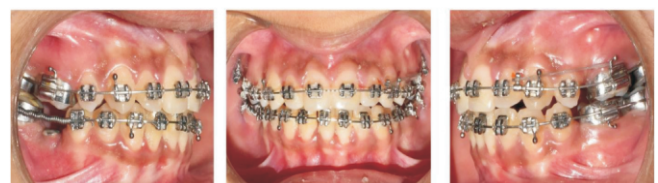

Fig. 2 Open coil spring for space gaining for implant prosthesis in lower right first molar region.

An implant (Adin Dental Implant Solutions, Alon Tavor, Israel) was placed in the extraction space of 46. After 24 months of active treatment, class II molar and class I canine relationship on right side was achieved while maintaining class I molar and class I canine relationship on left side with closure of all spaces. The settling of occlusion was carried out on 0.012" NiTi for 3 months to achieve good functional occlusion. Fixed lingual retainers were given in both the arches (Fig. 3).

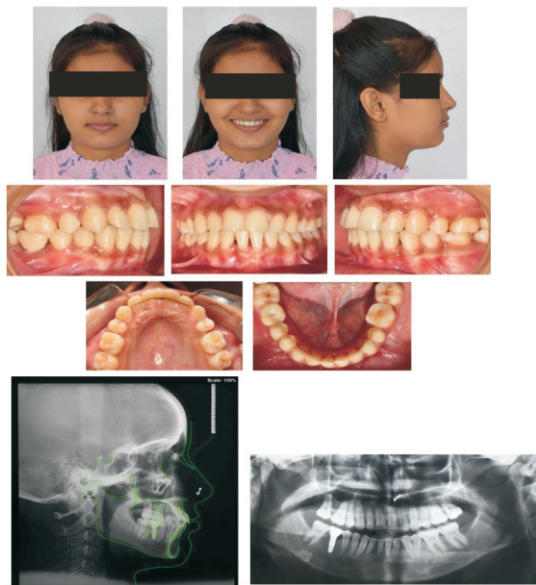


Fig. 3 Patient after 27 months of treatment finished in class II molar relation on right side and class I molar relation on left side with class I canine relation bilaterally.

### CASE II

A 23 years old female patient reported irregularly placed teeth in front region of her upper and lower jaw. She had root stumps in respect to 46 and missing 26. She exhibited 2mm of overjet and overbite, crowding in her anterior region with crossbite in respect to 12 and 22. Development of third molars were almost completed in all four quadrants, and exhibited optimal bone support for orthodontic therapy (Fig. 4).

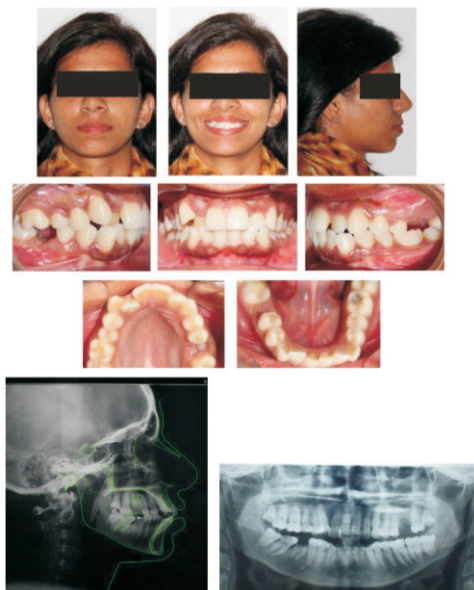

Fig. 4 23-year-old female patient with missing upper left first molar and root stumps of lower right molar.

Treatment objectives included resolving of crowding; leveling, aligning, and coordination of both the arches for better functional occlusion; and achievement of esthetic facial profile with ideal overjet and overbite. The treatment plan involved extraction of 46 (root stump) along with 14, and 34 to end up in class II molar relationship on right and class III on left side.

The banding and bonding of upper arch was done with MBT 0.022" x 0.028" slot post 14 extraction. Leveling and alignment was initiated with 0.014" NiTi arch wire and continued till 0.016" SS. A NiTi open coil spring was given to gain space for the blocked out laterals. Bite was raised and then piggy back with 0.012" NiTi wire was given for alignment of 12 & 22.

Patient was then referred to department of oral surgery for the extraction of 34, but in addition, extraction of 44 was done by mistake due to miscommunication with oral surgeon. This event changed our treatment plan and final outcome, as we had to manage this additional space. Thus, we decided to end up in class I molar relationship on the right side instead of Class II. Now, the lower arch was bonded and leveling alignment was initiated and gradually reached to 0.019" x 0.025" SS wire. After 10 months of leveling and aligning, space closure was done initially with type II active tieback followed by class II elastics (5/16" 4.5 oz; Fig. 5) for 11 months. Uprighting spring (0.019x0.025" TMA) was given on mesially tipped 48 with simultaneous mesialization of 47 (Fig. 6) for 5 months.

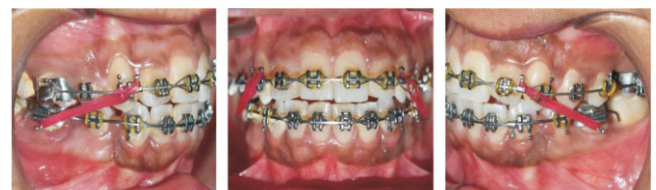

Fig. 5 Mesialization of 47 with class II elastics.

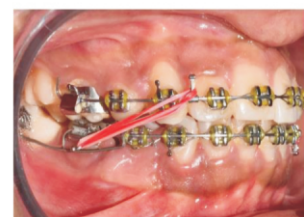


Fig. 6 Uprighting of 48 with a 0.019x0.025" TMA uprighting spring.

Meanwhile, the patient decided to get married and thus she demanded the removal of brackets. She was satisfied with the treatment as significant amount of space closure was achieved. Unfortunately, we had to debond the case and fixed lingual retainers were given in both the arches. (Fig. 7)

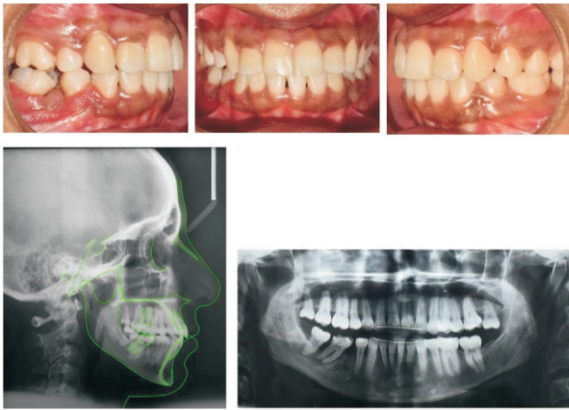


Fig. 7 Patient after early debonding due to marriage with some space still remaining between 44 and 47.

But, still our objectives were not fully accomplished as there was some space remaining mesial to the second molar. We gave her an alternative way of space closure such that it won't affect her marriage proceedings and also help us in completing the orthodontic treatment. Thus, mesialization of 46 and 47 for the remaining space closure was initiated by miniscrew placement between 43 and 45. A hook was formed using 0.019×0.025" SS and engaged in molar tube so that the force can be applied near to the center of the resistance of molar for bodily movement (Fig. 8).

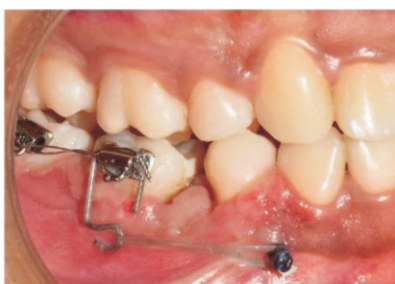

Fig. 8 Mesialization of 46 and 47 by miniscrew placement between 43 and 45 with a hook engaged in molar tube formed using 0.019×0.025" SS.

After successful closure of all spaces, Class I molar relation on right side and Class III molar relation on left side was achieved with Class I canine relation bilaterally in a total of 32 months of treatment. Ideal overjet and overbite was achieved

with good intercuspation and esthetic soft tissue profile (Fig. 9).

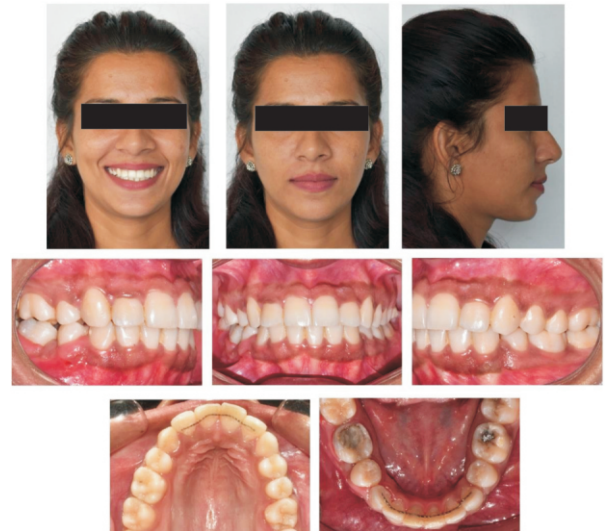

Fig. 9 Patient after 32 months of treatment finished in class I molar relation on right side and class III molar relation on left side with class I canine relation bilaterally.

### CASE III

A 17-year-old female patient reported with the main concern being irregularly placed teeth in front region of upper jaw. Intraoral examination depicted a Class I molar relationship on the left side and missing 16, end on canine relationship bilaterally with 11 mm of overjet and 3 mm of an overbite of the upper incisors (Fig. 10).

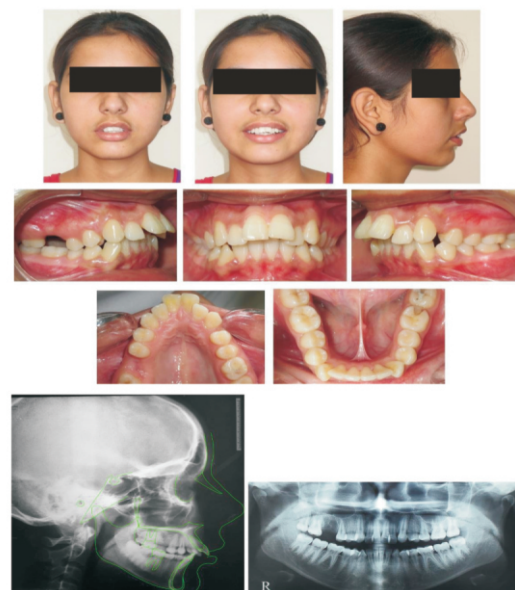


Fig. 10 17-year-old female patient with missing upper right first molar and reverse smile arc.

The treatment plan was extraction of all 1st premolars and replace missing 16 with an implant. The extraction of all first premolars were done. Pre-adjusted edgewise appliance (0.022"x0.028" slot MBT prescription, 3M Unitek) was bonded in both upper and lower arches. Leveling and alignment was initiated with 0.012" NiTi archwires and completed in 8 months using 0.016" x 0.022" nickel-titanium. Midway during the treatment, the patient refused for the prosthetic implant placement since she couldn't afford the cost of an implant. So, we decided to mesialize 17 and 18 instead.

After 8 months of treatment, retraction was initiated using single key hole loop fabricated using 0.018 x 0.025" SS wire. Differential alpha and beta bends on left side with equal alpha and beta bends were given on right side during the activation so that simultaneous retraction of anteriors and protraction of 17 could be achieved (Fig 11).

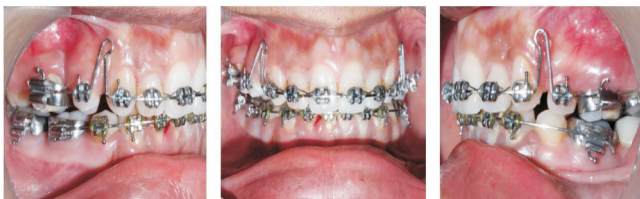

Fig. 11 Key hole loop used for retraction as well as protraction in the 2<sup>nd</sup> quadrant.

After the retraction was complete the remaining mesialization was done using an omega loop with differential alpha and beta bends also fabricated using 0.018 x 0.025" SS wire (Fig. 12).

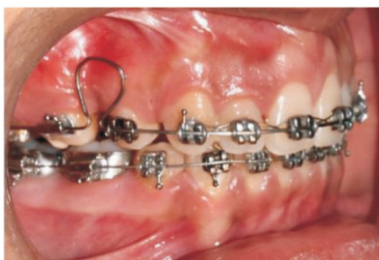

Fig. 12 Omega loop for closure of the remaining space mesial to the molar.

The mesialization was approximately completed in 10 months. Ultimately, class II elastics on right side and class III elastics on left side for 4 months were given to correct the

midline shift. After 22 months of active treatment, a bilateral class I molar and canine relationship was achieved with closure of all spaces. Discoloration was seen in respect to 36 due root canal treatment for which a crown has been advised. Fixed lingual retainers were given in both the arches (Fig. 13).

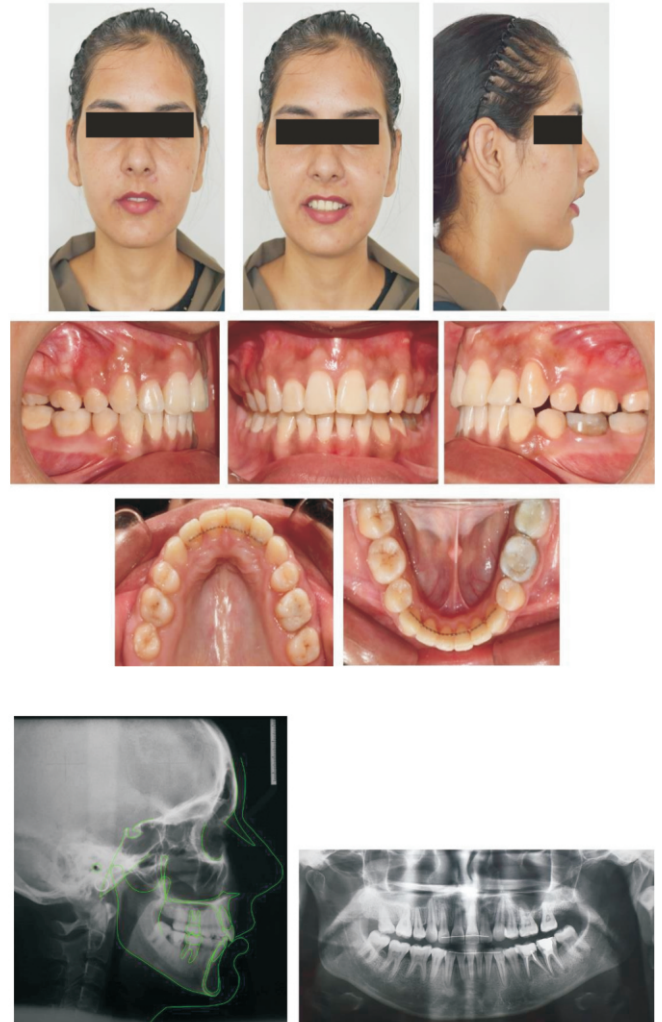

Fig. 13 Patient after 22 months of active treatment finished in class I molar relation on right side and class III molar relation on left side with class I canine relation bilaterally.

#### CASE IV

A 20-year-old female patient reported with the main concern being irregularly placed teeth in front region of both upper and lower jaw. Intraoral examination depicted an end on molar relationship on the right side with 7 mm of overjet and 2 mm of an overbite, crowding in anterior region of both upper and lower arches with crossbite in relation to 12, scissor bite in relation to 25, missing 26 and carious 16 (Fig. 14).

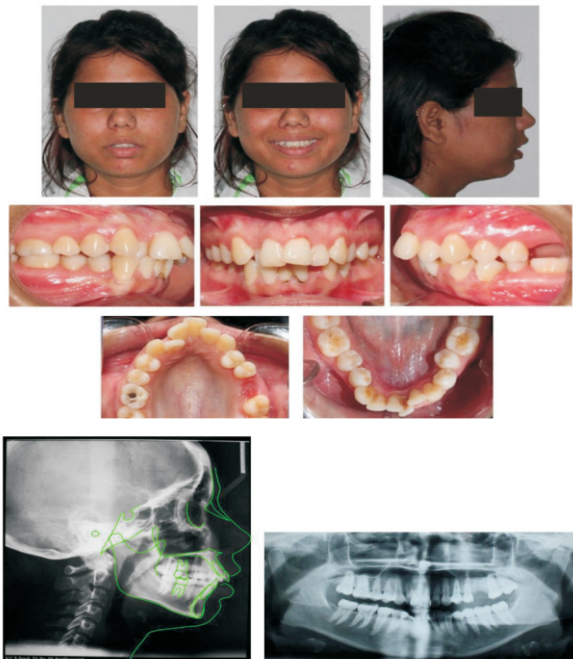


Fig. 14 A 20-year-old with crossbite in relation to 12, missing 26 and carious 16.

The treatment of choice was extraction of all 1st premolars and replace missing 26 with an implant. But the patient couldn't afford the cost of an implant so we decided to use the extraction space for partial mesialization of the molar to finish in class I. Since it was a fresh extraction socket, mesial movement of the molar would have been relatively easy.

Restoration of 16 done along with the extraction of all first premolars were done. Pre-adjusted edgewise appliance (0.022"x0.028" slot MBT prescription, 3M Unitek) was bonded in both upper and lower arches. Leveling and alignment was initiated with 0.012" NiTi archwire continuing with SS wires of increasing thickness. After 10 months, retraction was done using TADs (1.5 x 8 mm; SK Surgical, Pune, Maharashtra, India) in order to provide critical anchorage. TAD failure occurred in the 3<sup>rd</sup> quadrant so we decided to retract using an E-chain (Fig 15).

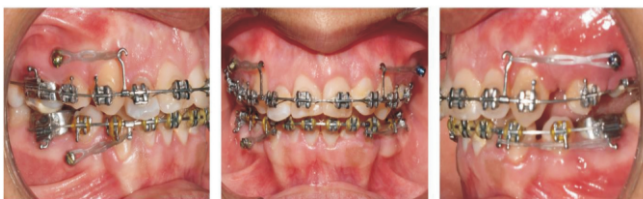

Fig. 15 Retraction done using TADs (1.5 x 8 mm; SK Surgical,

Pune, Maharashtra, India) to provide critical anchorage. TAD failure in the 3<sup>rd</sup> quadrant, retraction with an E-chain.

A double key hole loop fabricated using 0.018 x 0.025" SS wire was used for retraction as well as mesialization of the molar in 2<sup>nd</sup> quadrant. Differential alpha and beta bends were given on left side to generate a more retractive force than a protractive force (Fig 16).

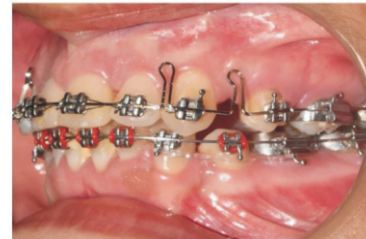


Fig.16 A double keyhole loop with equal alpha and beta bends for retraction of anteriors as well as protraction of posteriors.

The mesialization was approximately completed in 8 months. A torquing auxillary made of 0.014" AJ Wilcock was given to manage the crown inclination of the blocked out lateral incisors (Fig 17)

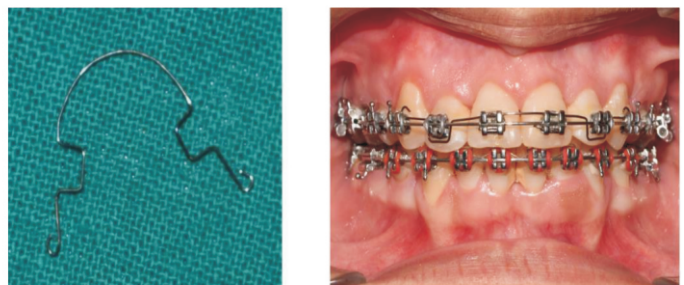


Fig. 17 A torquing auxillary made of 0.014" AJ Wilcock archwire to manage the labiolingual inclination of the blocked out lateral incisors.

The settling of occlusion was carried out on 0.014" NiTi to achieve good functional occlusion. Fixed lingual retainers were given in both the arches. After 24 months of active treatment, a bilateral class I molar and canine relationship was achieved with closure of all spaces. The patient didn't follow proper oral hygiene precautions during the lockdown period which led to the gingival recession in the lower anterior region which was also evident in the pretreatment lower occlusal photographs (Fig 14). Ideal overjet and overbite was achieved with good intercuspation and esthetic soft tissue profile (Fig 18).

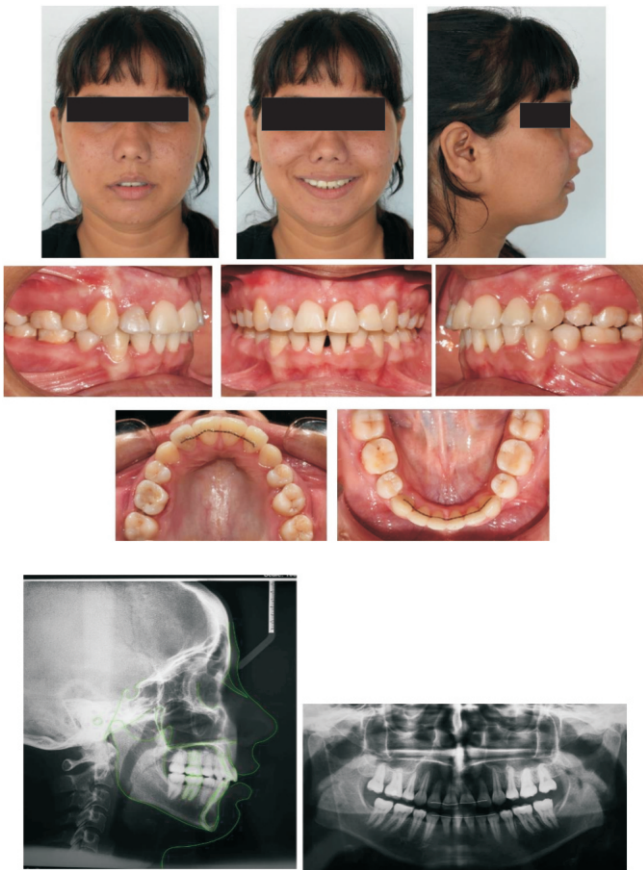

Fig. 18 Patient after 24 months of active treatment finished in class I molar and canine relation bilaterally.

**Discussion:**

Significantly damaged first molar have a good chance of going through a restorative process that will eventually lead to extraction. The longevity of a dilapidated molar intended to be preserved in a patient with wisdom tooth removal must be weighed against the orthodontic alternative including the removal of the dilapidated molar and retention of the wisdom tooth. Wisdom tooth agenesis in the compromised or extracted first molar's is an absolute contraindication for the orthodontic rehabilitation.[6] The existence of third molars in the missing molar quadrant is critical, or at the very least, there ought to be a strong probability of third molar eruption to provide a functional occlusal table.[1,7] If third molars are being used to replace second molars, the angulation, root developmental status, eruption space, and periodontal status of the mandibular third molars must all be assessed.<sup>8</sup> Therefore, in the 1<sup>st</sup> case we opted for prosthetic rehabilitation since there was a missing third molar in 4<sup>th</sup> quadrant while in the remaining cases we went for orthodontic rehabilitation.

The timing and necessity for molar extractions, can vary considerably depending on the patient's dental development, maxillomandibular crowding and relationships, and also the amount of overjet and overbite. The space created due to missing molar can be managed in following ways: pure retraction of anterior teeth, reciprocal traction and pure protraction of posterior teeth.[9] Because the first molar's mesiodistal width is so long, there are quite few cases of pure retraction of anteriors. Pure protraction of posteriors is the most complex aspect of tooth movement because the distance to be moved is the greatest. Thus, reciprocal traction is the simplest and mostly followed line of treatment. There has been a significant amount of confusion among the practitioners regarding the extraction pattern as well as the type of tooth movement in missing 1<sup>st</sup> molar cases. We have tried to compile the answers to these questions in Table 1.

Table 1. Clinical situations in case of missing molars

Sr. No.	Situations	Extraction pattern	End Result	
			Molar relation	Canine relation
1	Missing U6	All 4 extraction	Class I	Class I
2	Missing L6	U4	Class II	Class I
3	Missing U6	L4	Class III	Class I

U – upper; L – lower; 4,6 – tooth numbers

The benefits of molar protraction include ability to use the patient's natural dentition, avoid damage to the neighboring teeth undergoing prosthetic preparation, reduced pain or trauma from third molar extractions.[8] The thickness of mandibular cortical bone is greater than that of maxillary bone, thus rate of mandibular molar translation is nearly half that of maxillary molar translation. The radiographic density or cortical thickness of the resisting alveolar bone is inversely related to the rate of molar protraction.[10] Thus, it is preferable to opt for protraction of the molars in cases where the eruption of third molar is favorable. On comparing to young adults, adults have more resistance to orthodontic tooth movement and are more likely to lose alveolar ridge height, gingival recession, and root resorption, as well as have more problems retaining the closed space, resulting in decreased stability.[1] To overcome such problems, the orthodontists should increase the gap between activations and use an effective method to assure delivery of light forces so that the tissues involved get time to recuperate and soft tissue clefts, that have a tendency to open spaces, do not develop.[1]

### Conclusion:

Orthodontic treatment with first molar extraction in adult patients is technically more complex since the extraction of first molar gives extra space which is not easy to manage. There is always a lot of confusion in deciding whether this space should be maintained for a prosthetic replacement or should be closed orthodontically. If the decision is made to close the space orthodontically, it is still challenging to decide how much of the space should be used for retraction of the anteriors and for the protraction of the molars. Furthermore, treatment takes longer and requires greater control of orthodontic mechanics to reduce the side effects of space closure.

### References:

1. Dhole PM, Maheshwari DO. Orthodontic space closure using simple mechanics in compromised first molar extraction spaces: case series. *J Indian Orthod Soc.*2018;52:51-9
2. Ong DC-V, Bleakley JE. Compromised first permanent molars: an orthodontic perspective. *Aust Dent J.* 2010;55:2-14
3. Sabri R. Multidisciplinary management of permanent first molar extractions. *Am J Orthod Dentofacial Orthop.*2021;159:682-92.
4. Sandler JA, Atkinson R, Murray MA. For four sixes. *Am J Orthod Dentofacial Orthop.*2000;117:418-34.
5. Aghoutan H, Alami S, El-Aouame A, El-Quars F. Orthodontic Management of Residual Spaces of Missing Molars: Decision Factors, in *Human Teeth - Key Skills and Clinical Illustrations*, IntechOpen, 2019.
6. Bassigny F. What to do in case of a dilapidated or already extracted first molar? Justification for orthodontic option. *Rev OdontStomat.*2008;37:135-48.
7. Schroeder AM, Schroeder KD, Santos SJD, Leser MM. Molar extractions in orthodontics. *Dental Press J Orthod.*2011;16:130-57.
8. Baik UB, Kim RM, Yoon HK, Kook AY, Park HJ. Orthodontic uprighting of a horizontally impacted third molar and protraction of mandibular second and third molars into the missing first molar space for a patient with posterior crossbites. *Am J Orthod Dentofacial Orthop.* 2017;151:572-82.
9. Baik UB. Molar protraction: orthodontic substitution of missing posterior teeth. In *Kim K. (eds) Temporary Skeletal Anchorage Devices: A Guide to Design and Evidence-Based Solution*, Springer., Heidelberg, Germany, 2014, pp. 119–160.
10. Toshniwal NG, Mani S, Das S. Molar protraction: A challenge.. *Int J Appl Dent Sci.*2019;5:182-4.