

## Comparision of Normal Saline Irrigation with Cold Normal Saline In Surgical Removal of Lower Wisdom Tooth: A Pilot Study

### Abstract:

Surgical removal of impacted lower wisdom tooth remains as the most common dental surgical procedure that is performed on outpatient basis. In the present study, a total of 40 patients with impacted lower wisdom tooth underwent surgical extraction under local anaesthesia by using Normal saline as irrigating solution at two different temperatures that is refrigerated at 8-degree Celsius temperature and other NS at room temperature. The patients underwent standard operating procedures and medication. Post-operative complications in terms of pain, swelling, infection and delayed wound healing were assessed and compared on Day 1 and Day 3 and 7<sup>th</sup> day after surgery. The result of this study showed that irrigation with cold saline decreases the post-operative complications and enhances the healing after third molar removal.

A bigger scale of research with more samples is recommended to evaluate the most efficacy irrigating solution during surgical removal of impacted lower wisdom tooth.

**Key-words:** Chlorhexidine, distilled water, irrigating solution, normal saline

### Introduction:

Removal of impacted wisdom tooth is the most common dental surgical procedure performed in dental surgery (NICE, 2000)<sup>1</sup>. Pain, swelling, and trismus are well known sequelae after third molar surgery and lead to a transitory functional alteration in the mastication function[2-4]. The third molar surgery has following benefits like, relief of pain, prevention of periodontal disease and caries, prevention of dentigerous cyst formation, root resorption of the adjacent second molar and to facilitate orthognathic surgery and orthodontic treatment<sup>5</sup>. Alveolar osteitis is one of the most common complications associated with third molar surgery. It is characterized by a severe throbbing pain that usually begins 3 to 5 days postoperatively followed by residual radiating pain to the ear. The causes of this painful condition, commonly known as "dry socket," are not completely known but are considered to be related to malformation or disruption of blood clots in a newly vacated third molar socket. Although

data support the rationale that alveolar osteitis can be caused independent of fibrinolysis, destruction of a formed thrombus by invading oral bacteria is generally accepted as a more important etiologic factor.

Through these factors, thermal injuries occurring due to temperature raise during drilling, may be the most influent one [6,7]. The threshold level for thermal injuries on the bone is the 47°C for a minute and the temperature can raise that level easily during drilling by rotational burs[6,8].


**<sup>1</sup>SHIVAM AGARWAL, <sup>2</sup>GAURI BARGOTI, <sup>3</sup>AKRITI DHEER, <sup>4</sup>BALRAM GARG, <sup>5</sup>BIRSUBHRA ROY, <sup>6</sup>KAJAL AWANA**

<sup>1,2,4,5,6</sup>Oral and Maxillofacial Surgery

<sup>3</sup>Conservative and Endodontic Dentistry

**Address for Correspondence:** Dr. Gauri Bargoti  
Oral and Maxillofacial Surgery  
Email: bargotigauri30@gmail.com

**Received :** 01 June, 2022, **Published :** 30 Sep., 2022

Access this article online	
<b>Website:</b> www.ujds.in	<b>Quick Response Code</b> 
<b>DOI:</b> https://doi.org/10.21276/ujds.2022.8.3.4	

**How to cite this article:** Agarwal, S., Bargoti, G., Dheer, A., Garg, D. B. G., Dr Birsuhbra Roy, kajal Awana, & kajal Awana. (2022). Comparision of Normal Saline Irrigation with Cold Normal Saline in Surgical Removal of Lower Wisdom Tooth: A Pilot Study. UNIVERSITY JOURNAL OF DENTAL SCIENCES, 8(3). 16-22

Irrigating solution that is used during surgical removal of the wisdom tooth does not only prevent injury to the bone but also irrigates the working field and improves the vision of the dentist. In previous animal studies, it was shown that cutting the bone without water spray had significantly produced a greater width and intensity of inflammatory exudates and cellular debris at the margins of the defect compared to those with irrigation when viewed under the microscope (Costich *et al.*, 1964)<sup>1</sup>. However, there are very few studies on the types of irrigating solutions used during surgical procedure in the human oral cavity. Most of the studies were focused on the type of irrigation used as a cleanser for chronic wound on other parts of the human body (Angerås *et al.*, 1992; Petrisor *et al.*, 2011)<sup>[1]</sup>.

Normal saline is the most common irrigating solution used among the dental professionals during the surgical removal of lower impacted wisdom tooth and is recommended as the best cleansing solution for human body wound (Glide, 1992; Bergstrom *et al.*, 1994; Lawrence, 1997). On the other hand, Koerner (1994) had recommended sterile water and normal saline as the irrigating solution during surgical removal of wisdom tooth. The authors believed that both irrigants are sterile and able to reduce the heat that was generated during the surgery. Furthermore, these irrigants can also keep the surgical field clean.

Petrisor *et al.* (2011) had emphasized that normal saline is preferred than sterile water because it is isotonic with physiological properties of human body and therefore it is safer to the body.

Angerås *et al.* (1992) found significant decrease of infection rate in wounds cleansed with tap water compared to the wound cleansed by normal saline<sup>[9]</sup>.

Sabri Cemil Isler et.al conducted a study in which they performed standardized drilling and miniscrew placement in the tibias of 18 Sprague Dawley rats with rotating bur uncooled, cooled with 25°C and 4°C saline irrigation<sup>10</sup>. The bone healing was evaluated between the uncooled and cooled groups as a result osteoblast were seen more active and bone marrow was more dynamic in group 4°C than group 25°C. The objective of the present study is to compare the

effectiveness and the efficacy of normal saline, as irrigating solutions when used at different temperatures on the surgical removal of lower wisdom teeth by comparing the post-operative clinical complication.

### **Materials and methods:**

The study was conducted in the Department of Oral Maxillofacial Surgery at ITS Dental College, Muradnagar, Ghaziabad. The samples were patients with indication for surgical removal of impacted lower wisdom tooth (NICE, 2000). The study comprised of initial screening, taking informed consent, surgical procedures to remove the impacted tooth and review of patient on Day 1 and Day 3 and 7<sup>th</sup> day after surgery. Prior to the surgical procedure Intra oral periapical radiograph or Orthopantomogram was taken for every patient who participated in the study for classification of impaction according to Winter's classification and to exclude any other pathologies.

### **Ethical approval was granted from the Ethical Committee.**

Inclusion criteria of the samples were: (1) Healthy patient or patient with mild systemic disease only according to American Society of Anesthesiologists (ASA) Physical Status Classification System. Only patient with ASA I and ASA II were accepted. (2) Patient whose impacted wisdom tooth are indicated for surgical removal (NICE, 2000). (3) Patient who agreed to have treatment carried out under local anesthesia. (4) Patient is not allergic to any of the medication that would be used/ prescribed in the study. (5) Patient does not take any antibiotic or anti-inflammatory medication in 7 days prior to the surgery

The exclusion criteria were: (1) Patient with ASA PS Classification above II. (2) Impacted teeth that were indicated for removal under general anesthesia. (3) Patient who presents with acute infection at the operating site 7 days prior to surgery. (4) Patient who was not able to give voluntarily consent.

A total of 40 patients were randomly divided into 2 groups (A and B). Pre-op & Post-op IOPA was advised for both the group (fig-1,2). The normal room temperature was 19 degrees Celsius. Patients in group A was treated with normal saline at

room temperature as an irrigant, whereas cold normal saline (8-degree Celsius temperature) was used in Group B. Written consents for both the study and surgery were taken from all the patients prior to surgery. The patients were treated in the same month in which the temperature range was 28 to 30 degrees Celsius, the treatment was done at a standard time of 10AM. The age group of patients was from 18 to 53 years with difficulty index of 4 to 6. All patients were treated with the same surgical procedure and technique and by the same operating surgeon. The 702 round bur was used for all the procedures with the irrigating needle of 19 gauge. Average time taken for the surgery was 45 minutes. The irrigating solution was delivered as continuous stream during the surgery via micromotor at the rate of 15ml/min. After removal of the wisdom tooth, the socket was cleaned and rinsed with the respective irrigating solutions before suture was applied. Patient was given standard post-operative instructions after the surgery and asked to stop smoking for 1 week. Post-operative medication was prescribed after surgical removal of impacted tooth for 3 days & patient were recalled for follow-up visit & suture removal. Pre-op, intra-op, immediate post-op picture had been taken (fig-3). The medications prescribed were: Augmentin 625mg(TDS); Zerodol SP(TDS); Chymoral fort(BD); Ketorol DT (SOS).

All the patients were reviewed on Day 1 and Day 3 and 7<sup>th</sup> day post-operatively for complications in terms of pain, swelling, infection and delayed wound healing. Intensity of pain is measured by using Visual Analogue Scale (VAS) (McCormack *et al.*, 1988) whereby the intensity of pain is divided into 10 scales with 0 indicates no pain at all and 10 as the most severe pain that the patient has ever suffered. Extent of swelling was measured with a graduated scale superoinferiorly from lateral canthus of the eye to angle of the mandible and anteroposteriorly from corner of mouth to tragus of the ear (fig-4) and clinically by the presence and infection through systemic effects such as fever, sore throat or lymphadenopathy. Delayed wound healing was judged by whether there was any wound dehiscence. Suture removal was completed 7 days after the surgery.

Statistical analysis by ANOVA and Fisher's exact test were carried out. *P* value of less than 0.05 was considered significant. The null hypothesis of the present study was there would be statistically significant difference in post-operative

clinical complications among both types of irrigating solutions used in the study.

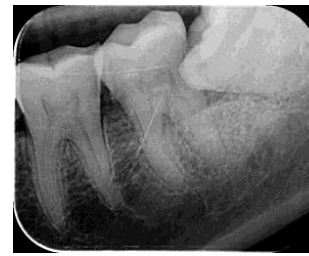

Figure-1: Pre-operative IOPA X-ray

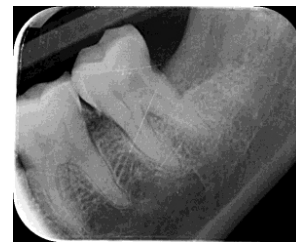
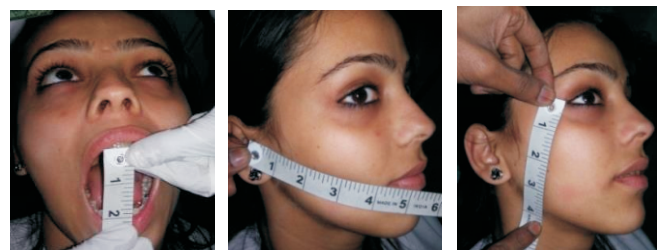


Figure-2 : Post-operative IOPA X-ray

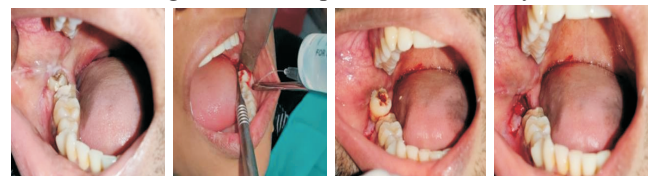

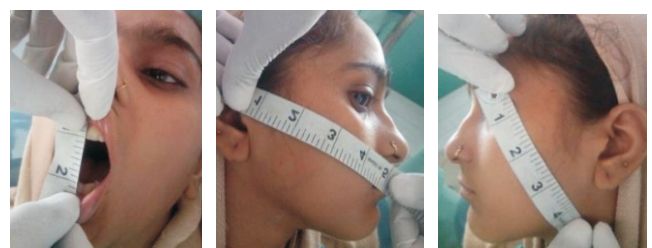Figure-3: Pre-op, intra-op and immediate post op picture of patient



Group-A Interincisal mouth opening and measurement of extraoral swelling (AP- Corner of mouth to tragus of ear & SI-lateral canthus of eye to angle of the mandible)



Group-B Interincisal mouth opening and measurement of extraoral swelling (AP- Corner of mouth to tragus of ear & SI-lateral canthus of eye to angle of the mandible) (Figure-4)

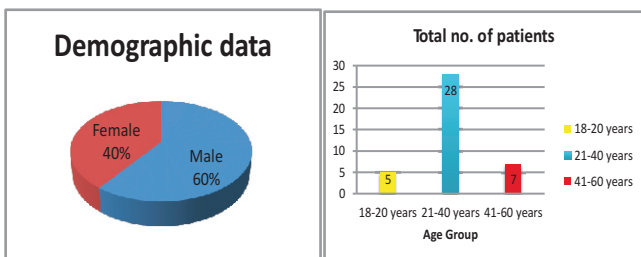
**Results :**

A total of 40 patients were randomly divided into 2 groups (A and B), 16 (40%) females and 24 (60%) males, with mean age of 20-40 years (the youngest at 18 years and oldest at 53year) took part in the study (Table 1). 10 patients had requested for wisdom tooth removal due to recurrent pericoronitis; whereas the other 16 were due to unrestorable caries and 14 patients have it removed due to untreatable pulpal and/or periapical pathology. With regards to types of impactions, 22patients presented with mesioangular impaction, 5 patients have vertical impaction, the remaining 6 patients presented with horizontal impaction (Table 2).In group A patient which was treated with the normal saline ,7 patient presented with swelling on Day 1 after operation,18 patients presented with swelling in Day 3. However, only 2 patients continued to have swelling on Day 7 after operation.

Decrease in pain on postoperative Day 7 is seen in 18 cases except 2 cases that presented with increased of pain score. But there were 2 cases for delayed wound healing. There was also decrease in infection seen post-operatively(Table 3). In group B patient which was treated with cold saline,19 patient presented with swelling on Day 1 after operation,18 patient presented with swelling in Day 3 & only 2 patients continued to have swelling on Day 7 after operation. There was no history of post- pain and infection on 3<sup>rd</sup> & 7<sup>th</sup> day but only 1 case was presented with delayed wound healing on 3rd day (Table 4). Pain score as measured by VAS between two group came out to be significant at day 1, 3,7 with p value <0.001(Table-5).The inter incisional opening was significant between two group at day 3 & day 7 but there is no significant difference between a day 1.(Table-6)

The Extraoral swelling as measured from lateral cantus to angle of mandible andtragus of ear to corner of the mouth in group 2 (cold saline) significantly reduced by day 3 & day 7. (Table-7 and Table-8)

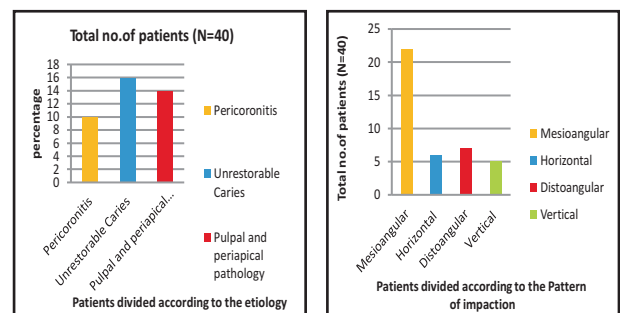
(Table-1) Demographic detail, distribution of patients according to Age and Gender in control and study group



	<b>MALES</b>	<b>FEMALES</b>
<b>Group A (Normal Saline)</b>	13 patients	7 patients
<b>Group B (Cold Saline)</b>	11 patients	9 patients

<b>Age group</b>	<b>Total no.of patients (N=40)</b>
<b>18-20 years</b>	5
<b>21-40 years</b>	28
<b>41-60 years</b>	7

(Table-2 number of patients divided according to the etiology and pattern of impaction according to Pell and Gregory Classification



<b>Etiology</b>	<b>Total no. of patients (N=40)</b>	<b>Pell and Gregory Classification</b>	<b>Total no. of patients (N=40)</b>
Pericoronitis	10	Mesioangular	22
Unrestorable Caries	16	Horizontal	6
Pulpal and periapical pathology	14	Distoangular	7
		Vertical	5

(Table-3) post-operative clinical complications observed in Group-A patients at different time intervals

PostOperative clinical complication in Group-A (DAY -1)						
	Pain	Swelling	Fever	Sorethroat	Lymphadenopathy	Wound dehiscence
No. of patients N=20	(Grade 0-4)10	7	-	2	1	-
	(Grade 4-7)5					
	(Grade 8-10)					

PostOperative clinical complication in Group-A (DAY -3)						
	Pain	Swelling	Fever	Sorethroat	Lymphadenopathy	Wound dehiscence
No. of patients N=20	(Grade 0-4)18	18	1	-	2	1
	(Grade 4-7)10					
	(Grade 8-10)2					

PostOperative clinical complication in Group-A (DAY -7)						
	Pain	Swelling	Fever	Sorethroat	Lymphadenopathy	Wound dehiscence
No. of patients N=20	(Grade 0-4)18	2	-	-	-	2
	(Grade 4-7)2					
	(Grade 8-10)					

(Table-4) post-operative clinical complications observed in Group-B patients at different time interval

PostOperative clinical complication in Group-B (DAY -1)						
	Pain	Swelling	Fever	Sorethroat	Lymphadenopathy	Wound dehiscence
No. of patients N=20	(Grade 0-4)14	19	-	-	-	-
	(Grade 4-7)4					
	(Grade 8-10)2					

PostOperative clinical complication in Group-B (DAY 3)						
	Pain	Swelling	Fever	Sorethroat	Lymphadenopathy	Wound dehiscence
No. of patients N=20	(Grade 0-4)16	18	-	-	-	1
	(Grade 4-7)3					
	(Grade 8-10)1					

PostOperative clinical complication in Group-B (DAY -7)						
	Pain	Swelling	Fever	Sorethroat	Lymphadenopathy	Wound dehiscence
No. of patients N=20	(Grade 0-4)20	2	-	-	-	-
	(Grade 4-7)					
	(Grade 8-10)					

Table 5. Comparison of Visual Analog Scale between two groups at different time intervals

Time Interval	Groups	VAS Score Mean±SD	Independent Sample t -test	
			p-value	Significance
Day 01	Group 1	4.10±1.02	0.0001	Significant
	Group 2	2.45±0.89		
Day 03	Group 1	6.20±1.06	0.0001	Significant
	Group 2	4.00±0.73		
Day 07	Group 1	5.65±0.93	0.0001	Significant
	Group 2	3.90±0.85		

Table 6. Comparison of Inter-Incisal Opening (in mm) between two groups at different time intervals

Time Interval	Groups	Inter-Incisal Opening Mean±SD	Independent Sample t -test	
			p-value	Significance
Day 01	Group 1	36.55±2.44	0.267	Non-significant
	Group 2	37.50±2.87		
Day 03	Group 1	23.05±5.06	0.0001	Significant
	Group 2	34.15±3.13		
Day 07	Group 1	34.75±2.88	0.006	Significant
	Group 2	37.30±2.70		

Table 7. Comparison of Lateral Canthus to Angle (in cm) between two groups at different time intervals

Time Interval	Groups	Lateral Canthus Angle Mean±SD	Independent Sample t -test	
			p-value	Significance
Day 01	Group 1	9.35±1.39	0.604	Non-significant
	Group 2	9.55±0.99		
Day 03	Group 1	12.35±1.60	0.0001	Significant
	Group 2	10.15±0.93		
Day 07	Group 1	9.35±1.39	0.604	Non-Significant
	Group 2	9.55±0.99		

Table 8. Comparison of Tragus-Corner of Mouth (in cm) between two groups at different time intervals

Time Interval	Groups	Tragus-Corner of Mouth Mean±SD	Independent Sample t-test	
			p-value	Significance
Day 01	Group 1	9.05±1.15	0.151	Non-significant
	Group 2	8.60±0.75		
Day 03	Group 1	11.55±1.15	0.0001	Significant
	Group 2	9.70±0.66		
Day 07	Group 1	9.75±1.29	0.001	Significant
	Group 2	8.60±0.75		

**Discussion:**

Surgical removal of third molars, as one of the most common procedures in oral and maxillofacial surgery. Pain and swelling are the patient's chief complaints and become the main concern to clinicians after surgical removal of impacted lower wisdom tooth<sup>12</sup>. Any measure that can lessen or eliminate these 2 problems would be of good news to both parties. In normal healing, most of pain and swelling reduces within 2 or 3 days. However, wound healing may be delayed due to alveolar osteitis (AO) or wound infection at surgical sites. These complications are accompanied by painful symptoms and a significant impact on the quality of life, resulting in loss of patient's productivity and working days. Wound irrigation is described as a steady flow of the irrigant solution across an open wound surface. It helps to achieve

proper wound hydration, remove deeper debris, and aids in better visual examination of the wound. It facilitates the progression from inflammatory to proliferative phase of wound healing and helps in wound healing from the deeper to superficial tissue layers. It also helps to prevent premature surface healing over an abscess pocket or infected tract (7, 8). Choosing an appropriate irrigant is one of the most critical steps in wound management. Solutions generally used for wound irrigation include topical cleansers, antibiotics, antifungal, antiseptics and anesthetics. Ideally, an irrigant should be isotonic, nonhemolytic, nontoxic, transparent, easy to sterilize, and inexpensive. Irrigating during surgical removal of impacted lower wisdom tooth has been a standard practice. It helps clinician to have a better view of surgical site by removing blood, bony debris and foreign bodies. At the same time, it also reduces heating effects from the rotating instrument that used to cut the bone and bacterial load at the surgical site which contributes to a more promising healing (Kumar *et al.*, 2011)<sup>13</sup>.

An ideal irrigating solution for surgical removal of wisdom tooth should be easily available or prepared, isotonic, nonirritant, nontoxic, non-hemolytic, antiseptic and yet economic (Urvi *et al.*, 2014).<sup>14</sup> In study conducted by Koerner 1994, it is found that sterile water and normal saline can be used as the irrigating solution during surgical removal of wisdom tooth<sup>21</sup>.

For the protection of the bone from the thermal damage during osteotomy, saline solution is routinely applied to the drill and the osteotomy site in surgical practice. And also, most of the surgeons prefer cool saline solutions and they believe that it is more effective than the normal solutions for the reduction of the temperature. In the literature, there are some studies indicating the effect of the saline application on temperature rise, on the contrary, others indicate that application of saline solution to the rotational system to bone interface during osteotomy do not reduce the temperature during the osteotomy to any significant degree. Kim *et al.* established that low-speed drilling without irrigation would not produce enough heat to cause thermal necrosis<sup>19</sup>; in the authors' knowledge, this is the first study focuses on the effect of the irrigation temperature to reduce thermal rise. At the same time, it is evaluated in this study that application of saline solution is effective or not for the reduction of the thermal

damage. A follow up study in 2013 was conducted, finding a potential reduction in thermal injury with external cooling and sharp instruments. Subsequently, they recommended cooling with ice-cooled water<sup>18</sup>. Chlorhexidine is a known antiseptic and has been shown to be safe and effective in different intraoral procedures (Larsen, 1991; Yamalik *et al.*, 1992; Kosutic *et al.*, 2009).<sup>15,16,17</sup> It is bactericidal against both Gram-positive and Gram-negative bacteria by disrupting the cell membrane of microorganism. In addition, it is also biocide against fungi. On top of these, chlorhexidine has the advantage of residual effect or substantivity over 48 hours (Denton, 2001)<sup>20</sup>.

In the present study, the efficacy of normal saline compared with the cold saline as irrigating solution during the surgical removal of impacted lower wisdom tooth was studied. Normal saline has physiologic properties and is always safe as irrigating solution. It is also isotonic and therefore chemically more similar to the natural tissue fluid compared to the other solution. It is the most widely used irrigating solution for surgical removal of wisdom tooth. On the other hand, In cold saline (8 degree temperature), osteoblasts were seen more active and bone marrow was more dynamic resulting in less swelling & pain post-operatively & also enhances the healing after third molar removal. Irrigation with cooled saline solution can confer greater benefit in bone cutting or drilling operations using high-speed instruments<sup>22</sup>.

### Conclusion:

Post-operative complications following surgical removal of third molars has a significant impact on the quality of life of patients, resulting in increased missed days of work and study. The cold saline group (experimental group -B) had significant reduction in post-operative swelling (facial oedema), pain as compared to normal saline (control group-A) on 3rd and 7th post-operative day & also there was less infection and early wound healing in case where socket was irrigated with cold saline. Thus, the use of cold saline may be used to reduce post-operative swelling & pain in surgical removal of wisdom tooth.

### References:

1. John Keat Hon Chonga , Ahmad Dzulfikar Samsudina , Mei Siang Mab (2016). The efficacy of 3 irrigating solution in surgical removal of lower wisdom tooth: a pilot study. Arch Orofac Sci , 11(1): 1-6.

2. Lynn cornish, helen douglas (2016). Cleansing of acute traumatic wounds: tap water or normal saline?. Wounds UK | Vol 12 | No 4 |
3. Isler SC, Cansiz E, Tanyel C, Soluk M, Selvi F, Cebi Z (2011). The effect of irrigation temperature on bone healing. *Int J Med Sci.*;8(8):704–708.
4. Angerås MH, Brandberg A, Falk A, Seeman T (1992). Comparison between sterile saline and tap water for the cleaning of acute traumatic soft tissue wounds. *Eur J Surg*, **158**(6-7): 347-350.
5. Lee CT, Zhang S, Leung YY, Li SK, Tsang CC, Chu CH. Patients' satisfaction and prevalence of complications on surgical extraction of third molar. *Patient Prefer Adherence*. 2015;9:257-63.
6. Berge TI, Boe OE. Predictor evaluation of post-operative morbidity after surgical removal of mandibular third molars. *Acta Odontol Scand*. 1994;52:162-69.
7. Earl P. Patients' anxieties with third molar surgery. *Br J Oral Maxillofac Surg*. 1994;32:293-97.
8. Conrad SM, Blakey GH, Shugars DA, Marciani RD, Phillips C, White RP Jr. Patient's perception of recovery after third molar surgery. *J Oral Maxillofac Surg*. 1999;57:1288-94.
9. Eriksson A, Albrektsson T, Grace B, McQueen O. Thermal injury to bone. A vital microscopic description of heat effects. *Int J Oral Surg* 1982;11:115-21.
10. Eriksson R, Adell R. Temperatures during drilling for the placement of implants using the osteointegration technique. *J Oral Maxillofac Surg* 1986;36:968-73.
11. Eriksson R. Heat-induced bone tissue injury. An in vivo investigation of heat tolerance of bone tissue and temperature rise in the drilling of cortical bone. Gothenburg, Sweden: PhD Dissertation, University of Gothenburg, defended February, 21. 1984: 1-64.
12. Rakhshan V. Common risk factors for postoperative pain following the extraction of wisdom teeth. *J Korean Assoc Oral Maxillofac Surg*. 2015;41(2):59–65.
13. Kumar KS, Reddy GV, Naidu G, Pandiarajan R (2011). Role of povidone iodine in periapical surgeries: Hemostyptic and antiinflammatory? *Ann Maxillofac Surg*, 1(2): 107-111.
14. Urvi S, Haren P, Hiren P, Bijal B, Hitesh D. Efficacy of chlorhexidine versus betadine as an irrigating agent during removal of bilateral impacted lower third molars. *Pak Oral Dent J*. 2014; 34(2):264-267
15. Larsen PE (1991). The effect of a chlorhexidine rinse on the incidence of alveolar osteitis following surgical removal of impacted mandibular third molars. *J Oral Maxillofac Surg*, 49(9): 932-937.
16. Yamalik KM, Yucetas S, Abbasoglu U (1992). Effects of various antiseptics on bacteremia following tooth extraction. *J Nihon Univ Sch Dent*, 34(1): 28-33.
17. Kosutic D, Uglesic V, Perkovic D et al. (2009). Preoperative antiseptics in clean/contaminated maxillofacial and oral surgery: prospective randomized study. *Int J Oral Maxillofac Surg*, 38(2): 160-165
18. Baker RP, Whitehouse MR, Maclean A, Blom AW, Bannister GC. The thermal effects of lavage on 57 ox femoral heads prepared for hip resurfacing arthroplasty. *Acta Orthop* (2013) 84(5):448–52.
19. Kim SJ, Yoo J, Kim YS, Shin SW. Temperature change in pig rib bone during implant site preparation by low-speed drilling. *J Appl Oral Sci* (2010) 18(5):522–7.
20. Denton GW (2001). Chlorhexidine. In: Block SS (ed.) *Disinfection, Sterilization, and Preservation*. 5th ed. Philadelphia: Lippincott Williams & Wilkins, pp. 321-336.
21. Koerner KR. The removal of impacted third molars. Principles and procedures. *Dent Clin North Am*. 1994; 38(2):255-278.
22. U Mercan, M Sumer , OA Kaya , I Keskiner , DG Meral, O Erdogan. An In-vitro Study on Thermal Changes During Implant Drilling with Different Irrigation Volumes. *Niger J Clin Pract* 2019;22:350-4.