

## The Neutral Zone Technique Revisited.

### Abstract:

The success of a complete denture is an interplay of many factors. The diminution of denture foundation is critical for mandibular ridges pertaining to less surface area. Neutral zone techniques have long been employed to address the cases of severe residual ridge resorption in an attempt to achieve adequate denture stability. Accurate registration of neutral zone is essential for optimum denture stability as teeth arrangement in such cases is dictated by the complex as well as individual actions of oral musculature. Accurate neutral zone registration requires that the denture base remains stable in the patient's mouth when the patient is asked to do various functional movements involving the tongue, lips, cheeks, etc. Through this case report, we would like to address this problem by introducing a modification to the commonly followed neutral zone techniques which facilitates accurate myodynamic registration as well as recording the tentative centric jaw relation in a single step.

**Key-words:** Complete denture, Functional movements, Neutral zone, Neutral zone technique, Residual ridge resorption.

### Introduction:

First described by Wilfed Fish (1931)[1], the neutral zone is the potential space where the outward force of the tongue is balanced by the inward force produced by the lips and cheeks during oral function.[2] These muscle actions set some boundaries that define the neutral zone.[3] Arrangement of denture teeth in this zone and harmonizing the external contours of the denture according to muscle function are the basis of various neutral zone techniques mentioned in the literature.[4]

Residual ridge resorption is a continuous process that initiates soon after loss of teeth and progresses until what remains is only the basal bone. Implant-supported prosthesis and vestibuloplasty are other suggested options to tackle such cases but the treatment cost, patient systemic factors, involved surgical intervention, pain, infection, etc. restrict their application.[5]

### Case Report:

A 65 years old female patient reported to our department with the chief complaint of difficulty in chewing food due to ill-

fitting mandibular denture. On intraoral examination, it was found that the mandibular residual alveolar ridge was severely resorbed. The patient was edentulous for over 8 years. Other treatment options like implant-supported overdenture were rejected due to financial constraints and anatomic limitations. Maxillary and mandibular complete denture using the neutral zone technique and lingualized occlusion was planned with informed consent from the patient.


<sup>1</sup>DHIREN SANJEEV SHAH, <sup>2</sup>SHALABH KUMAR,  
<sup>3</sup>AATIKA, <sup>4</sup>TANIYA BHATIA

<sup>1,3,4</sup>Department of Prosthodontics and crown and bridge,  
Teerthanker Mahaveer Dental College and Research  
Centre, Moradabad

<sup>2</sup>Department of Prosthodontics and crown and bridge,  
Teerthanker Mahaveer Dental College and Research  
Centre, Moradabad

**Address for Correspondence:** Dr. Dhiren Sanjeev Shah  
Teerthanker Mahaveer Dental College and Research  
Centre, NH- @\$, Delhi moradabad highway, Moradabad-  
244001, Uttar Pradesh  
E mail : dhiren.shah80@yahoo.com

**Received :** 26 MaY, 2022, **Published :** 30 Sep., 2022

Access this article online	
<b>Website:</b> www.ujds.in	<b>Quick Response Code</b> 
<b>DOI:</b> https://doi.org/10.21276/ujds.2022.8.3.19	

**How to cite this article:** Shah, D., Kumar, S., Aatika, & Bhatia, T. (2022). The Neutral zone technique revisited. UNIVERSITY JOURNAL OF DENTAL SCIENCES, 8(3). 83-85

Primary impressions of both the edentulous arches were made using the admixed technique<sup>[6]</sup>. Border molding was done with green stick compound, and the final impression made with zinc oxide eugenol impression paste. Autopolymerizing acrylic resin was used to fabricate record bases. The maxillary wax occlusal rim was made conventionally while the crestal portion of mandibular record base was extended vertically (Figure 1).

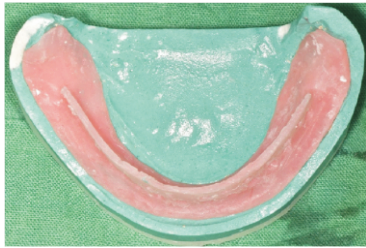

Figure 1. Vertical extension approximately 1mm in thickness constructed at the centre of the alveolar ridge.

Perforations were then made for facilitating mechanical interlocking of the registration material. The intraoral part of the fox plane was then duplicated in autopolymerizing acrylic resin with a handle of sufficient length. During the jaw relation procedure, the crestal acrylic portion of the mandibular record base served the function of mandibular occlusal rim as was modified according to patient's vertical dimension until uniform contact with maxillary rim was achieved. Two millimetre reduction in height (equal to the thickness of the fox plane) was further done in the crestal extension, so that the acrylic handle duplicated in fox plane can be fused over it without altering the already established vertical dimension. Two anterior and two posterior notches were made in maxillary wax occlusal rim and corresponding notches were made in the intraoral part of the duplicated fox plane (Figure2).



Figure 2. Notches incorporated in the intraoral part of the duplicated fox plane fused to the vertical extension.

The maxillary wax occlusal rim was inserted into the patient's mouth. Adequately softened mixture of tracing compound and impression compound modelling plastic in 1:1 ratio was added around the perforated crestal portion of the mandibular record base. The open mouth functional movements were performed by the patient following which, the mandible was guided in centric relation and then all the closed mouth functional movements involving lips and cheek were performed by the patient. While the functional movements were performed the acrylic handle helped ensuring positive contact of the mandibular record base to the residual ridge. The maxillary wax occlusal rim along with the mandibular neutral zone registration record were then removed from the patient's mouth in toto (Figure 3).

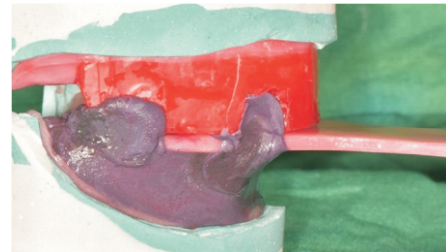


Figure 3. Maxillary wax occlusal rim along with the mandibular neutral zone registration record removed from the patient's mouth *in toto*.

The acrylic handle was then trimmed before mounting the casts. Following indirect face bow transfer, mandibular cast was mounted on a semi-adjustable articulator. Putty index was made to replace the impression compound mandibular rim with modelling wax (Figure 4).

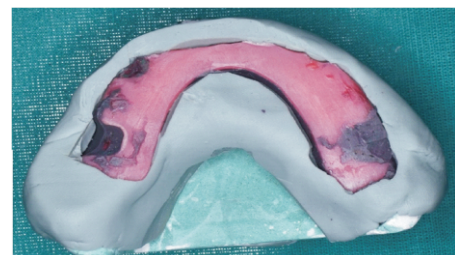


Figure 4. Putty index of neutral zone record.

Maxillary semi-anatomic and mandibular monoplane acrylic denture teeth were used and the teeth arrangement was done in neutral zone with lingualized occlusal scheme. Subsequent steps of try-in, denture processing, and denture insertion were done in a routine manner.

### Discussion:

Many materials like impression compound, elastomeric impression materials, tissue conditioners, waxes, zinc oxide eugenol impression material, acrylic resins have been used either for the registration of neutral zone or for external impressions.[5] In this case, green stick compound was impression compound to decrease the viscosity and improve the moldability of the material while recording neutral zone.

The acrylic handle unified with the mandibular record base ensured intimate adaptation of the record base over the severely resorbed ridge during all functional movements while the perforations in the crestal extension aided in retention of the material.

Improved the dexterity of the clinician and intimate adaptation of mandibular record base over the alveolar ridge are the advantages of this modification making the registration process simple, accurate, quick and without any repetitions thus increasing patient compliance.

When teeth arrangement is done in neutral zone, the uninterrupted muscle activity improves the retention and stability of the complete denture prosthesis.[5] The non-anatomic teeth used in neurocentric concept assume a more central location with respect to the denture foundation as dictated by the tongue function.[7] The occlusal scheme used in this case was lingualized occlusion. The palatal cusps of maxillary posterior anatomic teeth occluded in the central groove of the mandibular monoplane teeth. Lingualized occlusion thus combines the masticatory advantage of anatomic teeth with the mechanical freedom offered by the non anatomic teeth.[8]

### Conclusion:

Regardless of the severity of residual ridge resorption, there exists a space in completely edentulous patients where muscular forces are in equilibrium. Severe mandibular ridge resorption is not uncommon in clinical practice. The modification described in this case report enables the dentist to make an accurate neutral zone registration record along with the centric jaw relation in a single step.

### References:

1. Fish EW. An analysis of the stabilising factors in full denture construction. *Br Dent J* 1931;52:559-570.
2. Beresin VE, Schiesser FJ. The neutral zone in complete dentures. *J Prosthet Dent* 1976;36:356-367.
3. Cagna DR, Massad JJ, Schiesser FJ. The neutral zone revisited: From historical concepts to modern applications. *J Prosthet Dent* 2009;101:405-412.
4. Yeh YL, Pan YH, Chen YY. Neutral zone approach to denture fabrication for a severe mandibular ridge resorption patient: Systematic review and modern technique. *Journal of Dental Sciences* 2013;8:432-438.
5. Porwal A, Sasaki K. Current status of the neutral zone: A Literature review. *J Prosthet Dent* 2013;109:129-134.
6. McCord JF, Tyson KW. A conservative prosthodontic option for the treatment of edentulous patients with atrophic mandibular ridges. *Br Dent J* 1997; 182: 469-472.
7. Devan MM. The concept of neurocentric occlusion as related to denture stability. *J Am Dent Assoc* 1954;48:165-169.
8. Becker CM, Swoope CC, Guckes AD. Lingualized occlusion for removable prosthodontics. *J Prosthet Dent* 1977;38:601-608.