

Prosthetic Rehabilitation of Acquired Maxillary Defect Secondary to Necrotizing Stomatitis: A Rare Case Report

Abstract:

Necrotizing stomatitis is the necrotic inflammation of oral tissues requiring immediate surgical resection as a life saving measure. Prosthetic rehabilitation in such patients is a challenging task as large amount of ridge and palatal tissue is lost after resection leading to compromised retention, support and esthetics. This case report describes prosthetic rehabilitation of a patient with maxillary defect secondary to necrotizing stomatitis.

Key-words: Necrotizing Stomatitis, Sequestrum, Reconstruction

Introduction:

Word Necrotizing Stomatitis literally means “Necrotic Inflammation of the Mouth”. It is part of a spectrum of disease term “Necrotizing Periodontal Diseases”, which also includes necrotizing ulcerative gingivitis, necrotizing ulcerative periodontitis in early stages and noma or cancrum oris in advanced stages. It is a rare disease caused by mixed bacterial infection *P. Intermedia*[1], *Fusobacterium* and *spirochaetes* such as *Treponema*[2].

Predisposing factors for necrotizing periodontal disease are a change in life habits, young age, malnutrition, psychological tension, prolonged stress with insufficient rest, smoking, and alcohol consumption[3]. In developing countries like India it is common among children of low socioeconomic status usually occurring with malnutrition and shortly after onset of viral infections such as measles[4].

Surgery to remove necrosed part followed by antibiotic regimen is the only treatment option to save the life of the patient as there is destruction of epithelium and connective

tissue. Surgical management involves removal of mobile teeth and sequestra, debridement, decortications, resection followed by reconstruction[5]. Reconstruction in such cases after surgical resection is a challenging task as there is reduced denture bearing surface area affecting retention adversely; air leakage due to poor stability; reduced support area for denture; movement of prosthesis during function and poor esthetics due to removal large portion of maxilla. As the prosthesis replaces missing teeth as well as lost hard and soft tissues of alveolar ridge and palate, the bulk of the prosthesis further decreases retention due to its added weight and volume[6,7].

¹AMINA, ²SAAD AHMED, ³GEETA RAJPUT
⁴N. D. GUPTA

^{1,3}Department of Prosthodontics Crown & Bridge
Dr. Ziauddin Ahmad Dental College and Hospital,
Aligarh Muslim University, Aligarh


²Department of Oral Pathology and Microbiology
Rama Dental College, Kanpur

⁴Department of Periodontics & Community Dentistry
Dr. Ziauddin Ahmad Dental College and Hospital,
Aligarh Muslim University, Aligarh

Address for Correspondence: Dr. Amina
Assistant Professor, Department of Prosthodontics Crown
& Bridge Dr. Ziauddin Ahmad Dental College and Hospital
Aligarh Muslim University
Email: amina6468.aa@gmail.com

Received : 29 May, 2022, **Published :** 31 Dec., 2022

How to cite this article: Amina, Saad Ahmed, & Geeta Rajput N. D. Gupta. (2022). Prosthetic Rehabilitation of Acquired Maxillary Defect Secondary to Necrotizing Stomatitis: A Rare Case Report. UNIVERSITY JOURNAL OF DENTAL SCIENCES, 8(4).

Access this article online	
Website: www.ujds.in	Quick Response Code 
DOI: https://doi.org/10.21276/ujds.2022.8.4.19	

This case report describes prosthetic rehabilitation of a patient with definitive obturator, who had undergone maxillectomy secondary to necrotizing stomatitis, in a way that fulfilled his needs and significantly improved his of quality of life.

Case Report:

A thirty two year old male reported to department of Prosthodontics, Crown and Bridge with the chief complaint of nasal regurgitation of fluids and poor speech after surgery to treat upper jaw infection one month back. There was no significant medical history. Patient was a chronic smoker since past ten years. Previous dental history and investigation reports revealed that patient has undergone partial maxillectomy secondary to necrotizing stomatitis.

Extraoral examination revealed a severely retruded maxilla due to removal of major portion of alveolar ridge, compromising esthetics of the patient (fig. 1). Mouth opening was normal. There was no mandibular deviation on opening. On intraoral examination, it was found out that all maxillary teeth were extracted alongwith resection of a major portion of residual alveolar ridge. A small oroantral communication of about 10x10 mm was present in right posterior vestibular region (fig 2). All walls of the defect were lined with healthy mucosa. In mandibular arch all teeth were present, with no evidence of supraeruption. Mandibular movements were within the normal range. Tongue function was normal and speech was affected. Labial and buccal mucosa, floor of mouth, soft palate & oropharynx were normal.

The basic goals of prosthetic rehabilitation were to fabricate obturator prosthesis which will seal acquired tissue opening of vestibule, restore facial contour and improve esthetics, replace missing teeth, improve speech as well as mastication and significantly improve the quality of life of the patient.

Treatment Procedure:

Primary impression of the upper arch was made using irreversible hydrocolloid (Zelgan 2002, Dentsply, India), after blocking the anterior and medial tissue undercuts using wet gauze. The lower impression was also made at the same

appointment using the same material. Primary cast was made using dental plaster (Dentico, Neelkanth) for custom tray fabrication. Custom tray was fabricated with autopolymerizing acrylic resin (DPI-RR Cold Cure) after application of two layers of modeling wax as spacer (fig 3). Border moulding was done with heavy body polyvinyl siloxane impression material (Elite HD+, Zhermack). Final impression is made with heavy body polyvinyl siloxane impression material lined with light body (Elite HD+, Zhermack) (fig 4). Master cast was fabricated with dental stone (Kalstone, Kalabhai). Occlusal rim was fabricated on the master cast with modelling wax (Y-Dents MDM) and jaw relations were recorded. Bite registration was done with aluwax (Aluwax Dental Products Co.) and casts were articulated. Teeth arrangement was done using zero-degree/non anatomic teeth and try in was performed (fig.5). Curing was done with high impact heat polymerization acrylic resin. (Triplex, Ivoclar Vivadent) (fig 6). During insertion appointment, necessary occlusal corrections were made and patient was given proper instructions regarding maintainance of prosthesis (fig 7). The prosthesis fulfilled esthetic and functional demand of the patient as well as significantly improved the quality of life of the patient. Follow up was done at one week, one month, two month and 6 month intervals.

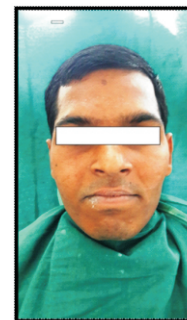

Fig 1 a: Pre operative, extraoral (Frontal view)

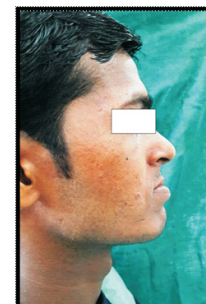

Fig 1b: Preoperative, extraoral (Profile view)

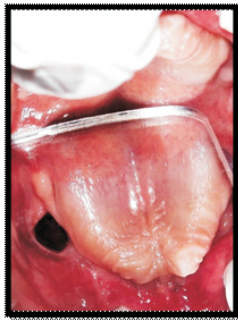


Fig 2: Intraoral View

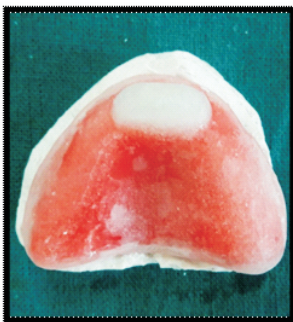

Fig 3: Custom tray

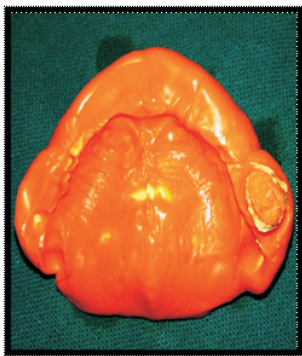


Fig 4: Final Impression

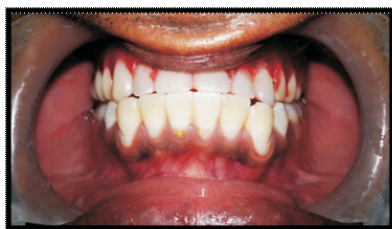

Fig 5: Try in

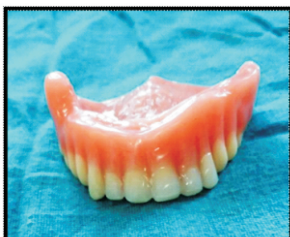

Fig 6: Definitive Prosthesis

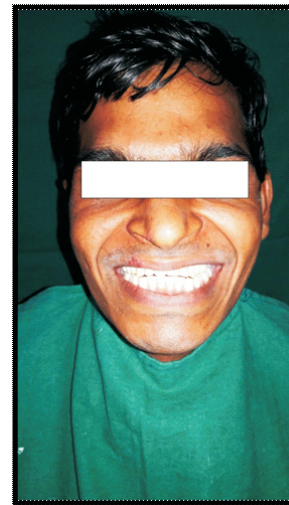

Fig 7a: Prosthesis inserted in patients mouth

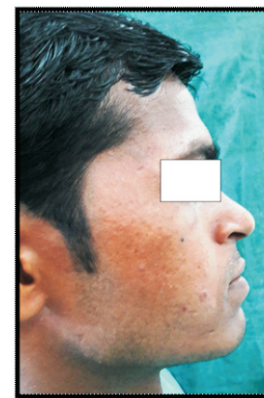

Fig 7b: Post operative (Profile view)

Discussion:

Fabrication of an obturator for an edentulous patient presents a major challenge because of the lack of seal and support from teeth, as a result of which retention, stability and support of the prosthesis is compromised. In cases with Necrotizing Stomatitis, since a large portion alveolar ridge is removed, stresses must be equally distributed to available portion of the hard palate. Also esthetic needs of the patient must be fulfilled as esthetics may be severely compromised due to resulting retruded maxilla after resection.

Oroantral communication, if present can be purposely kept patent by the acrylic resin extensions of the denture as it may provide only means of retention in such patients[8]. This form of retention can also be considered for similarly impaired

patients when conventional forms of retention, including osseointegrated implants, cannot be considered as a treatment option[8].

Coordination with speech pathologist to gain knowledge about physiology and mechanics of speech can help to design the prosthesis, which can fulfill the requirements of phonation, resonance and articulation[6].

In the above presented case our aim was to fabricate an obturator prosthesis which will seal the acquired defect in the vestibule, provide adequate functions of speech, chewing and swallowing, as well as acceptable esthetic appearance.

Various factors that are critical for the patients that are looking forward to be able to make intelligible speech with the help of such a prosthesis include: labial or palatal placement of the anterior teeth; correct vertical dimension of occlusion; the coverage of the hard palate; concavity of the palatal vaults of maxillary complete dentures and artificial teeth which may disturb the air flow, causing misarticulation⁹. While fabricating removable prosthesis the design of the alveolar area is crucial because the tongue comes into contact with sections of teeth, alveolar ridge and hard palate during speech¹⁰. Apart from esthetics other two important factors determining anterior tooth placement includes occlusion and esthetics. In the presented case, in order to correct esthetic problem due to collapsed upper lip, slightly longer anterior teeth with slightly pronounced proclination were placed. Palatal contours were waxed-up to improve phonetic of the patient.

Success of an obturator depends upon the weight of the prosthesis as well as remaining hard and soft palate. Prosthesis should be as light as possible[11]. Prosthesis was light weight in presented case due small size of the defect and palatal tissues were also healthy. Prosthesis was fabricated with high impact heat polymerization acrylic resin. (Triplex, Ivoclar Vivadent) with a small bulb extending into defect and engaging lateral and posterior undercut.

Conclusion:

Prosthetic rehabilitation of a maxillectomy defect is the only definitive treatment of choice when surgical reconstruction of the maxilla is contraindicated, delayed, declined by the patient, or not possible. This clinical report described the prosthetic rehabilitation of a patient with partial maxillectomy due to necrotizing stomatitis. The patient adapted well to the prosthesis and reported improvements in both speech and mastication with its use.

References:

1. *Karring, edited by Jan Lindhe, Niklaus P. Lang, Thorkild. Clinical periodontology and implant dentistry (5th ed.). Oxford: 2008. pp. 413, 459.*
2. Lang N, Soskolne WA, Greenstein G, et al. Consensus report: necrotizing periodontal diseases. *Ann Periodontol* 1999; 4:78.
3. Scully, Crispian. *Oral and maxillofacial medicine: the basis of diagnosis and treatment* (2nd ed.). Edinburgh: Churchill Livingstone. 2008. pp. 101, 347.
4. Horning GM, Cohen ME. Necrotizing ulcerative gingivitis, periodontitis, and stomatitis: clinical staging and predisposing factors. *J Periodontol.* 1995; 66: 990–998.
5. S. Reddy, K. Prasad, P. Chippagiri et al., Osteomyelitis of the maxilla: a case report of three cases; *American Journal of Advances in Medical Science* 2014. vol. 2, no. 3, 34–41.
6. Chalian, VA, Drane JB, Standish SM. The evolution and scope of maxillofacial prosthetics. In: Chalian VA, Drane JB, Standers SM editors. *Maxillofacial Prosthetics: Multidisciplinary Practice.*
7. Williams and Wilkins Company; Baltimore: USA, 1972. Beumer J, Curtis TA, Marunick MT. *Maxillofacial rehabilitation: prosthodontic and surgical considerations.* St Louis: Ishiyaku Euro America; 1996. p. 225-29.
8. Leanne M. Sykes, Johan F. Wolfaardt, Ashwin Sukha . Prosthetic rehabilitation of a patient with total avulsion of the maxilla: A clinical report; *J Prosthet Dent* 2002; 88: 362-6.

9. Tanaka H. Speech patterns of edentulous patients and morphology of the palate in relations to phonetics. J Prosthet Dent 1973; 29(1):16-28.
10. Pogrel MA, Miller CE. A case of maxillary necrosis. J Oral Maxillofac Surg 2003; 61(4):489-93.
11. Sykes LM, Wolfaardt JF, Sukha A. Prosthodontic rehabilitation of a patient with total avulsion of the maxilla (a clinical report). J Prosthet Dent 2002; 88(4):362-66.