

Recreating Smiles Using A Natural Tooth Pontic: A Case Report.

Abstract:

Traumatic injuries resulting in loss of one's anterior tooth have a significant psychological impact. As the children are becoming more conscious about their appearance, a mere replacement of the lost tooth can minimize these aesthetic & functional concerns. This paper describes the techniques used to recreate the smile of an 8-year-old child, who sustained trauma to the face after a fall while playing. As the child has a developing dentition, we opted for a natural tooth pontic and composite build-up to restore his smile

Keyword :

Introduction :

As dentists, we seldom encounter a clinical situation that warrants the removal of teeth from a high aesthetic zone as a result of trauma, periodontal disease, root resorption, or failed endodontic treatment. In children and young adolescents, the loss of a solitary permanent maxillary anterior tooth is usually because of either trauma or its sequelae. With the ever-increasing demand of aesthetics, an early loss of anterior teeth can have a debilitating effect on a child's psyche and thus, requires immediate attention in order to avoid masticatory and phonetics difficulties and also, to maintain the edentulous space.[1]

In cases of avulsion injuries, viability of periodontium plays a pivotal role in determining the long-term success of replantation. A tooth replanted with a necrotic periodontium is likely to get ankylosed and undergo inflammatory resorption.[2] Conventionally, a wide range of treatment options are at our disposal such as the removable partial dentures, fixed partial prosthesis and dental implants. However, in pediatric patients, a harmonious growth and development of oral-maxillofacial structures is desirable and therefore, such prosthesis are not a viable option as they can have a deleterious impact on the surrounding structures.[3] Another method for replacement of missing tooth is to use the avulsed tooth as a pontic which offers enhanced aesthetics and

is a more conservative, less time consuming compared to other techniques.[4]

This case report describes a case where the avulsed tooth could not be replanted in 7 years old child considering the increased extra-oral dry time period but was instead, utilized as a pontic and incorporated in a space maintainer. This appliance offered the advantage of preventing loss of interarch spaces, allowed continuous growth of oro-facial structures and did not compromise upon the speech and aesthetics of the growing child.

Case Report :


A seven-year-old male child was referred from a general hospital to the Department of Pediatric and Preventive Dentistry, ITS-CDSR, Muradnagar, Ghaziabad after sustaining trauma to the face following a fall while playing on

¹NIKITA DHINGRA, ²SHIVANI MATHUR,
³MANVI MALIK, ⁴KETKI KASHYAP
¹⁻⁴Department of Pediatric and Preventive Dentistry,
ITS-CDSR, Muradnagar, Ghaziabad

Address for Correspondence: Dr. Nikita Dhingra
M.D.S
Department of Pediatric and Preventive Dentistry
ITS-CDSR
Muradnagar, Ghaziabad
E-mail: nikitadhingra14@gmail.com

Received : 3 Feb., 2022, **Published :** 30 June, 2022

How to cite this article: .Dhingra, D. N. (2022). Recreating Smiles Using A Natural Tooth Pontic. UNIVERSITY JOURNAL OF DENTAL SCIENCES, 8(2). 100-103

Access this article online	
<p>Website: www.ujds.in</p>	<p>Quick Response Code</p> 
<p>DOI: https://doi.org/10.21276/ujds.2022.8.2.19</p>	

the football field resulting in injury to the upper lip [Figure 1]. The facial wounds had been sutured and tetanus toxoid administered. The medical history was not contributory. The general physical examination did not show any other external injury.

The intraoral examination showed a missing maxillary right central incisor and an Ellis class I fracture in maxillary left central incisor. The gingiva overlying the missing teeth and lower lip was also torn [Figure 2]. Radiograph confirmed the avulsion of maxillary right central incisor [Figure 3].

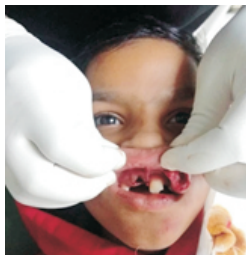

Figure 1: The extra -oral view of patient showing laceration of upper lip

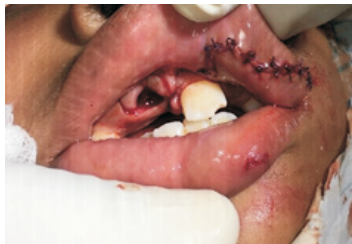

Figure 2: The intra-oral view of the patient showing missing maxillary right central incisor & an Ellis class I fracture in maxillary left central incisor and associated soft tissue injury

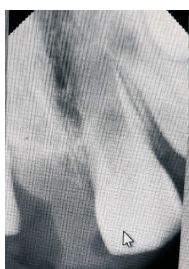

Figure 3: An IOPA confirming the avulsion of maxillary right central incisor

The deciduous lateral incisors had exfoliated a month back. Also, patient had proximal caries in maxillary right deciduous first molar and pit and fissure caries in mandibular right and left deciduous first molars [Figure 4&5]. History revealed that the avulsed tooth was found at the site of the mishap but

unfortunately, deposited 3 days later. Since, the avulsed tooth had remained dry extra-orally for 72 h after the injury, replantation was not performed. The tooth was cleared of all dust and debris. The necrotic periodontal tissue attached to the root was chemically removed with sodium hypochlorite and finally, rinsed with sterile saline. The pulp was extirpated from the avulsed tooth [Figure 6] and the crown decoronated. The root canal access cavity was sealed with composite. The crown was transferred to sterile saline at room temperature.

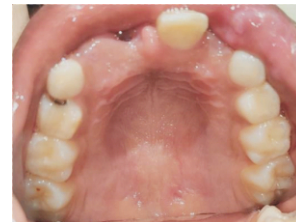

Figure 4: The intra-oral view of patient showing proximal caries with maxillary right deciduous first molar

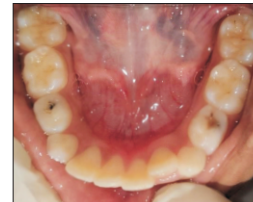

Figure 5: The intra-oral view of patient showing pit and fissure caries with mandibular right & left deciduous first molar

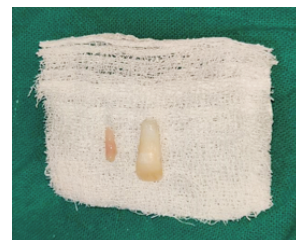

Figure 6: The avulsed immature tooth with extirpated pulp

Stainless steel orthodontic molar bands were adapted on the first permanent maxillary molars and alginate impressions were made for both maxillary and mandibular arch. Caries excavation was performed in relation to maxillary right deciduous first molar and a stainless crown was delivered with the same. A palatal arch and an additional wire extension was fabricated using a 0.9 mm round stainless steel wire. The wire extension was soldered to the palatal arch which was then soldered upon the orthodontic bands. In the subsequent visit, intra-orally an eruption swelling in relation to maxillary right lateral incisor was palpable and thus, crown exposure was planned [Figure 7]. A diode laser was used at a power of

1.5W in contact mode for crown exposure in order to assess the angulation of maxillary right lateral incisor [Figure 8].

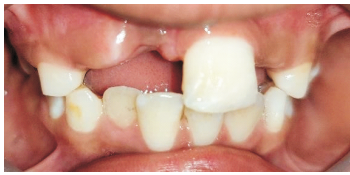

Figure 7: Eruption swelling in relation to maxillary right lateral incisor

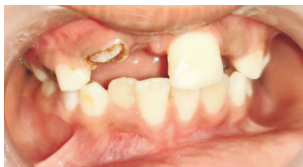

Figure 8: Crown exposure was performed using Diode laser

The mesiodistal dimension of the natural, avulsed tooth was adjusted as per the angulation of erupting maxillary right lateral incisor [Figure 9]. The palatal aspect of the avulsed tooth crown was then dried, acid-etched with 37% orthophosphoric acid for 20 s and rinsed with water for 15 s. It was air-dried and a light-curing adhesive agent was applied and subsequently, light-cured. A light-cure composite resin was used to attach the tooth with wire component, which was then photopolymerized for 40 s at several point. The appliance was tried and occlusion prematurities were removed. The palatal arch assembly was cemented in the maxillary arch using a glass-ionomer luting agent [Figure 10]. The patient was recalled after a week [figure 11] and thereafter is on a biannual follow-up.

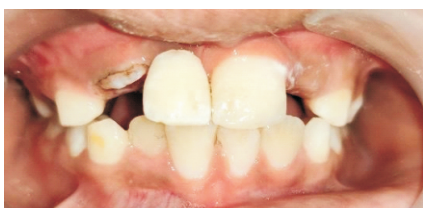

Figure 9: Mesiodistal dimension of central adjusted according to the exposed lateral incisor

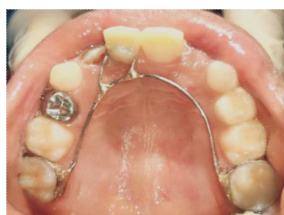

Figure 10: The space maintainer maxillary right incorporated with the natural tooth pontic cemented in maxillary arch

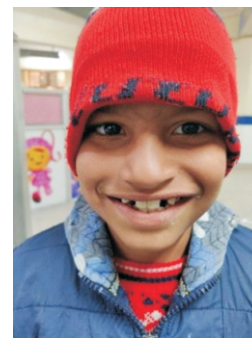

Figure 11: 1-week post-op

The appliance was adjusted according to the angulation of erupting lateral incisor in the subsequent visits. The patient has been comfortable with the appliance nearly 1 year after treatment [Figure 12].

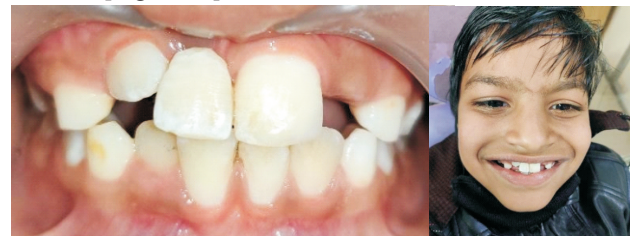

Figure 12 : 1 year post up

Discussion:

Sudden tooth loss can be a traumatic experience that affects a child psychologically and hampers social skills in today's world, in which appearances seem to matter from a young age. Besides appearance missing anterior teeth also affects the speech, compromises mastication and encourages habits like tongue thrusting. Thus, to prevent such complications tooth replacement becomes necessary.

Out of all the dento-alveolar injuries in children, 5-20% injuries occur in permanent dentition and avulsion is seen in 0.5-16% of all injuries. The peak incidence of dental trauma occurs in 7-11-year age group with males being two times more commonly affected than females.[5] In our case, the direct impact sustained during the fall and the loosely structured periodontal ligament around the erupting permanent teeth could be an additional causative factor resulting in avulsion.[6]

Ideally, the immediate treatment of avulsed tooth is replantation as aids in preserving the pulp as well as the periodontium. Replantation, performed up to 60 mins of extra-oral dry times has been reported and signs of periodontal healing was seen in only 15% cases.[7] However, in case immature tooth an increase in extra-oral dry time of more than 1 hour, reduces the success of replantation and tooth possess a greater risk of replacement resorption.[8] Therefore, in such clinical scenarios, it is advised to opt for a immediate treatment that functions as a space maintainer and prevents undesirable complications such as midline deviation, pathologic migration and supra-eruption of the antagonistic teeth.

The space loss following tooth avulsion can be bridged by a removable partial denture; resin bridges and recently fibre-reinforced bridges. Removable functional appliances have a disadvantage of being bulky, unesthetic due to the presence of clasps and need laboratory time and precision.[9] Fibre-reinforced bridges are another treatment modality which are hygienic, aesthetic, and do not require the fabrication of a cast model but they do tend to rigidly splint the adjacent teeth thereby, restricting the growth of inter-canine arch width.[10] In our case, we incorporated a natural tooth pontic in a fixed space maintainer that harboured support from the palate and at the same time, did not hamper the growth of the maxillary arch. Another major advantage of utilizing the patient's natural tooth it provides positive patient reinforcement and the optimal pontic in terms of shape, colour, size, and alignment.[11]

Conclusion:

Thus, this paper highlights an aesthetic and long-term provisional solution to avulsed tooth where replantation is undesirable. In pediatric patients, this appliance can be provided as an interim, fixed prosthesis which allows continuous growth and development of maxilla and the surrounding structures until a fixed bridge or an implant can be planned. Additionally, natural tooth pontic is a non-invasive, reversible, simple and cost-effective chair-side technique, which offers superior aesthetics and function with no need of laboratory involvement.

References:

1. Benjamin F: Childhood lasts a lifetime. *Br Dent J.* 2018, 224:579-3. 10.1038/sj.bdj.2018.271
2. Sharma U, Garg AK, Gauba K. An interim, fixed prosthesis using natural tooth crown as a pontic. *Contemporary clinical dentistry.* 2010 Apr;1(2):130.
3. Vaghani KN, Nadig PS, Shah MA, Dave DH. Natural tooth pontic: An interim restoration for compromised aesthetic conditions. *Adv Hum Biol* 2019; 9:173-6
4. Gandhi M, Baviskar A. Anterior Tooth Replacement of Avulsed Deciduous Tooth: Resin Reinforced Fibre with Natural Tooth Pontic. *Cureus.* 2021; 13(11): e19605. doi:10.7759/cureus.19605
5. Fouad AF, Abbott PV, Tsilingaridis G, et al. International Association of Dental Traumatology guidelines for the management of traumatic dental injuries: 2. Avulsion of permanent teeth. *Dent Traumatol* 2020;36(4):331-342. <https://doi.org/10.1111/edt.12573>
6. Andreasen JO. Effect of extra-alveolar period and storage media upon periodontal and pulpal healing after replantation of mature permanent incisors in monkeys. *Int J Oral Surg.* 1981; 1:4353.
7. Andreasen JO, Borum MK, Jacobsen HL, Andreasen FM. Replantation of 400 avulsed permanent incisors 4. Factors related to periodontal ligament healing. *Endod Dent Traumatol* 1995;11: 76-89.
8. Flores MT, Andreasen JO, Bakland LK, Feiglin B, Gutmann JL, Oikarinen K, et al. Guidelines for the evaluation and management of traumatic dental injuries. *Dent Traumatol* 2001; 17:1938.
9. Lahiri A, Jalan P, Zahir S, Kundu GK: Restoring smile and confidence in a 5-year-old child: a case report. *Int J Curr Res.* 2019, 11:257-9. 10.24941/ijcr.33830.01.2019
10. Ulusoy AT, Cehreli ZC. Provisional use of a natural tooth crown following failure of replantation: A case report. *Dent Traumatol* 2008; 24:96-9.
11. Bhargava S, Namdev R, Dutta S, Tiwari R. Immediate fixed temporization with a natural tooth crown pontic following failure of replantation. *Contemp Clin Dent* 2011;2:226-9.