

Capillary Hemangioma on the Hard Palate- A Puzzling Expression

Abstract:

Hemangiomas of the head and neck are benign tumours that have their origin from the blood vessels. Hemangiomas are classified as capillary, cavernous, sclerosing and central type. The nature of this tumour is progressively slow growing, including involvement of greater portions of the superficial and deep blood vessels, functions may be affected, depending on the location. Hemangiomas are common in the head and neck and have rare occurrence in the oral cavity. Lips, buccal mucosa and tongue are the common sites, hemangiomas occur rarely on the palate. This is a case of unusual location of capillary hemangioma on the palate in a middle aged man diagnosed by histopathology after surgical excision

Key-words: Capillary, Hemangioma, Palate

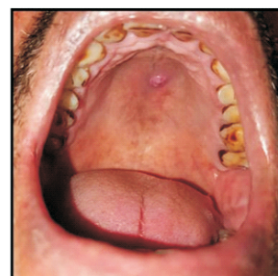Introduction:

Hemangiomas are relatively common benign proliferations of the vascular channels that may be present at birth or arise during early childhood[1]. Due to the common tumour entity in the childhood, hemangiomas occur in about 5-10% of children < 1 year of age, depicting rapid proliferating growth phase of endothelial cells followed by gradual decline[2]. Hemangioma may appear in the middle-aged or older individuals having no specific gender predilection and approximately >50% patients falling in the bracket of > 40 years of age[3,4]. Buccal mucosa, tongue and lips are prominent sites of occurrence of hemangioma, uvula, soft and hard palate occurrences are rare[5].

Case report:

A 52 year old man presented with a sessile growth on the midpalatine raphe region of hard palate since 1 month. The growth is the size of a pea which was noticed 1 month ago and has increased to the present size. The growth was asymptomatic, with no history of pain, pus discharge or bleeding and without any secondary symptoms manifested. Upon intraoral soft tissue examination, the growth appeared solitary, pink, broad based with pebbly surface and well defined borders. It was present on the midpalatine raphe,

approximately 5 cm behind the incisive papilla between maxillary first and second premolar, measuring about 0.8 cm in diameter. On palpation, the growth was non tender, soft to firm in consistency and non pulsatile. Oral hygiene of the patient was fair. (figure 1)



An occlusal radiograph was taken that did not reveal any

¹DEEPTI GARG, ²SWATI GAUTAM,
³BALJEET SINGH, ⁴AKSHITA SINGH THAKUR

^{1,2,4}Department of Oral Pathology and Microbiology, Bhojia Dental College and Hospital, Bhud, Baddi, Distt Solan

³Department of Periodontology, Bhojia Dental College and Hospital, Bhud, Baddi, Distt Solan

Address for Correspondence: Dr. Akshita Singh Thakur
PG student

Department of Oral Pathology and Microbiology
Bhojia Dental College and Hospital, Bhud, Baddi,
Distt Solan, H. P

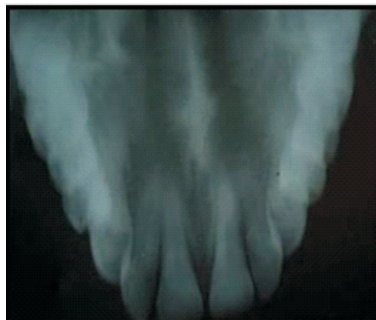Email : akshitathakur24@gmail.com

Received : 24 Jan., 2022, **Published :** 31 Dec., 2022

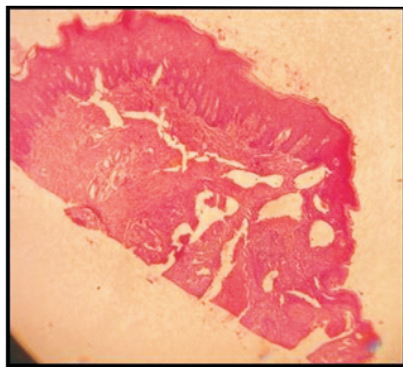Access this article online	
Website: www.ujds.in	Quick Response Code 
DOI: https://doi.org/10.21276/ujds.2022.8.4.10	

How to cite this article: Garg, D., gautam, S., singh, baljeet, & thakur, akshita. (2022). "Capillary Hemangioma on the hard palate- A puzzling expression". UNIVERSITY JOURNAL OF DENTAL SCIENCES, 8(4).

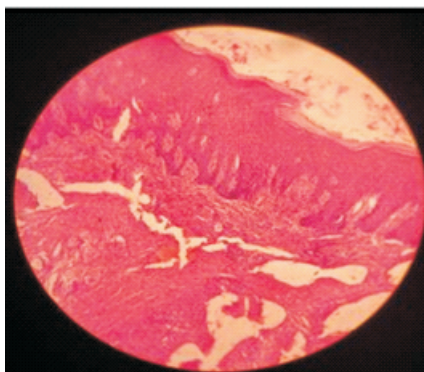
pathological changes (figure 2)



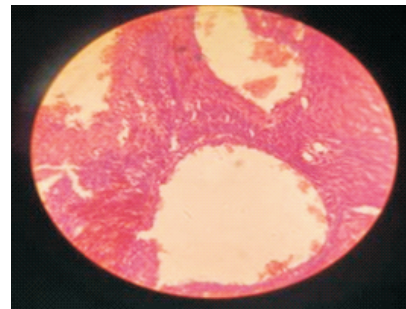
Differential diagnosis include pyogenic granuloma, irritational fibroma, squamous cell carcinoma, Kaposi sarcoma, AIDS-related complex, metastatic carcinoma and benign lesion like bacillary angiomatosis, epulis, telangiectasia. The patient was operated under local anesthesia and an excisional biopsy was performed and the mass was sent for further histopathological examination. The excised mass upon histopathological examination revealed parakeratinized stratified squamous epithelium (figure 3-a)



The connective tissue stroma comprised of numerous small and large endothelium-lined blood vessels engorged with the RBC's.(figure 4-a)



The endothelial cells were plump and giving rise to new small capillaries.(figure 5-a)



Chronic inflammatory cell infiltration and bundles of collagen fibres were also seen. Upon co-relation of clinical and histopathological findings, final diagnosis of capillary hemangioma was established.

A systematic review of capillary hemangioma on the palate

Serial number	Authors	Case
1.	Lale et al, 1998 ⁶	<ul style="list-style-type: none"> A case of palatal haemangioma presenting with feeding difficulties in a young infant.
2.	Aydan Acikgoz et al, 2000 ³	<ul style="list-style-type: none"> A case of 13 year old boy with swelling and recurrent periodontal bleeding
3.	Alparslan Dilsiz et al, 2009 ⁷	<ul style="list-style-type: none"> A case of 19 year old female patient with the complaint of bleeding and slowly enlarging mass on the upper right molar region.
4	Rachappa m. m et al, 2010 ⁸	<ul style="list-style-type: none"> Unusual case of benign tumor occurring on hard palate of a 7 year old male patient which was clinically diagnosed as pyogenic granuloma and histopathologically as capillary hemangioma.
5	Vipin bharti, et al, 2012 ⁹	<ul style="list-style-type: none"> A case of capillary hemangioma of anterior palatal mucosa in a 13-year-old female.
6	Roopika Handa, et al, 2013 ¹⁰	<ul style="list-style-type: none"> Rare case of capillary hemangioma of the palatal mucosa
7	Khurshid mattoo et al, 2015 ¹¹	<ul style="list-style-type: none"> Capillary hemangioma of the posterior palatal mucosa in a 23 year old female patient
8	Pooja singh, et al, 2016 ⁴	<ul style="list-style-type: none"> The case signifies a rare location of a capillary haemangioma on the palate in a middle aged man.
9	Veena raj et al, 2016 ¹²	<ul style="list-style-type: none"> Case report of capillary hemangioma on the palate of a 20 year old pregnant patient.
10	Sinan Uluyol et al, 2018 ¹³	<ul style="list-style-type: none"> A case of geriatric patient with abundant hemorrhage due to a capillary hemangioma of the hard palate
11	Rilna et al, 2019 ¹⁴	<ul style="list-style-type: none"> Case of capillary hemangioma of the hard palate in a male patient aged 7 years
12	Dr. I. Venkata Krishna et al, 2021 ¹⁵	<ul style="list-style-type: none"> An unusual case of capillary hemangioma occurring on posterolateral part of hard palate of a 12 year old male child since 6 months

Discussion:

Hemangiomas of the oral cavity may exist as small or large superficial growths with varying degrees of penetration into soft tissues or as monstrous growths extending to the oesophagus. They maybe multicentric and exhibit cobblestone appearance[16]. Usually, superficial small lesions tend to be capillary hemangiomas , whereas superficial large or deep lesions tend to be of cavernous or mixed variety [17].

In this case, with the clinical appearance, a working diagnosis of pyogenic granuloma was assumed; however, histopathological examination confirmed a diagnosis of capillary haemangioma. Usually capillary haemangioma is composed of many small capillaries lined by a single layer of endothelial cells, supported by a connective tissue stroma of varying density. It bears considerable resemblance to the young granulation tissue and is mostly identical to some cases of pyogenic granuloma. Some cases show remarkable endothelial cell proliferation.[18]

The management of hemangiomas and the treatment of choice depend on several factors including the age of the patient and the size and extent of the lesions, as well as their clinical characteristics. Some congenital lesions may undergo spontaneous regression at an early age. Small and superficial lesions may be completely excised. In few cases, emergency surgery may become mandatory when arterial bleeding arises from intraosseous hemangiomas of the jaw following simple tooth extraction. Other modalities of management of hemangiomas, including oral corticosteroids, intralesional injection of fibrosing agents, interferon a-2b, radiation, electrocoagulation, cryosurgery, laser therapy, embolization and surgical excision. Maximum capillary haemangiomas reported in the literature have been treated with either excision or curettage.[8]

CONCLUSION :

Though a rare benign tumor of the oral cavity, early detection and biopsy of capillary hemangioma is necessary to determine its clinical behavior and potential complications pertaining to dentoalveolar region being associated with it.. clinical importance should be given to oral hemangiomas as

they tend to mimic other lesions in the region so proper diagnosis, investigation and treatment becomes essential. Certain cases of the hemangioma do not regress with time and may present with complication that requires treatment

Reference:

1. Varma S, Gangavati R, Sundaresh KJ, et al. BMJ case Rep. 2013
2. Neville BW, Damm DD, AllenCM, et. Oral and maxillofacial pathology. 3rd edn. St Louis: Saunder, 2008
3. Acikgoz A, Sakallioğlu U, Ozdamar S, et al. Rate benign tumours of oral cavity- capillary hemangioma of palatal mucosa : a case report. Int j paediatr dent 2000;10:161
4. Singh P, Parihar A S, Siddique SN, Khare P. Capillary hemangioma on the palate: a diagnostic conundrum. BMJ Case Rep.
5. Barnes L Tumour-like lesions of the soft tissues. In : Barnes L, ed. Surgical pathology of the head and neck. New York, NY : Marcel dekker, 1985;725-880.
6. A palatal haemangioma in a child: A. M. LALE, P. JANI, N. COLEMAN*, P. D. M. ELLIS. The Journal of Laryngology and Otology July 1998, Vol. 112, pp. 677-678
7. Rare benign tumors of oral cavity- capillary haemangioma of palatal mucosa: a case report. Aydan acikgoz, umur sakallioğlu, sukrü ozdamar & Ata uysal. international journal of paediatric dentistry 2000;10:161-165.
8. Rachappa M, trivedi MN. Capillary hemangioma or pyogenic granuloma: a diagnostic dilemma. contem cli dent 2010;1:119-22
9. Capillary hemangioma of palatal mucosa. Vipin Bharti and Jagmohan Singh; J Indian Soc Periodontol. 2012 Jul-Sep; 16(3): 475–478.
10. Roopika handa, soheyl sheikh, shambulingappa P, amit aggarwal, jyoti mago, sipra salaria; capillary hemangioma of palate: A case report. Pakistan oral & dental journal 2013; 1(33): 55-57.
11. Capillary Hemangioma of Posterior Palatal Mucosa. Khurshid Mattoo, Neha Garg. International Journal of Hematological Disorders, 2015, Vol. 2, No. 2, 29-30
12. Management Of Capillary Hemangioma In The Oral Cavity Of A Pregnant Patient: A Rare Case Report: Veena Raj Vasantha Kumari , Sabari Chandra Mohan , Seema Geetha. Journal of Scientific Dentistry, 6(2), 2016

13. Hemangioma of the Hard Palate in an Elderly Patient as a Life Threatening Surgical Emergency. Sinan Uluyol, MD. The Journal of Craniofacial Surgery .Volume 00, Number 00, Month 2018.
14. Capillary hemangioma of the hard palate: A rare childhood tumor. Rilna, T Guna, Njude, K Raghu. journal of dental and maxillofacial research. 2019.
15. Intraoral Capillary Hemangioma of Hard Palate: Case Report. Dr. I. Venkata Krishna¹ , Dr. GV Reddy² , Dr. Laxmi Shravya³ , S. Sai Veena⁴ , Sowjanya Dadi⁵. International Journal of Science and Research (IJSR). Volume 10 Issue 6, June 2021
16. Cocks EW Jr. Cavernous hemangioma of the oral and hypopharynx. Am J Surg 1961;102:798-802.
17. Shklar G, Meyer I. Vascular tumors of the mouth and jaw. Oral surg oral med oral pathol 1965;19:335-58.
18. Rajendran R, Shivapathasundram B. Benign and malignant tumors of oral cavity. Shafer's textbook of oral pathology. Reed Elsevier India Pvt Ltd, 2006.