

## TAD Assisted Retraction in A Lingual Appliance for Correction of Dentoalveolar Class II Malocclusion

### Abstract:

Orthodontics, in today's contemporary world, is focused mainly on aesthetics. Most of the adult patients are reluctant to orthodontic treatment due to their un-aesthetic appearance. To answer such problems several options are available, ranging from aesthetic brackets, made from tooth-coloured plastic or ceramic, another option is Invisalign, which is restricted to the treatment of only certain kinds of simple malocclusions. Hence, the lingual appliance selected for this case is by far the best option available from the aesthetic outlook and mechanical aspect however torque control of anterior teeth in lingual orthodontic appliance has always been considered a major problem. For maintaining the torque value of anterior teeth either we have to apply direct moment and force to the lingual brackets or by using a different combination of lever-arm and mini-screws mechanics to deliver force in a line that passes through or near to the center of resistance. In the present case, we utilized the combination of long lever-arm and palatal mini-implant system to produce a controlled en-masse retraction of the anterior teeth. This customised long lever arm created by soldering one power to others such that the point of force application is close the center of resistance.

**Keywords:** Tads, lingual orthodontics, lever arm mechanics, Center of resistance, mini-implant.

### Introduction:

Orthodontics, in today's contemporary world, is focused mainly on aesthetics. Most of the adult patients are reluctant to orthodontic treatment due to their un-aesthetic appearance. To answer such problems several options are available, ranging from aesthetic brackets, made from tooth-coloured plastic or ceramic, another option is Invisalign, which is restricted to the treatment of only certain kinds of simple malocclusions, hence from the aesthetic outlook and mechanical aspect, lingual orthodontics [LiO] proves to be the best option for comprehensive treatment of most malocclusions.[1,2]

The appliance selection is only a portion of the therapy since, even in the twenty-first century, with all of the latest innovations, the importance of biomechanics cannot be overlooked. As a result, regardless of the appliance used, biomechanics remains the most important factor in tooth movement, force levels, force directions, and anchor control.[3] One of the most common difficulty that occurs with lingual orthodontic treatment is anterior torque control during the en-masse retraction of the anterior teeth. (Fig 1).

Therefore, thorough knowledge and proper understanding of the biomechanical differences between lingual orthodontics [LiO] and labial orthodontics [LaO] for torque management of anterior teeth during en-masse retraction are required.

The amount of retraction and intrusion of incisors varies in LiO and LaO with the same amount of force because the resultant force in LiO passes lingually to the center of resistance in comparison to LaO. The point of application of resultant force is lingual to the Cres in LiO that's why in LiO, incisors tend to tip palatally than in the labial system (Figure 1). For maintaining the torque value of anterior teeth either we have to deliver direct moment and force to the lingual brackets

<sup>1</sup>MISHRA SHALINI, <sup>2</sup>KUMAR MUKESH, <sup>3</sup>GOYAL MANISH, <sup>4</sup>BHUSHAN PRATEEK, <sup>5</sup>PRIYA PARUL, <sup>6</sup>KAUSHIK SURBHI

<sup>1-6</sup>Department of Orthodontics and Dentofacial Orthopaedics Teerthanker Mahaveer Dental College, Moradabad


**Address for Correspondence:** Dr. Priya Parul  
Post Graduate Student, Department of Orthodontics and Dentofacial Orthopaedics, Teerthanker Mahaveer Dental College, Moradabad.

A 38, Sector 16, New Moradabad Road, Moradabad  
E-mail : parulpriya97425@gmail.com

**Received :** 3 Jan., 2022, **Published :** 30 June, 2022

**How to cite this article:** Mishra, S., Kumar, M., Goyal, M., bhushan, P., Priya, P., & kaushik, S. (2022). TAD Assisted Retraction in A Lingual Appliance for Correction of Dentoalveolar Class II Malocclusion. UNIVERSITY JOURNAL OF DENTAL SCIENCES, 8(2). 67-72

### Access this article online

<b>Website:</b> www.ujds.in	<b>Quick Response Code</b> 
<b>DOI:</b> https://doi.org/10.21276/ujds.2022.8.2.12	

or use a different combination of lever-arm and mini-screws mechanics to deliver force in a line that passes through or near to the center of resistance.[4-6]

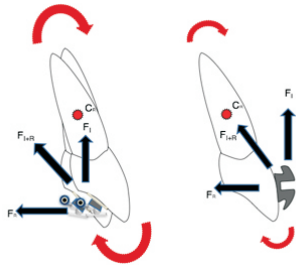


Figure 1. Force vectors in lingual and labial mechanics; CR indicates the center of resistance; FR- retraction force; FI- intrusion force; FI+R-the resultant force.

The introduction of temporary skeletal anchorage devices (TAD)in LiO makes mechanics easy and helps the clinician to pass the resultant force near to the Cres, particularly in individual with Angle Class II malocclusion as TADs along with lever-arm systems serve for controlled en-masse retraction of the upper anterior teeth in LiO. In the lever-arm and TAD system, for achieving the desired tooth movement we have to adjust the length of the lever-arm and the point of force application by changing the TAD placement site.[7]

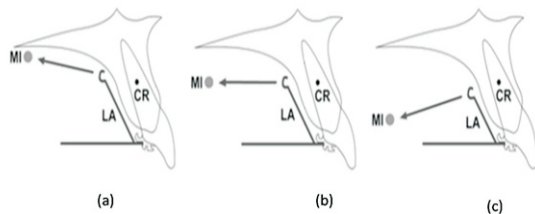


Figure 2. Combinations of different positions of mini-implant and different lengths of lever-arm.

Various combinations of different positions of mini-implant and different lengths of lever-arm were used to achieve different types of movements, for example in figure 2b retraction force parallels to the occlusal plane and applied through the Cres of the upper anterior teeth to achieve translatory movement. In figure 2a where translatory movement is required along with simultaneous intrusion, a clinician should adjust the implant position as well as the length of the lever-arm. The retraction force is re-directed through the center of resistance of the upper anterior teeth as shown in Figure 2c to achieve translation and simultaneous extrusion. [4,8]

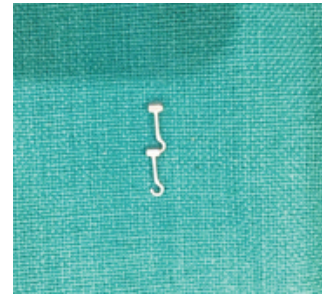


Figure 3. Customized long lever arm was formed by soldering one power-arm to others.

In the present case, we utilized the above-mentioned lever-arm and palatal mini-implant combination to produce a controlled en-masse retraction of the anterior teeth. This customised long lever arm (figure 3) was created by soldering one power-arm to others in such a way that the line of force application passes close to the centre of resistance.

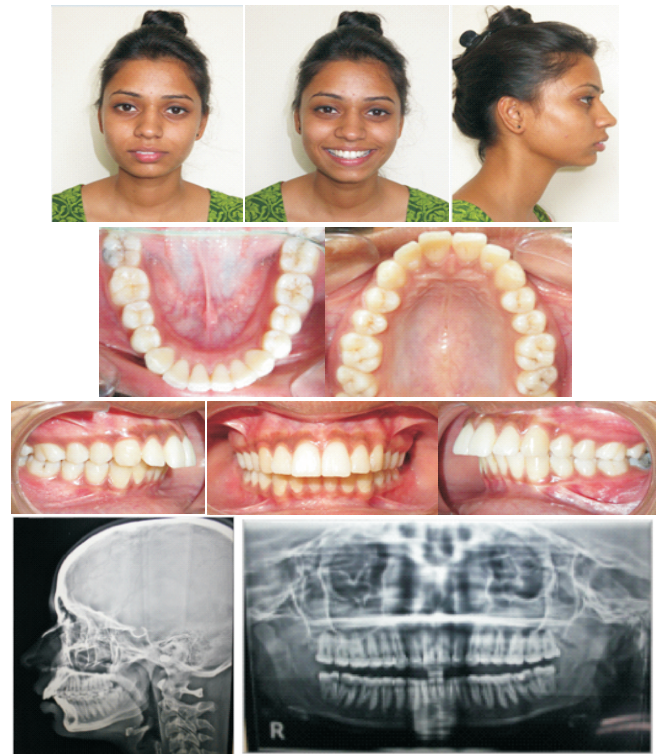

Figure 4. Pre-treatment records.

Table 1. Cephalometric summary

MEASUREMENTS	NORM	PRETREATMENT	POSTTREATMENT
SNA	82°	85°	84°
SNB	80°	81°	81°
ANB	2°	4°	3°
WIT'S Appraisal	0 mm	4 mm	2 mm
MPA	32°	23°	24°
U1/NA	22°	33°	25°
U1-NA	4.0mm	8 mm	3 mm
L1/NB	25°	30°	27°
L1- NB	4.0mm	6 mm	4 mm
IMPA	90°	126°	123°
I/I	131°	93°	135°

### Diagnosis And Etiology:

A 22-year-old female patient presented with the major complaint of forwardly positioned upper front teeth. She exhibited no relevant medical or habit history. An extraoral examination revealed a mesocephalic and mesoprosopic form with a convex profile and a posterior facial divergence with no gross facial asymmetry. The nasolabial angle was acute, with potentially competent lips (Figure 4). Intraoral examination revealed that the patient had a Class II molar and canine relationship with a “U shaped” maxillary and mandibular arch form and proclined maxillary incisors with an increased overjet and overbite with coinciding midlines. The oral hygiene status was average (Figure 4). Temporomandibular joint (TMJ) assessment revealed bilaterally well-coordinated movement with maximum mouth opening of 39 mm (Figure 4).

### Cephalometric Assessment :

A pre-treatment ANB of 5 and MPA 23 was pointing towards a Class II skeletal base and a hypodivergent growth pattern. As clinical examination already revealed proclined upper and lower incisors hence the 1/NA, 1/NB, and IMPA angulations were found to be increased that is 33, 30° and 126° respectively (Table 1, Figure 4).

### Treatment Objectives:

- To achieve ideal levelling and alignment of upper and lower teeth
- To achieve an ideal overjet and overbite.
- To obtain competent lips.
- To achieve good facial balance.
- To achieve a static and functional occlusion
- To maintain the stability of the treatment results.

### Treatment Plan And Alternatives:

Two treatment plans were decided, as the patient was skeletal class II the first being the upper second premolars and lower first premolar extraction, decompensation followed with BSSO advancement with/ without genioplasty. The second one is the extraction of the upper 1st premolars to meet the space requirements with camouflage. The first treatment plan was rejected as the patient wanted a nonsurgical line of treatment. Thus, the second treatment option opted. Due to aesthetic concerns, lingual mechanotherapy was chosen.

### Treatment Progress:

Due to variation in lingual tooth morphology and difficulty in bonding on the lingual surface, it creates the need for custom measurement for the selection of appropriate bracket base thickness and torque. Indirect bonding was chosen to achieve this objective. After completion of laboratory procedures, Fujita lingual brackets were positioned indirectly from the 1st molar to the 1st molar in both arches with 0.018” slots from cuspid to cuspid and 0.022” slots for the posterior teeth. Initial levelling and alignment were accomplished with 0.012” and 0.014” Nitinol arch wires (figure 5) and with twelve months into treatment, gradually progressed to 0.016” × 0.022” stainless steel closing mushroom arch wires were inserted in upper and lower arches to initiate en-mass retraction.

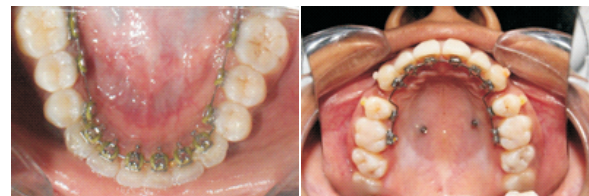

Figure 5. Initial levelling and alignment: Upper arch- 0.014” AJ Wilcock arch wire; Lower arch- 0.012” Nitinol arch wire.

At this point, the lever-arm and mini-screw system were designed to achieve bodily retraction of the anterior teeth without anchorage loss by an innovative approach by soldering one power arm to the other to increase its length and achieve the point of force application as close as possible to the center of resistance of anterior maxilla.

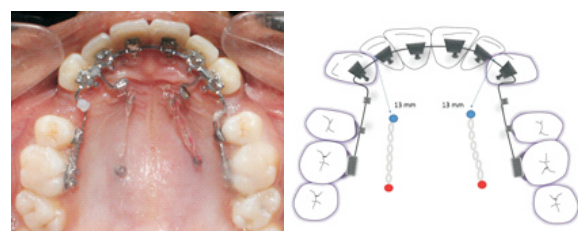


Figure 6. Retraction by lever-arm and mini-implant system

Two mini-screws S.K surgical (2 mm diameter, 10 mm length) were inserted bilaterally in the palatal alveolar bone between the 1st premolar and 1st molars region (Figure 6). After the TADs were installed, all the extraction spaces were closed within 8 months. Thereafter, finishing and detailing was done on 0.014” Ni-Ti arch wires and composite buttons were bonded onto the buccal surfaces of all the canines and lower first premolars for settling the occlusion with the help of settling elastics. Subsequently, the patient was not able to come for her monthly visits due to the outbreak of the COVID

19 pandemic and was forced to get her brackets off at a private clinic at her native place. Later on, when she came to the department, her post-treatment records were taken and a broken mini-implant was found in the OPG (Figure 6) for which the patient was advised a minor surgical procedure to retrieve it but it was postponed till the pandemic subsides as there was no complaint of pain or discomfort by the patient. The overall duration of active treatment was 25 months. (Figure 7).

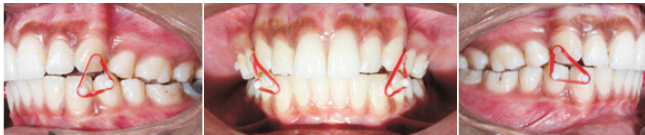

Figure 7. Settling elastics.

**Results:**

The post-treatment facial photographs showed marked improvement in the smile and facial profile. Maxillary anterior teeth protrusion was corrected, and a Class II molar relationship was maintained on the left and right side along with the correction of overjet and overbite (Figure8). The upper incisors to the NA angle had decreased from 33° to 25° and the lower incisors to NB angle decreased from 30° to 27° (Table 1). IMPA had reduced from 126° to 123°. The retraction of the maxillary incisors aided in the improvement of the soft tissue profile.

Cephalometric superimpositions illustrate the reduction in the proclination of maxillary and mandibular incisors (Figure9).

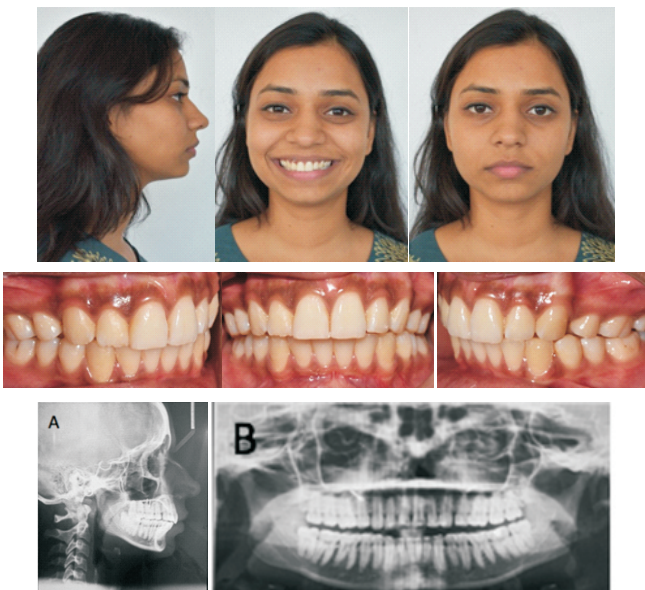


Figure 8. Post-treatment records.

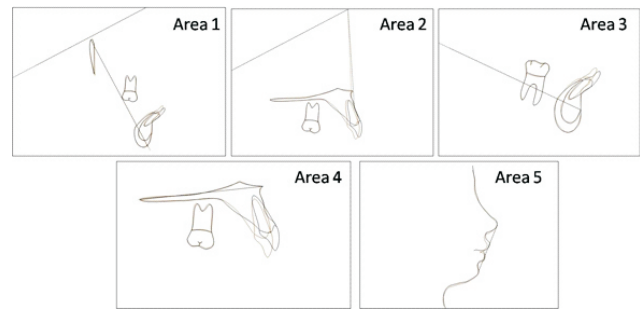


Figure 9. Superimposition: Area 1- Ba-Na at CC; Area 2- Ba-Na at Na; Area 3- At Xi-Pm at Pm; Area 4- ANS-PNS at ANS; Area 5- At aesthetic plane.

**Discussion:**

Torque control during retraction of anterior teeth has always been a problem in lingual mechanotherapy. This is due to change in the position of the force vector of anterior teeth to the Cres which occurs when brackets are changed from the labial surface to lingual. In LiO the resultant force (FR+I) acts more lingually to the Cres of maxillary incisors as compared to LaO. Therefore, a comparatively greater moment is generated when the same magnitude of the force is applied as  $M=F*D$  for an uncontrolled tipping of upper anteriors. To overcome the aforementioned problem, knowledge of the Cres of maxillary anterior and usage of lever arm mechanics for space closure are quite beneficial (Figure 2).[4,9]

According to Bulcke et al, Yoshida N et al, Pendersen et al, and Aravind M et al the Cres of the maxillary anterior segment are located.[7] mm apical to the interproximal bone level or around 13 mm from the incisal edge of the upper anterior in optimal biological conditions. Thus, to achieve bodily retraction of the anterior teeth along its center of resistance and without anchorage loss, the use of long lever arms and mini screws in the palatal area respectively, becomes of utmost importance.[8-11] Lee JS, Creekmore TD, and Kanomi Radvocated that mini screws have a clear edge over other options available like cylindrical end osseous implants, and disc-shaped on plants for anchorage control especially in LiO as they are easy to place in any desired location with minimum difficulty with the added benefit of withstanding immediate loading of force and lastly they cause minimal soft tissue irritation.[12-16]

To select a mini-implant of an appropriate dimension, it is imperative to know the variation in the thickness of soft tissue in the palatal area, as advocated by Park. He also stated that most of the soft tissue in the medial posterior region of the

palate is less than 1 mm thick. Thus, it is important to take into consideration that if screw is to be placed in the palate with thick soft tissue, it should have an adequate dimension else it could easily become dislodged. So, it is very important to assess the soft tissue thickness to determine the appropriate length of the screw.[17]

In the present case report, a lever-arm and mini-screw system were designed so that the force for retraction runs parallel to the occlusal plane and through the Cres of the anterior teeth as advocated by VandenBulcke et al to produce a bodily movement of the upper anterior teeth. Lever-arm mechanics using segmented archwire has an advantage that it is possible to develop a definite and anticipated force system between the six maxillary anterior teeth and buccal teeth during retraction. In this case, continuous stiff archwires were used for anterior teeth retraction as Hong et al proposed that such a system can be either in a continuous or segmented arch until correct biomechanics are applied.[8,4]

The use of long lever arm to induce translatory movement of teeth according to the level of the hook has been proved useful by Finite Element studies done by Park YC and Kim KH et al, but it does come with its fair share of precautions as it has been seen that when the length of the lever arms is extended, they are more prone to elastic deformation with outward rotation of the anterior segment, which might result in linguoversion of the central incisors and buccoversion of the canine. So, to prevent transverse bending in the anterior region, the two arms of the lever should be joined together. Thus, in the present case to prevent unwanted bowing mentioned above teeth were consolidated from canine to canine before retraction was started.[18]

According to Wei Liang et al's three-dimensional finite element analysis, there are significant differences in torque control of the maxillary incisors between LiO and LaO and also concluded that when a force of similar magnitude is applied, a translatory retraction of the upper incisors is seen in LaO and lingual crown tipping in LiO. Thus, it was advised when retracting the maxillary anteriors in LiO a proper moment/force ratio should be maintained and lingual root torque should be increased along with the use of light forces to prevent lingual tipping of anterior teeth.[19]

### Conclusion:

The lever-arm and mini-screw system in lingual orthodontics make the clinician's work easy to control anterior torque loss

during en-masse retraction. Simultaneously by re-directing the screw position and the length of the lever-arm, clinician can easily achieve translation or translation with intrusion or translation with extrusion of anterior teeth. As demonstrated in this case, a mini-screw in conjunction with a lever-arm may be utilised to control the point of force application in the posterior area and generate an optimal force system during en-masse retraction in lingual orthodontic treatment.

### References:

1. Wiechmann D, Wong WK, Hagg EU. Incognito - the novel CAD/CAM lingual orthodontic appliance. *Dent Asia* 2008;19-25.
2. Echarri P. Lingual orthodontics: Patient selection and diagnostic considerations. *SeminOrthod.*2006;12:160-6.
3. Lin W, Fiona Pang KK, Sukie Wong UT, Doshi V. Mini-screws, a viable adjunct along with Incognito lingual appliance: A case series. *APOS Trends Orthod.*2015;5:275-8.
4. Hong RK, Heo JM, Ha YK. Lever-Armand mini-implant system for anterior torque control during retraction in lingual orthodontic treatment. *Angle Orthod.* 2005;75:129-141.
5. Takemoto K. Sliding mechanics versus loop mechanics during en-masse retraction in extraction cases. In: Romano R, ed. *Lingual Orthodontics*. Hamilton, Ontario, Canada: BC Decker; 1998:109–115.
6. Hong RK. *Mushroom Archwire Technique and the Lingual Bracket*. Seoul, South Korea: Jeesung; 2000:58–69.
7. Park YC, Choy K, Lee JS, Kim TK. Lever- arm mechanics in lingual orthodontics. *J Clin Orthod.*2000;34:601-605.
8. VandenBulcke MM, Burstone CJ, Sachdeva RCL, Dermaut LR. Location of the centers of resistance for anterior teeth during retraction using the laser reflection technique. *Am J Orthod Dentofacial Orthop.* 1987;91:375–384.
9. M. Aravind, G.Shivaprakash, G.C Ramesh. Torque control in lingual orthodontics with lever arm mechanics: A case report. *ORTHODONTICS (CHIC)* 2013;14:e186–e196.
10. Yoshida N, Brinkmann PGJ, Koga Y, Mimaki N, Kobayashi K. Experimental evaluation of initial tooth displacement center of resistance and center of rotation under the influence of an orthodontic force. *Am J Orthod Dentofacial Orthop.*2001;120:190-197.

11. Pendersen E, Isidor F, Gjessing P, Andersen K. Location of the center of resistance for maxillary anterior teeth measured on human autopsy material. *Eur J Orthod.*1991;13:452-458.
12. Creekmore TD, Eklund MK. The possibility of skeletal anchorage. *J ClinOrthod.* 1983; 17:266–269.
13. Kanomi R. Mini-implant for orthodontic anchorage. *J ClinOrthod.* 1997; 31:763–767.
14. Lee JS, Park HS, Kyung HM. Micro-implant anchorage for lingual treatment of a skeletal Class II malocclusion. *J ClinOrthod.*2001; 35:643–647.
15. Karaman AI, Basciftci FA, Polat O. Unilateral distal molar movement with an implant-supported distal jet appliance. *Angle Orthod.* 2002; 72:167–174.
16. Kyung SH, Hong SG, Park YC. Distalization of maxillary molars with a midpalatal miniscrew. *J ClinOrthod.* 2003; 37:22–26.
17. Park YC, Lee SY, Kim DH, Jee SH. Intrusion of posterior teeth using mini-screw implants. *Am J Orthod Dentofacial Orthop.*2003;123:690–694.
18. Kim KH, et al. Finite element analysis of the effectiveness of lever arm in lingual sliding mechanics. *Korean J Orthod.* 2011;41(5):324–36.
19. Liang W, Rong Q, Xu B. Torque control of the maxillary incisors in lingual and labial orthodontics: a 3-dimensional finite element analysis. *Am J Orthod Dentofacial Orthop.* 2009; 135:316–22.