

Non-surgical Management of Skeletal Class III and Dental Class I Malocclusion : A Case Report.

Abstract:

This case report discusses the nonsurgical, nonextraction therapy of a female patient, aged 21years, with a skeletal Class III malocclusion, reverse overjet and presence of retained maxillary canine bilaterally. Reverse overjet was corrected by protrusion of maxillary teeth, which contributed to alignment and leveling of teeth. Following fixed orthodontic treatment, there was considerable enhancement in patient's smile as well as an increase in the patient's confidence and quality of life. The profile changes and treatment results were demonstrated with proper case selection and good patient cooperation with fixed appliance therapy. At the end of treatment the patient was extremely satisfied with the results.

Keywords : Skeletal Class III Malocclusion, Reverse Overjet and Overbite, Non-Surgical Orthodontic camouflage.

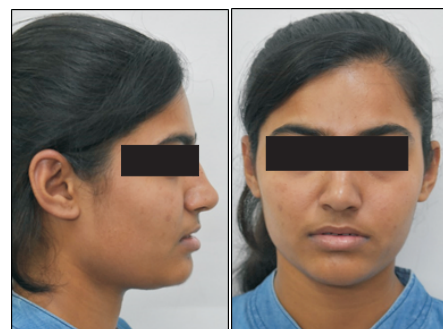Introduction:

It is widely known that inheritance plays a role in the genesis of skeletal class III malocclusion.[1] This relationship may result from a normal maxilla and a mandibular skeletal protrusion or a maxillary retrusion and a normal mandible or a combination of maxillary retrusion and mandibular protrusion.[2] The correct identification of the skeletal case is difficult and necessitates meticulous treatment planning. While the patient's primary complaint is usually a poor aesthetic look, it may also include functional and temporomandibular disorders.[3]

The treatment of choice will be determined by the patient's age, severity of malocclusion, primary complaint, extraoral and intraoral examinations, and cephalometric evaluation. Growing patient with developing Class III malocclusion can be corrected easily with growth modification appliance, however, patients who have reached the end of their growth potential must be camouflaged by orthodontic tooth movement with fixed appliances or corrected surgically.[5] The severity of Class III malocclusion in adults will determine whether the patient is a candidate for orthognathic surgery or orthodontic treatment.[6] The camouflage approach for the correction of class III malocclusion often include proclination

of the upper incisors and retroclination of the lower incisors to correct reverse/negative overjet.

The current case report presented to illustrate non-surgical and non-extraction treatment line of a rare combination of skeletal Class III and dental Class I malocclusion with bilateral over retained deciduous canine in the upper arch.



¹PARUL PRIYA, ²TANISHA SINGH, ³SUMIT TOMAR, ⁴MANISH GOYAL, ⁵MUKESH KUMAR, ⁶NAVNEET KUNJ

¹⁻⁶Teerthanker Mahaveer University

Address for Correspondence : Dr. Parul Priya
Teerthanker Mahaveer University
Email : parulpriya97425@gmail.com

Received : 20 Nov., 2021, **Published :** 31 March, 2022

How to cite this article: Priya, P., Tanisha Singh, Sumit Tomar, Manish Goyal, Mukesh Kumar, & Navneet Kunj. (2021). Non-surgical Management of Skeletal Class III and Dental Class I Malocclusion -A Case Report. UNIVERSITY JOURNAL OF DENTAL SCIENCES, 8(1). 108 - 112

Access this article online

Website:
www.ujds.in

DOI:
<https://doi.org/10.21276/ujds.2022.8.1.21>

Quick Response Code



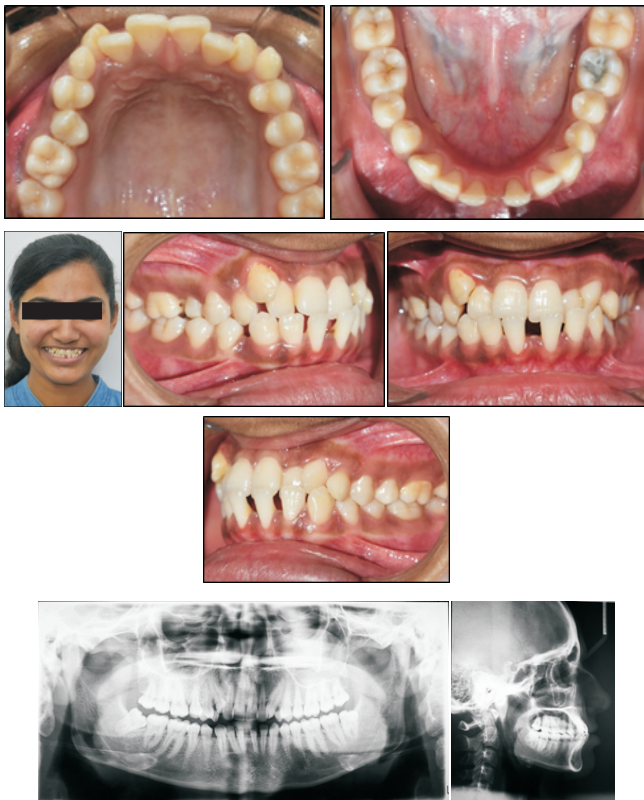


Fig.1,21-year-old female patient with Class I malocclusion with reverse overjet and reverse overbite before treatment.

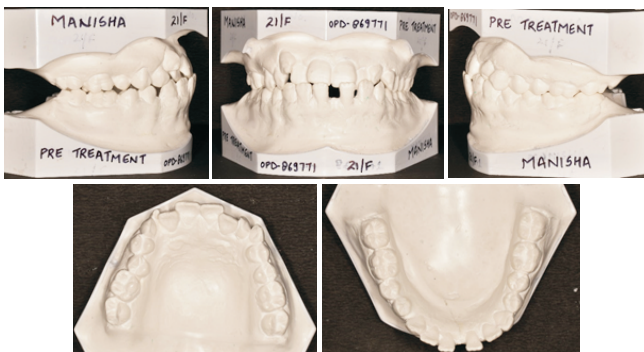


Fig. 2 Pre-treatment models

TABLE 1. Composite analysis suggestive of skeletal class III malocclusion

Sl. no	MEASUREMENTS	RANGE	PRETREATMENT
1	SNB	80°	83°
2	ANB	2°	-2°
3	WITS appraisal	-4.5-1.5 mm	-4mm
4	β-angle	27°-35°	37°
5	Yen angle	117°-120°	122°
6	W angle	51°-56°	61°
7	Articulare angle (S-Ar-Go)	143°±6°	132°
8	Facial axis (B-Na to Ptm-Gn)	90°	93°

TABLE 2. Comparison of pre- and post-treatment cephalometric values

Sl. no	MEASUREMENTS	RANGE	ACTUAL	
			PRE-TREATMENT	POST-TREATMENT
1	SNA	82°	81°	82°
2	SNB	80°	83°	83°
3	ANB	2°	-2°	-1°
4	Mandibular plane angle (SN-Go-Me)	32°	23°	24°
5	Y-axis {S-N to S-Gn}	66°	64°	65°
6	U I to N-A(mm)	4mm	8mm	9mm
7	U I to N-A(angle)	22°	32°	34°
8	L I to N-B (mm)	4mm	7mm	4.5mm
9	L I to N-B (angle)	25°	36°	24°
10	U I to LI (Interincisal -angle)	131°	109°	119°
11	Upper incisor to S-N plane	102° ± 20	114°	116°
12	IMPA (Incisor mandibular plane angle)	90°	109°	96°
13	S line to Upper lip	0-2 mm	-3mm	-2mm
14	S line to Lower lip	0-2 mm	2mm	0mm
15	H angle	7° - 15°	10°	11°
16	Nasolabial angle	94° - 110°	100°	98°

Diagnosis:

A 21-year-old female presented to the department of orthodontics and dentofacial orthopedic, with the chief complaint of great dissatisfaction with her smile and irregularly placed upper and lower front teeth. On clinical examination she revealed an orthognathic profile and an average clinical FMA, with no facial asymmetry. The upper incisors and buccal corridor were adequately exposed in her social smile. The facial and dental midlines were coincident. Intraoral examination revealed a bilateral class I molar and premolar relationship with anterior reverse overjet of -1mm and overbite of -2mm,over erupted lower incisors with midline spacing and a 2mm curve of spee. Presence of retained deciduous in relation to 53,63 had resulted in crowding in anterior region of upper arch with rotations of [13,14,15,16,23,24] (Fig.1). Partial crossbite i.r.t.[15,45]. Cephalometric analysis (Table 1) revealed skeletal Class III malocclusion (ANB, -2 degree) with hypodivergent growth pattern (SN-GO-Me, 23 degree), with proclined upper and lower incisors (U I to N-A= 32 degree/8mm, L I to N-B= 36 degree/8mm) (Table 2).

Treatment Objective:

Treatment objectives focused on (a) ideal alignment of upper and lower teeth, (b) correction of anterior crossbite, (c) achieving class I canine relation bilaterally, (d) improve smile aesthetic, (e) maintain a bilateral class I molar relationship, (f) improve facial harmony with the ideal overjet and overbite.

The proposed treatment plan was camouflage orthodontic treatment by extraction of the maxillary retained deciduous canine bilaterally, to relieve upper anterior crowding.

Treatment Progress:

The lower arch was bonded first with an (0.022" × 0.028" slot) with MBT prescription (3M Unitek). Levelling and alignment was initiated on a round 0.016" nickel titanium (NiTi) archwire. Simultaneously the maxillary deciduous canine was extracted bilaterally. One week later, the patient was instructed to wear a removable posterior bite plate in the upper arch (3mm thick in the premolar region) for eight weeks. This disocclude the bite and facilitate correction of anterior cross bite. Four months later, a lower 0.016" × 0.022" SS arch wire was engaged for complete levelling and alignment. Later, on power arm was placed on 0.017"x0.025" SS archwire bilaterally to deliver class I force for closure of existing space. Six months later, sectional bonding in the upper arch (canine to canine) was done and 0.012" nickel titanium arch wire was placed (Fig. 3), in intention to de-crowd the maxillary anterior segment as well as to retract the maxillary permanent canine into the extraction spaces. This force driven approach results in Row-Boat Effect[7] and mesially tipping of maxillary canine in adjuvant, facilitate mild proclination of incisors which favoured our objective. Once the anterior cross bite was corrected the bite plate was removed after one month of sectional bonding. Banding and bonding was then done to all other maxillary teeth, and a transpalatal arch (TPA) was fabricated for anchorage. Levelling and alignment of upper arch was continued with 0.016" and 0.018" NiTi arch wires and completed using 0.016"x0.022" SS arch wire. Class III elastics were used effectively for correction of overjet as well as overbite. After 11 month of treatment, continuous elastic chain from molar to molar was given on upper and lower arch (Fig. 4).

Finishing and detailing were done using 0.014" NiTi arch wire with light settling elastics (3.5oz and 5/16"). After a total of 13 month of therapy the fixed orthodontic appliance was removed, a 2 to 2 fixed retainer was bonded in the upper as well as 3 to 3 fixed retainer was bonded in the lower arch, along with an ESSIX removable retainer was given to the patient.

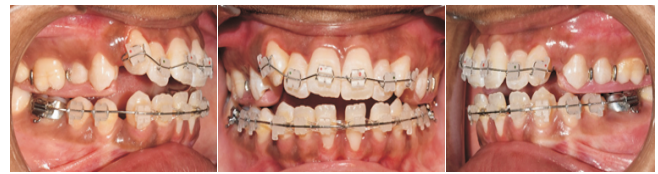

Fig. 3 Sectional bonding in upper arch

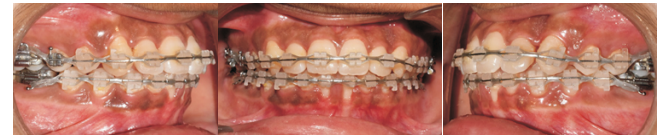
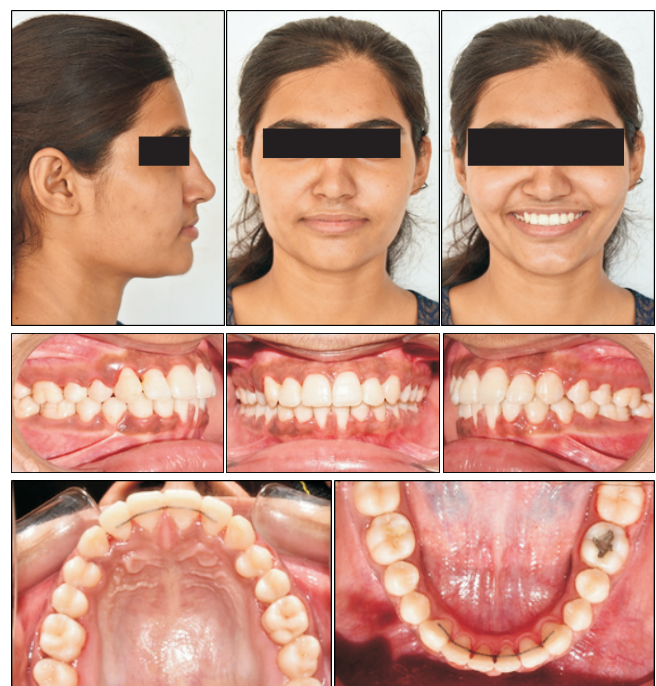
Fig. 4 Continuous E-chain from molar to molar in upper and lower arch

Treatment Result:

After finishing and detailing Class I canine relationship was achieved bilaterally whereas Class I molar relationship remains bilaterally. The patient's primary complaint of anterior crossbite was satisfactorily alleviated and ideal overjet and overbite and a stable occlusion with good intercuspation was achieved. Extraoral pictures revealed a relaxed lip closure and a pleasing smile with a consonant smile arc, meeting the patient's expectations (Fig.5). The ortho pantomogram demonstrated adequate root parallelism with no apical resorption. Maxillary and mandibular cephalometric superimpositions confirmed that the maxillary anteriors were proclined and the mandibular incisors were up righted (Fig.7).



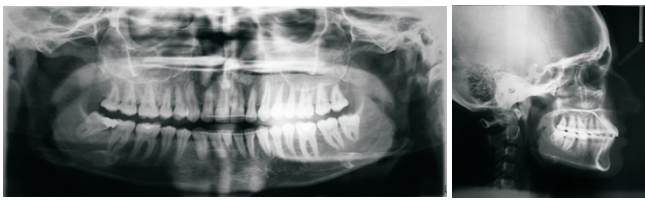

Fig. 5 Post-treatment extraoral, intraoral photographs and radiographs

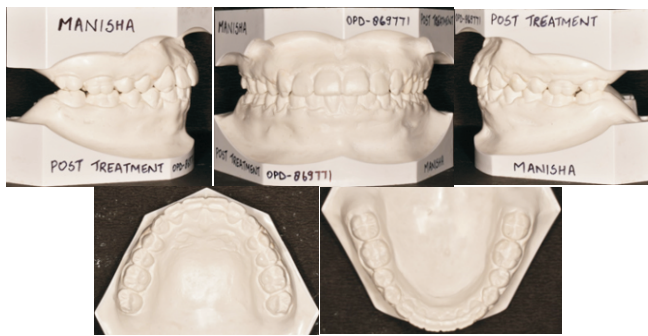

Fig.6 Post-treatment models

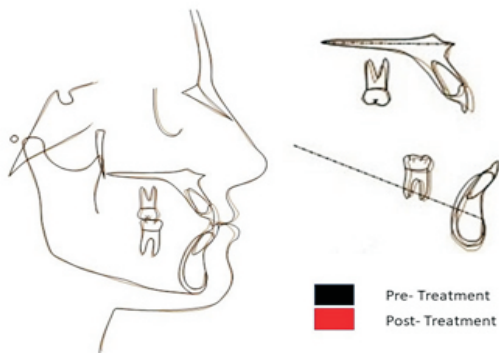


Fig.7 Overall, maxillary and mandibular cephalometric superimpositions

Discussion:

Treatment of a Class III malocclusion with reverse overjet and reverse overbite is challenging. Reverse overjet occurs when the mandible is 'oversized', or the maxilla is undersized or a combination of both.[4] Ellis and McNamara in their study of adult population with class III malocclusion discovered a combination of maxillary retrusion and mandibular protrusion to be the most prevalent skeletal relationship. Although our case presented with skeletal class III malocclusion with reverse overjet, she exhibited class I molar relationship bilaterally with retained deciduous upper right and left canine. In such cases ortho-surgical treatment is necessary to provide satisfactory results, but patients are often

sceptical about undergoing orthognathic surgery and prefer a non-surgical alternative.[5] Therefore, for improving the occlusal and incisal relationship between the maxillary and mandibular jaw bases in mild to moderate skeletal discrepancies, orthodontic camouflage is an alternative therapy that can be considered.[6]

Not all cases of class III malocclusion require surgery. According to Rabie et al.[8], the Holdaway angle can be a reliable reference in identifying the treatment modality of these individuals. They further suggested that patients with a Holdaway angle more than 12 degree can be effectively treated by orthodontics alone while patients with Holdaway angles less than 12 degree would require orthosurgical therapy. According to Kerr et al.[9], individual with ANB of less than 4 degree and IMPA of less than 83 degree are recommended for surgery. Furthermore, Tseng et al.[10] proposed a predictive model with overjet ≤ -2.73 mm, wits appraisal ≤ -11.18 mm, LI-MP angle ≤ 80.8 , Mx/Mn ratio $\leq 65.9\%$, overbite ≤ -0.18 and gonial angle ≤ 120.8 as the minimum number of discriminators required to achieve optimum discriminant effectiveness of diagnosis between surgical and non-surgical treatment of skeletal class III malocclusion. In our situation, (Table 3) these values pointed us in the direction of non-surgical treatment.

Presence of retained deciduous canine usually resulted in impacted and transposition of permanent canine.[11] In our case, although right and left maxillary canine was retained, the permanent canine erupted in the arch, making our case considerably distinct from typical cases previously reported in the literature.[12-14] Hence, in this case, we planned the treatment by orthodontic camouflage, which was in adjuvant with extraction of retained teeth. For rectifying maxillary anterior crowding in skeletal Class III malocclusions, mild proclination of the anteriors is an acceptable compromise.

With the non- extraction therapy in the mandibular arch, excessive retroclination of lower incisors was avoided because patient with skeletal Class III have concave profiles and thin basal bone over the symphysis[15] which can induce unwanted complications such as dehiscence and incisors root resorption.[16,17] Class III elastics were used effectively to eliminate residual spaces and correction of overjet and overbite which gave us quite good results.

Table 3. Cephalometric readings suggestive of non- surgical line of treatment

Sl. no	MEASUREMENTS	PRETREATMENT
1	Overjet	-1mm
2	Wits	-4mm
3	L1-MP angle	109°
4	Overbite	-2mm
5	Gonial angle	122°

Conclusion:

Orthodontic limitations in a class III patient have to be identified early to determine whether an orthodontic camouflage can be performed or an orthognathic surgery would be needed. Camouflage has its limitations in terms of the soft tissue changes that can be achieved. The orthodontic camouflage is a form of dental displacement along with its supporting tissues to compensate for a maxillomandibular discrepancy. The treatment of such malocclusions has to be planned adequately based on the treatment objectives, stability of the changes achieved, and acceptability of treatment by the patient. The discussed case report achieved good functional stability as well as aesthetic acceptability.

References:

1. Souza PÁ. Angle Class I malocclusion with anterior negative overjet. *Dental Press J Orthod.* 2016;21(2):102-114.
2. William S, Andersen CE. The morphology of the skeletal potential Class III skeletal pattern in the growing child. *Am J Orthod* 1986;89:302-11.
3. Proffit WR, Fields HW, Moray LJ. Prevalence of malocclusion and orthodontic treatment need in the United States: Estimates from the NHANES III survey. *Int J Adult Orthodon Orthognath Surg.* 1989;13(2):97–106.
4. Stellzig-Eisenhauer A, Lux CJ, Schuster G. Treatment decision in adult patients with Class III malocclusion: orthodontic therapy or orthognathic surgery” *Am J Orthod Dentofacial Orthop.* 2002;122(1):27-37.
5. Kapadia RM, Shah AP, Diyora SD, Rathva VJ. Non-surgical treatment of skeletal class III malocclusion. *BMJ Case Rep.*10;2014:bcr2013202326.

6. Bhandari PK , Anbuselvan G.J. Nonsurgical management of class III malocclusion: A case report. *J Indian Acad Dent Spec Res.* 2014;1(1):35-38.
7. Kim SJ, Kim JW, Choi TH, Lee KJ. Combined use of miniscrews and continuous arch for intrusive root movement of incisors in Class II division 2 with gummy smile. *Angle Orthod.* 2014 Sep;84(5):910-8
8. Rabie AB, Wong RW, Min GU. Treatment in borderline class III malocclusion: orthodontic camouflage (extraction) versus orthognathic surgery. *Open Dent J.* 2008;2:38–48.
9. Kerr WJ, Miller S, Dawber JE. Class III malocclusion: surgery or orthodontics” *Br J Orthod.* 1992;19:21–4.
10. Tseng YC, Pan CY, Chou ST, Liao CY, Lai ST, Chen CM, Chang HP, Yang YH. Treatment of adult Class III malocclusions with orthodontic therapy or orthognathic surgery: receiver operating characteristic analysis. *American Journal of Orthodontics and Dentofacial Orthopedics.* 2011;31;139(5):e485-93.
11. Bishara SE. Impacted maxillary canines: A review. *Am J Orthod Dentofacial Orthop.* 1992;101:159–71.
12. Becker A, Chaushu S. Etiology of maxillary canine impaction: a review. *Am J Orthod Dentofacial Orthop.* 2015;148(4):557-67.
13. Sajnani AK. Permanent maxillary canines - review of eruption pattern and local etiological factors leading to impaction. *J Investig Clin Dent.* 2015;6(1):1-7.
14. Julia Naoumova, Jüri Kürol, Heidrun Kjellberg, Extraction of the deciduous canine as an interceptive treatment—part II: possible predictors of success and cut-off points for a spontaneous eruption, *European Journal of Orthodontics.*2015;2(37):219–29.
15. Yang WS. Morphology of mandibular symphysis and positioning of lower incisors in the skeletal Class III malocclusion. *Korean J Orthod* 1985;15:149-53.
16. McFadden WM, Engstrom C, Engstrom H, Anholm JM. A study of the relationship between incisor intrusion and root shortening. *Am J Orthod Dentofacial Orthop* 1989;96:390-6. 18.
17. Kaley J, Phillips C. Factors related to root resorption in edgewise practice. *Angle Orthod* 1991;61:125-32.