

Interdisciplinary Orthodontics- A Combined Ortho-surgical Approach For Treating Skeletal Class II : Case Report

Abstract:

This case reports shows the successful treatment of Skeletal class II malocclusion with an end-on molar relation on both right and left side with overjet of 8mm and overbite of 6mm in a 19 year old female patient through Bilateral Sagittal Split Osteotomy (BSSO) Advancement, performed by oral and maxillofacial surgeon. With the combined orthodontic and orthognathic surgical approach; the correction of skeletal and dental imbalance, functional occlusion, dental and skeletal Class I relationship was achieved with minimal appointment.

Keyword :

Introduction:

Skeletal Class II malocclusion is due to either maxillary prognathism, mandibular retrognathism or a combination of both. The treatment approach of skeletal class II depends upon the growth status of the patient. In growing individuals this can be corrected by growth modulation (myofunctional appliances)[1]. However in non-growing or adults, pleasing esthetics and functional efficacy can be achieved by combining orthodontic and surgical approach. Proper diagnosis and treatment planning are the key factors for the successful management of skeletal class II cases. The treatment of severe dentofacial deformities in adult patients is challenging and arduous task for both orthodontist and oral surgeon. Treatment is difficult because of the skeletal and facial disharmony, absence of jaw growth and propensity to relapse,[2,3]

Bilateral Sagittal Split Osteotomy is very popular and versatile procedure performed intraorally on mandibular body and ramus. Osteotomy is an indispensable surgical procedure for the correction of lower jaw deformities. The osteotomy splits the ramus and the posterior body of the mandible sagittally, which allow either set-back, advancement or

rotation. Adult patients with severe skeletal malocclusions require orthognathic surgeries.

The case with skeletal Class II malocclusion due to retrognathic mandible is discussed in this article which was treated by bilateral sagittal split osteotomy mandibular advancement. Case was treated by 0.022 Pre Adjusted Edge-wise appliance with MBT prescription.

Clinical Examination:

A 19 year old female patient reported to the department of orthodontics and dentofacial orthopaedics with the chief complaint of forwardly placed upper front teeth and short lower jaw.

¹GAURAV SHARMA, ²YASH PATEL, ³ASHISH GUPTA, ⁴RASHMI PURI ⁵SURESH SHARMA, ⁶VATSALSINGHVI
¹⁻⁶Dept. of Orthodontics, Vyas Dental College, Jodhpur, Rajasthan

Address for Correspondence : Dr. Yash Patel
 Vyas Dental College and Hospital, Near Kudihaud,
 New Pali Road, Jodhpur, Rajasthan
 E-mail : ya.patel6671@gmail.com

Received : 29 Sep., 2021, **Published :** 31 March, 2022

Access this article online	
Website: www.ujds.in	Quick Response Code 
DOI: https://doi.org/10.21276/ujds.2022.8.1.15	

How to cite this article: Gaurav Sharma, Patel, Y., Ashish Gupta, Rashmi Puri, Suresh Sharma, & Vatsal Singhvi. (2021). Interdisciplinary Orthodontics- A Combined Ortho-surgical Approach for Treating Skeletal Class II Malocclusion. UNIVERSITY JOURNAL OF DENTAL SCIENCES, 8(1). 81 - 87

On extra-oral examination, profile examination revealed a convex profile, average nasolabial angle, deep mentolabial sulcus, and potentially incompetent lips (fig 3).

TMJ examination shows no history of pain or clicking while various jaw movements. The right and left excursive movements were normal with a maximum mouth opening of 46 mm.

On intraoral examination, patient had complete set of teeth, end-on molar relation on both sides, end-on canine relation on both sides, class II div 1 incisor relation, overjet of 8mm, overbite of 6mm and mesio-labial rotation of teeth with 45 (fig 1,2).

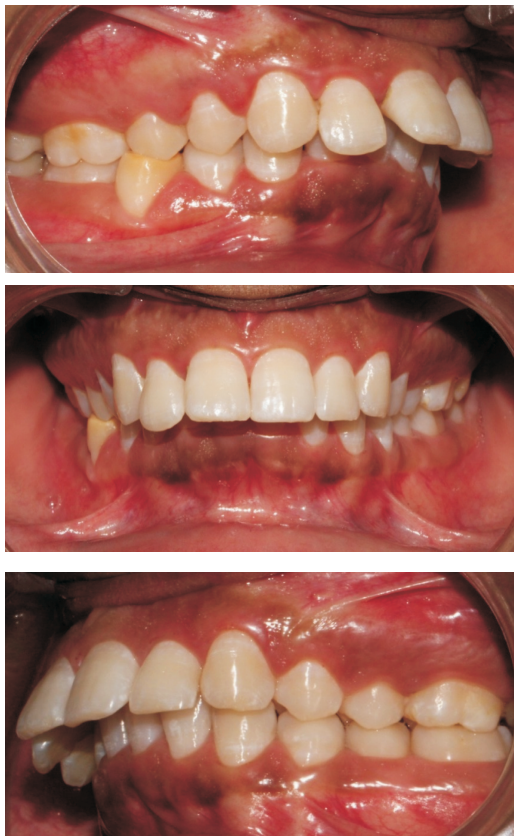

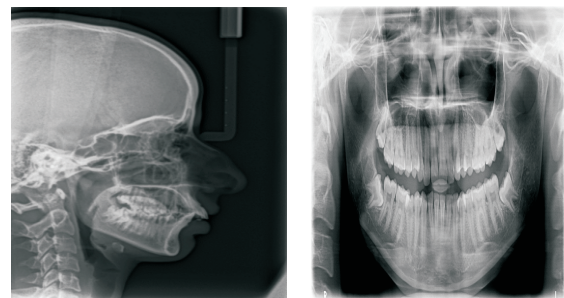
Figure 1 Pre-Treatment Intra Oral Photographs

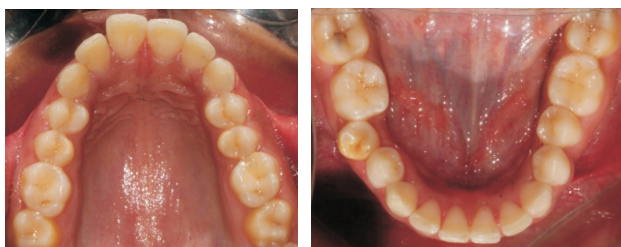

Figure 2. Pre-Treatment Occlusal Photographs

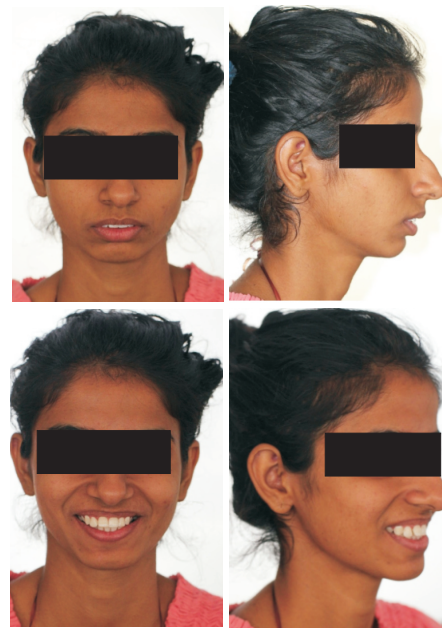

Figure 3 Pre-Treatment Extra Oral Photographs



Pre Treatment Radiographs – Mesio-Angular Impacted 38, 48

Diagnosis:

- Skeletal: Class II skeletal jaw base ($ANB = 8^\circ$) with anteriorly placed maxilla ($SNA = 85^\circ$) and posteriorly placed mandible ($SNB = 75^\circ$), and normodivergent to hyperdivergent growth pattern ($FMA = 27^\circ$) (table 1).
- Dental: Angle's Class II div 1 malocclusion with proclined lower incisors, overjet of 8mm and overbite of 6mm end-on molar relation on both sides, end-on canine relation on both sides, class II div 1 incisor relation, upper and lower midlines not coinciding and mesiolabial rotation with teeth 45.
- Soft tissue: Patient had convex profile, average nasolabial angle, deep mentolabial sulcus, and potentially incompetent lips.

History:

Patient does not give any relevant medical history.
 Patient gives history of thumb sucking 5 years back.

Problem List:

- Skeletal Class II jaw with Retrognathic Mandible (reduced corpus size Go-Pg linear 56mm according to COGS Analysis)(table 2)
- Increased overjet
- Proclined upper and lower anteriors
- Rotated teeth with respect to 45(mesio-labial)
- Convex profile
- Deep mentolabial sulcus
- Short upper lip
- Incompetent lips

Treatment Objective:

- Correction of Skeletal Discrepancy
- Correction of rotation.
- Correction of upper and lower incisor axial inclination.
- Establishment of proper overjet and overbite.
- Establishment of class I molar and canine relationship.
- Establishment of lip competency.
- To achieve aesthetic harmonious profile.

To maintain the stability of the result.

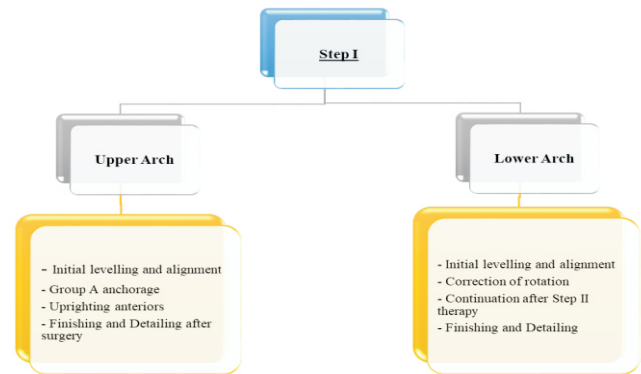
Cephalometry Analysis:

Parameter	Normal	Pre treatment value	Post treatment value
SNA	82°±2°	85°	84°
SNB	80°±2°	75°	80°
ANB	2°	8°	4°
Mandible Eff. Length(Co-Gn)	-	85.5 mm	91mm
Ramus height	50.25 mm	48 mm	59 mm
Sn- GoGn	32°	30°	35°
FMA	25°	27°	30°
UI-SN	102°	116°	108°
LI-FH	65°	54°	60°
Soft tissue profile	161°	141°	150°
Nasolabial angle	97°±2°	106°	96°
Mentolabial sulcus	122°±7°	70°	108°
Inter incisal angle	133°±2°	111°	123°

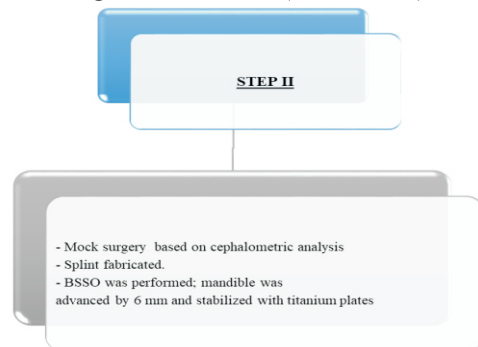
Parameter	Standard value	Patient value	Inference
Cranial base: Ar-PTM(II HP) PTM-N(II HP)	36.1+/- 2.8mm 52.8+/-2.9mm	29mm 50mm	Post. cranial base decreased and ant. cranial base length normal
Horizontal N-A-Pg N-A(II HP) N-B(II HP) N-Pg(II HP)	4.15+/-3.7° -4.46+/-3.7mm -11.17/-6.7mm -10.44+/-5.5mm	15° +2mm -11mm -8mm	Convex profile Maxilla is anteriorly placed Mandible is backwardly placed Chin is normally placed
Vertical N-ANS(perp HP) PNS-N(perp HP) ANS-Gn(perp HP) MP-HP ANGLE U1-NF(perpNF) L1-MP(perp MP) U6-NF(perp NF) L6-MP(perp MP)	52.12+/-7.26mm 53.08+/-4.88mm 61.85+/-4.40mm 23+/-4.88° 27.28+/-3.12mm 40.24+/-2.90mm 22.38+/-4.85mm 32.51+/-3.55mm	45mm 47mm 56mm 24° 25mm 36mm 24mm 21mm	Anterior maxilla normal Reduced post. height of max Lower vertical height reduced Normodivergent Normal eruption Infraeruption Normal eruption Infraeruption
Maxilla, mandible: PNS-ANS(II HP) Ar-Go(linear) Corpus Size Go-Pg(linear) B-Pg(II MP) Ar-Go-Gn(angle)	50.78+/-4.6mm 46.91+/-4.1mm 74.61+/-5.68mm 6.07+/-1.7mm 122.96+/-9.75°	53mm 38mm 56mm 7mm 113°	Normal size of maxi. base Reduced ramus height Reduced corpus size Chin normal Decreased Angle
Dental: OP upper to HP OP lower to HP A-B (II OP) U1 NF(angle)	10.44+/-4.31° -2.46+/-2.21mm 116.67deg +/- -6.67° 92.21deg+/- 10.31°	8° 6mm 123° 103°	Normodivergent Class II skeletal base Normal inclination of upper ant. Normal

Table 2

Treatment Plan:



Step 1. Pre surgical Orthodontic (Fixed Phase)



Step 2. Surgical Approach (BSSO Advancement Surgery)

Pre-Surgical Phase:

A full fixed preadjusted appliance (MBT prescription with .022 slot by Ortho Organisers O2) was placed. Alignment & leveling of maxillary & mandible arches were done with:

·0.014 Niti followed by 0.016 Niti, 0.018 Niti, 0.017" × 0.025" Niti and 0.019" × 0.025" Niti. After which 0.019" × 0.025" stainless steel (SS) stabilizing wire was placed.

Upper and lower arches were coordinated and patient was asked to bring her mandible forward to look for any occlusal interference and recheck VTO and presurgical records were taken.(fig 5)

Before undergoing surgical procedure the patient's molar relation was Class II and end on canine relation and there was no increase in overjet because of the expansion of upper arch and correction of the lower rotated second premolar which led to loss in space and proclination of lower anteriors and thus the overall overjet was maintained.(fig 6,7,8)

With the help of prosthodontist facebow transfer was done(fig 9) and patients cast were mounted on the articulator followed by which the mock surgery was performed based on COGS cephalometric prediction⁴ and surgical splint was fabricated.(fig 10)

VTO-Visual Treatment Objectives

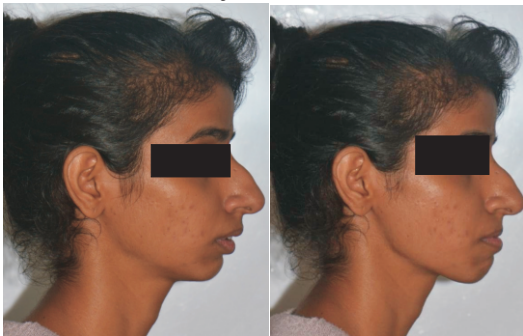

Figure 5

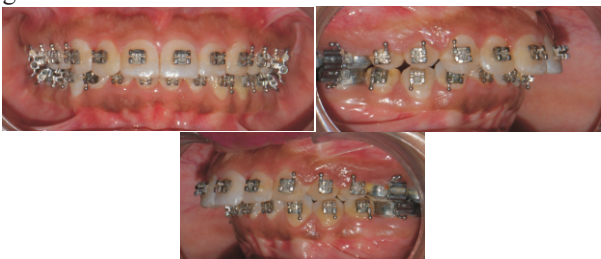


Figure 6 Mid-Treatment Intra Oral Photographs

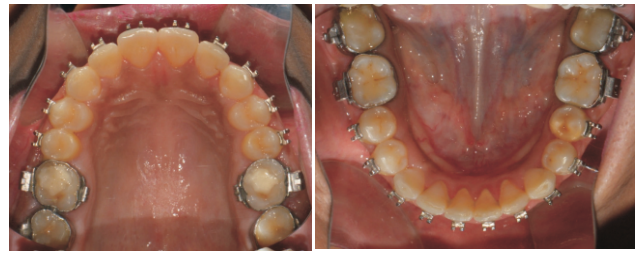

Figure 7 Mid-Treatment Occlusal Photographs

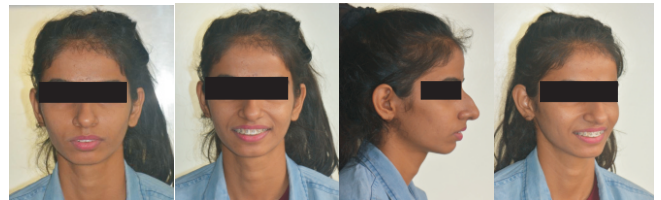

Figure 8 Mid-Treatment Extra oral Photographs

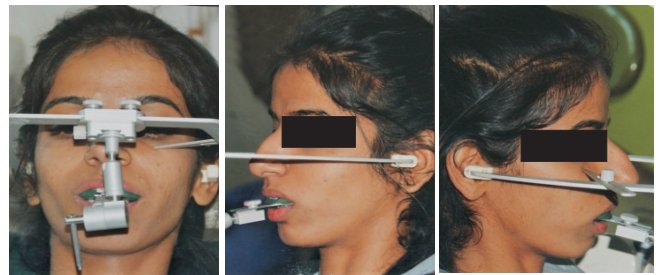

Figure 9 Facebow Transfer




Figure 10 Mock Surgery

Surgical phase:

Under general anesthesia advancement, BSSO was performed by oral and maxillofacial surgeon, mandible was advanced by 6mm and surgical splint was placed in patients

mouth followed by intermaxillary fixation and stabilization by titanium plates.(fig 11,12)

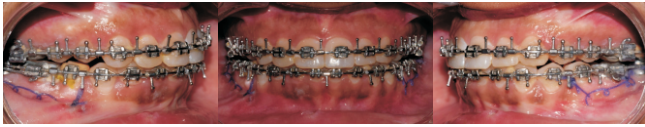

Figure 11 Post Surgical Intraoral Photographs

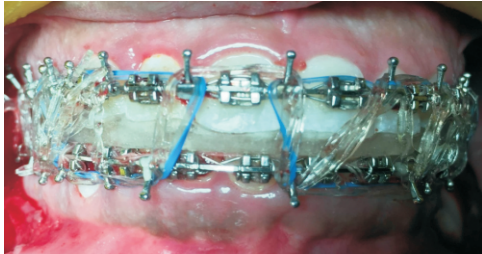


Figure 12 Inter Maxillary Fixation

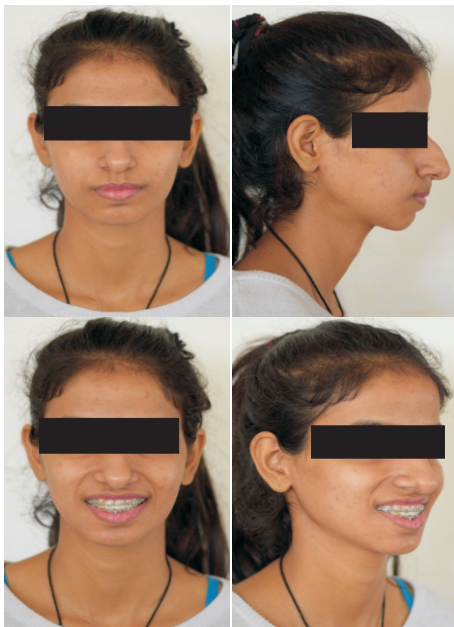

Figure 13 Post Surgical Extra Oral Photographs

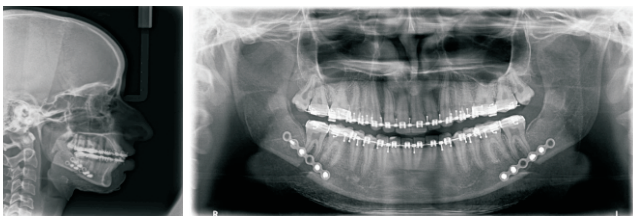


Figure 14 Post Surgery Radiographs

Post-surgical phase

For extrusion of posteriors, proper occlusion and closing of bite, patient was shifted to 0.014 SS wire in maxillary and

mandibular arch. Box shaped elastics were given for settling on both right and left sides for a period of 2 months.

Retention Plan

After completion of treatment the patient was given Begg's wrap-around retainer followed by fixed lingual retention in both maxillary and mandibular arch to prevent relapse.(fig 16)

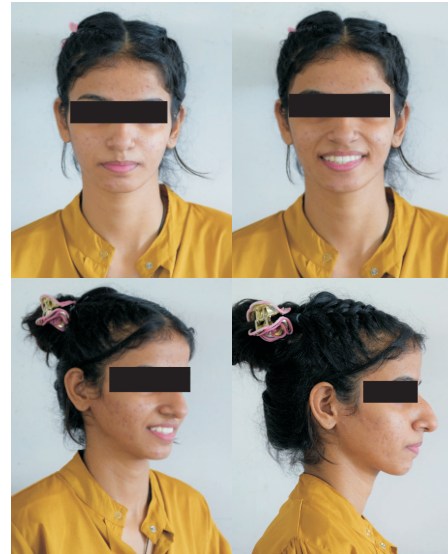

Figure 15 Post Treatment Extraoral Photographs

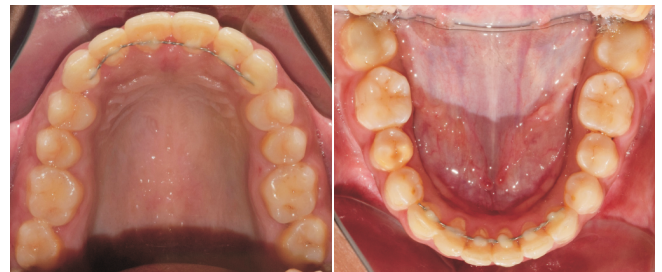

Figure 16 Post Treatment Occlusal Photographs

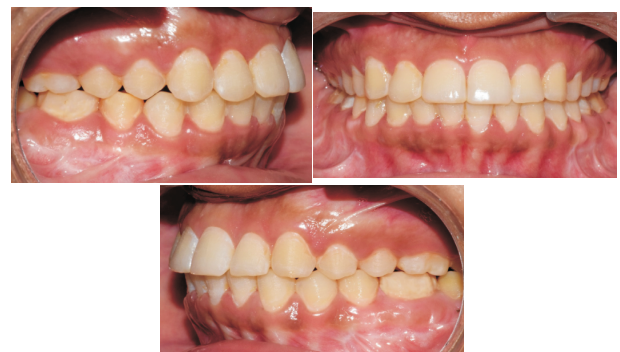

Figure 17 Post Treatment Intraoral Photographs

Treatment Result:

Comparing with the pre-treatment records; post treatment records showed marked improvement in facial profile and skeletal and dental problems were resolved.(fig 15) Overjet and overbite of 2mm , Angles Class I molar and canine relationship was achieved.(fig 17) Superimposition of Pre and Post surgery lateral Cephalograms showed that the treatment goals and objective were achieved.(fig 18) The patient's prime concern regarding the aesthetics was satisfied. The patient was happy with the treatment outcome.

Discussion:

Class II Malocclusion has been called the most frequent treatment problem in the orthodontic literature. Among the various jaw based discrepancies that exist, a Class II Skeletal pattern is probably the most prevalent one. It comprises a group of specific skeletal, dental and facial features. It is second in frequency, distribution and prevalence among all malocclusion cases. It is the most frequently encountered and treated malocclusion in orthodontic practice.⁵

There can be two treatment modalities for correction of class II malocclusion.

1. Early treatment (during growth phase)
2. Late Treatment (after growth completion)

In this case since the patient was non growing we were left with the option of late treatment modality which included of extraction procedure and surgical procedure. On examination, Visual treatment objective was positive and cephalometric analysis showed the need for mandibular advancement which can be carried out by using fixed functional orthodontics, or extraction of upper 5's and lower 4's for decompensation with BSSO or BSSO Advancement Surgery without decompensation.

But in this case patients nasolabial angle is average and if we go about with extraction with decompensation, it would worsen the facial profile. Looking to the patients need for minimum treatment time henceforth, we proceeded with BSSO Surgery without Decompensation.

Orthognathic surgery is becoming a common treatment alternative in the correction of dentofacial deformities. Persons with significant jaw malrelationships or with limitations due to lack of growth have treatment alternatives orthodontic mechanics alone or a combined surgical-orthodontic approach. Surgical jaw repositioning often allows the most ideal correction of etiologic factors, whereas orthodontic tooth movement alone is directed toward compensating for the skeletal malrelationships. BSSO was chosen owing to advantages like initial correction of complex skeletal problems, will normalize surrounding soft tissues lips, cheeks, and tongue which facilitate postoperative tooth movement and reduce the length of orthodontic treatment.⁶

The patient was advised to perform exercises for orbicularis oris and circumoral muscles i.e

1. Upper lip should be stretched over the lower lip in an attempt to touch the chin.
2. Pump hot salt water back and forth behind the lips 4 to 5 times and spit it out and repeat it.

Post-treatment result showed improved facial aesthetics and dental occlusion.

Patient was successfully treated by interdisciplinary approach over 14 months. The aims of treatment were accomplished, and the patient's concerns were addressed appropriately. patient was notably pleased with the treatment outcome. Good occlusal and aesthetic results were achieved, and this was reflected in her post-treatment one year follow up. (fig-19,20,21,22)

- Skeletal base relationship was improved.
- Ideal overjet and overbite was achieved.
- Class I molar and canine relation was achieved.
- Profile was improved markedly.
- Lip competency was achieved.
- Good functional occlusion was achieved.

Conclusion:

Bilateral Sagittal Split Osteotomy is one of the successful treatment option in correction of mandibular skeletal malocclusion and has good prognosis.

With ideal case selection, proper diagnosis and Orthodontic treatment planning with BSSO provides significant advantages.

1. Immediate profile improvement
2. Reduced treatment time

Proper mock surgery and surgical splint fabrication are the key elements for successful BSSO surgery. It is of the utmost importance to have an interdisciplinary approach during the planning of the surgical-orthodontic treatment for establishing objectives and obtain good results.

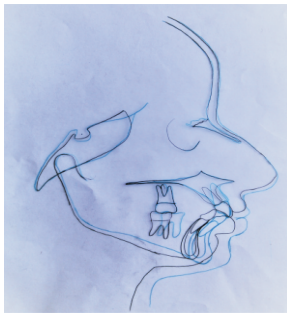

Figure 18 Pre Surgery and Post Surgery Superimposition

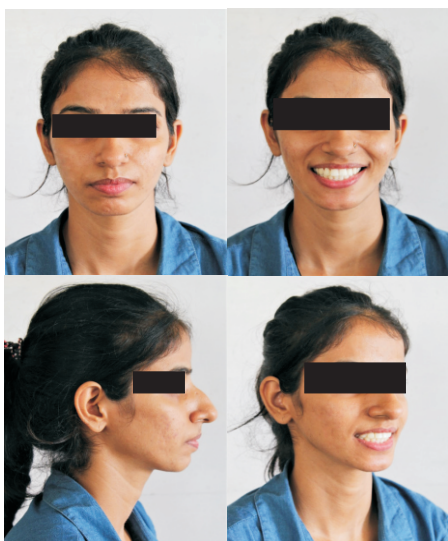

Figure 19 1 year follow up Extra-Oral Photograph

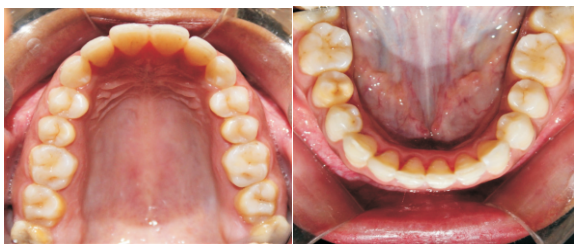

Figure 20 1 year follow up Intra-oral Photographs

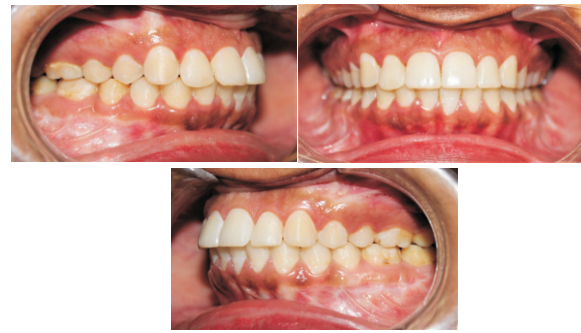

Figure 21 1 year follow up Intra-oral Photographs

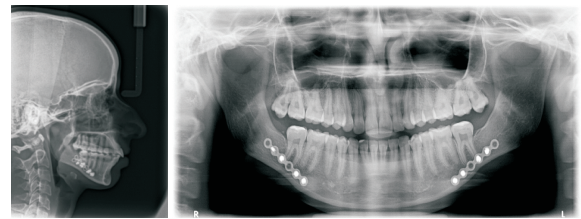


Figure 22 1 year follow up Radiographs

References:

1. Altay Burgaz M, Eraydın F, Diren Esener S, Ülkür E. Patient with Severe Skeletal Class II Malocclusion: Double Jaw Surgery with Multipiece Le Fort I. *Turk J Orthod* 2018; 31: 95-102.
2. Wieslander L, Lagerstrom L. The effect of activator treatment on Class II malocclusions. *Am J Orthod*. 1979; 75:20-6.
3. Daokar, S., Agrawal, G., Chaudhari, C., & Yamyar, S. (2017). Ortho-surgical Management of Severe Skeletal Class II Div 2 Malocclusion in Adult. *Orthodontic Journal of Nepal*, 7(1), 44-50.
4. Burstone CJ, James RB, Legan H, Murphy GA, Norton LA. Cephalometrics for orthognathic surgery. *Journal of Oral Surgery (American Dental Association: 1965)*. 1978 Apr 1;36(4):269-77.
5. Salzmann JA. Malocclusion and treatment need in United States youths 12 to 17 years of age. *Am j Orthod*. 1977;72(5):579-81.
6. Peddu R, Nuvusetty B, Dokku A, Chadawalawada D. Bilateral sagittal split osteotomy: Surgery first approach for correction of skeletal Class II. *J Indian Orthod Soc* 2018;52:133-6.