

Inlay-Retained Aesthetic Fixed Prosthesis Using Monolithic Zirconia: A Case Report.

Abstract:

Various indirect restorations to restore a single missing tooth in the posterior region are available in dentistry such as traditional full coverage fixed dental prostheses, implant-supported crowns, and inlay-retained fixed prosthesis. Resin bonded FDPs represent a minimally invasive procedure; preexisting fillings can minimize tooth structure removal and give retention to the IRFP, transforming it into an ultraconservative option. New high strength zirconia ceramics, with their stiffness and high mechanical properties, could be considered a right choice for an Inlay retained aesthetic fixed prosthesis rehabilitation. The case report describes an IRFP treatment using a CAD/CAM monolithic zirconia. Clinical and laboratory steps are illustrated, according to the most recent scientific protocols. Pleasing esthetic and better functional integration of indirect restoration at six months follow-up confirmed the success of this conservative approach.

Keywords: Indirect restoration, Zirconia, Monolith, Inlay, Direct restoration, Minimal invasive approach.

Introduction:

The availability of new treatments and technologies in dentistry has two consequences: on one side it expands the range of therapies given to patients and on the other hand it stimulates the development of decision-making algorithms for specific medical conditions [1]. Different indirect restorations to replace a single missing tooth in the posterior region are available in dentistry: traditional full-coverage fixed dental prostheses, implant supported crowns, and inlay-retained FDPs [2–4]. The last one is considered a less time and expensive solution compared to the others. Resin bonded FDPs represent a minimally invasive procedure; preexisting fillings can minimize tooth structure removal and give retention to the IRFP, transforming it into an ultraconservative option [4]. In fact, it has been demonstrated that a high amount of coronal dentin is lost during the prosthetic preparation of abutments for conventional full-coverage FDPs with an overall calculated tooth substance removal of 63% to 73% [5]. Historically, cast resin bonded FDPs were produced exclusively using noble metals like high-gold alloys; now a day a wide range of new materials are available: hybrid microfilled or fiber-reinforced composites, ceramics with a

high content of glass particles (i.e., lithium disilicate, glass-infiltrated zirconia, or alumina) or high strength ceramics (densely sintered zirconia/alumina polycrystal) to be used as frameworks for subsequent veneering or to fabricate monolithic restorations [6, 7]. All-ceramic restorations offer an excellent optical behaviour promoting bio-mimetic integration and their surfaces showed minimal plaque accumulation when exposed intraorally [8]. During clinical function, dental restorations are subjected to biting and chewing forces; stress applied during mastication may range between 441 and 981N in the molar region. New high strength

¹AISHWARYA ROY, ²RASHMI BANSAL,
³ABHINAV AGARWAL, ⁴MURITYUNJAY KUMAR

¹Department of Conservative Dentistry and Endodontics, Institute of Dental Sciences,

²Department of Conservative Dentistry and Endodontics, Institute of Dental Sciences, Bareilly

³Department of Conservative Dentistry and Endodontics, Teerthnaker Mahaveer Dental College and Research Center, Moradabad


⁴Department of Anaesthesiology, IQ City Medical College, Durgapur

Address for Correspondence: Dr. Rashmi Bansal
Department of Conservative Dentistry & Endodontics
Institute of Dental Sciences, Pilibhit By Pass Road,
Bareilly
Email: bansalrashmidr@rediffmail.com

Received : 27 May, 2021, **Published :** 31 August, 2021

How to cite this article: Aishwarya Roy, Rashmi Bansal, Abhinav Agarwal, & Murityunjay Kumar. (2021). Inlay-Retained Aesthetic Fixed Prosthesis Using Monolithic Zirconia: A Case Report. UNIVERSITY JOURNAL OF DENTAL SCIENCES, 7(3).

Access this article online

Website: www.ujds.in	Quick Response Code 
DOI: https://doi.org/10.21276/ujds.2021.7.3.17	

ceramics, with their stiffness and high mechanical properties (i.e., resistance to fracture and/or fatigue), could be considered a right choice in an IRFP rehabilitation[9]. New zirconia colour infiltration techniques can improve the colour matching when monolithic restorations were planned [10].

Case Report:

A 38-year-old patient referred to the Department of Conservative Dentistry And Endodontics, Institute of Dental Sciences, Bareilly, Uttar Pradesh with pain and sensitivity in upper left back tooth region since 2 months. Pain was of mild intensity, intermittent in nature and aggravates on chewing. On clinical and radiographic examination, faulty restoration leading to secondary caries was appreciated in relation to 24, 25 and 26. Further exploration with mouth probe revealed overhang amalgam restoration in relation to 24, overhang amalgam restoration leading to root caries in relation to 25 and faulty restoration in relation to 26. On vitality testing with electric pulp tester 24,25 were found non-vital whereas 26 was detected vital. Good oral hygiene, low susceptibility to caries, coronal height over 5 mm suggested for an IRFP rehabilitation, with a minimally invasive approach compared to conventional retained full-coverage FDP (Figure 1). Informed consent was obtained from the patient and the inlay-retained full zirconia fixed prosthesis treatment planning was approved.

Preliminary treatment was started with removal of faulty restoration, excavation of caries and evaluation of remaining sound tooth structure (Figure 2) followed by single sitting root canal treatment in relation to 24 (Figure 3) and extraction in relation to 25 as radiographic evaluation suggested presence of deep root caries which was non-restorable (Figure 2 & 3). The inlay preparations were designed in relation to 26 with rounded proximal boxes and internal edges, smooth round corners, and rectangular-based preparation floors with 2.5mm occlusal reduction, without bevels at occlusal or gingival margins. The isthmus width of the preparation was 3mm for molar abutments. The minimum axial reduction (shoulder with rounded internal angle) was set at 1.5mm and the convergence preparation angle was added up to approximately 6 degrees (Figure 4). The full coverage crown preparation was done in relation to 24 (Figure 4). Prepared

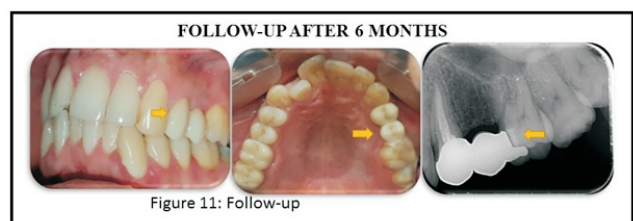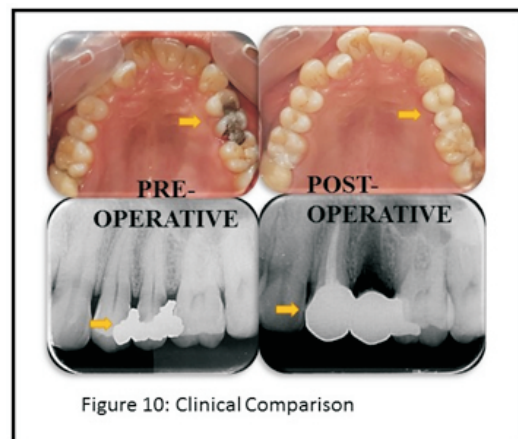
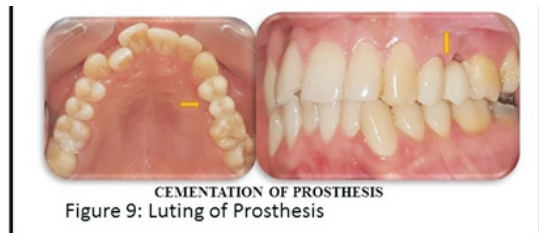
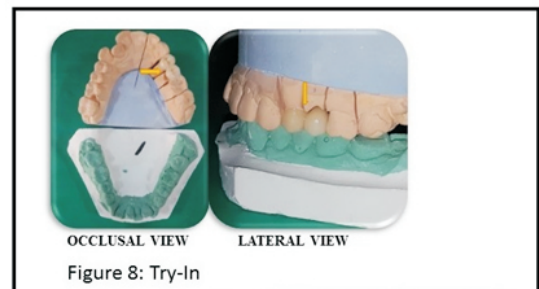
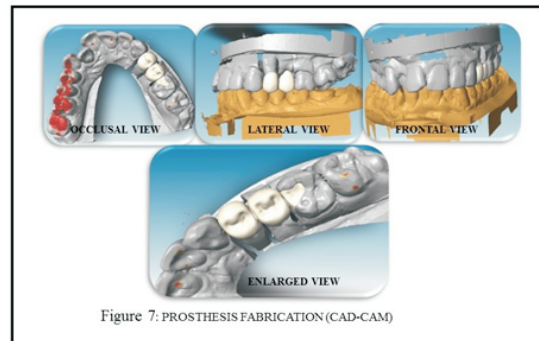
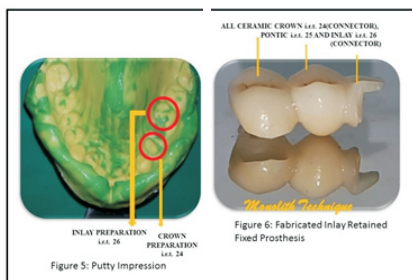
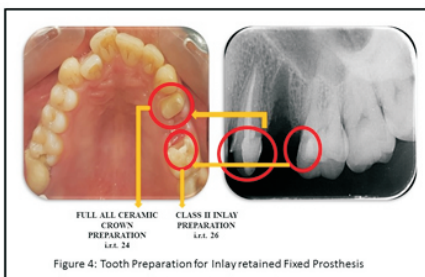
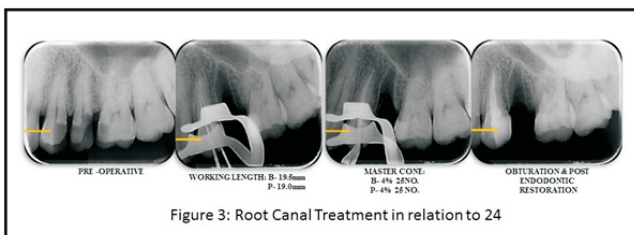
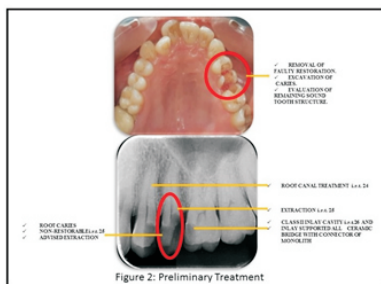
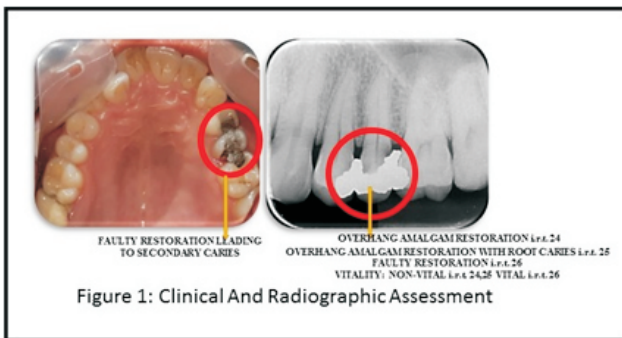
dentin was sealed with an adhesive system to prevent contamination by bacteria and components coming from the impression and provisional cementation materials. The impression was made using a putty material with a one-step technique (Figures 5). Alginate impression of the lower arch and occlusal registration were finally performed. Inlay cavity was then filled with temporary restoration.

Complete fabricated indirect inlay retained fixed prosthesis was obtained from laboratory using monolithic zirconia made with the help of CAD-CAM technique (Figures 6 & 7). Impressions were poured with Type IV gypsum and stone casts were mounted. The fit of the structure was evaluated and try-in was checked on the cast as well as in the oral cavity using a low-viscosity silicone material (Figure 8). The occlusion was checked with a 40 µm occlusal paper, both in maximum inter-cuspitation position and during eccentric movements, making any necessary adjustments with a fine diamond bur.

The temporary restorations were removed using a manual excavator; a rubber dam was placed, isolating the preparations from the oral cavity. Abutments were cleaned using apumice paste over a rotating brush; the cavities were treated with an intraoral sandblaster washed out for one minute, and gently air dried. Enamel and dentin surfaces were etched for 30 s and 15 s, respectively, with 35% phosphoric acid and rinsed for 30 s with air/ water spray. A dual-curing universal dental adhesive was applied to enamel and dentin with a micro-brush for 20 s, evaporated, and left uncured. A self adhesive dual-curing resin cement was dispensed directly into the cavities. The solid zirconia restoration was first placed in site with a finger pressure to complete the seating process, increasing the cement flow. Excess composite resin was carefully removed using a spatula and dental floss. Subsequently a prolonged light curing was performed in all directions for 90 seconds each. Margins were finished and polished with diamond burs, rubber points and diamond polishing paste (Figure 9 & 10).

Pleasing esthetic and better functional integration of the monolithic IRFP confirms the success of the rehabilitation at 10 days (Figures 10). Marginal integrity, absence of chipping and good gingival health status were observed at an interval of

6 months follow up(Figure 11). The patient was also highly satisfied with the selected rehabilitation.



Discussion:

It is generally accepted that partial restorations conserve sound tooth structures and are preferred over complete coverage restorations. In particular, when abutment teeth contain restorative fillings adjacent to the missing tooth, IRFPs are considered a very minimally invasive option. The weakest parts of IRFPs are the connectors and the retainers; in this study a standardized inlay preparation design was used to increase the stability and retention of the densely sintered ceramic restoration [6]. Monolithic high strength ceramic FDPs demonstrated higher in vitro resistance to fracture load than metal ceramic; zirconia based materials used for IRFP also showed greater mechanical behaviour than lithium disilicate glass-ceramic and fiber reinforced composites [10,11].

Conclusion:

Within the limits of a preliminary application, the technique described in this case report allows a minimally invasive approach for single-tooth substitution, as an alternative to a full-coverage FDP or an implant-supported crown.

References:

1. I. Denry and J. R. Kelly, "State of the art of zirconia for dental applications," *Dental Materials*, vol. 24, no. 3, pp. 299–307, 2008.
2. M. Sasse and M. Kern, "CAD/CAM single retainer zirconia ceramic resin-bonded fixed dental prostheses: clinical outcome after 5 years," *International Journal of Computerized Dentistry*, vol. 16, no. 2, pp. 109–118, 2013.
3. D. Augusti, G. Augusti, and D. Re, "Prosthetic restoration in the single-tooth gap: patient preferences and analysis of the WTP index," *Clinical Oral Implants Research*, 2013.
4. C. Monaco, P. Cardelli, M. Bolognesi, R. Scotti, and M. Ozcan, "Inlay-retained zirconia fixed dental prosthesis: clinical and laboratory procedures," *European Journal of Esthetic Dentistry*, vol. 7, no. 1, pp. 48–60, 2012.
5. S. Wolfart, F. Bohlsen, S. M. Wegner, and M. Kern, "A preliminary prospective evaluation of all-ceramic crown-retained and inlay-retained fixed partial dentures," *International Journal of Prosthodontics*, vol. 18, no. 6, pp. 497–505, 2005.
6. F. Beuer, H. Aggstaller, D. Edelhoff, W. Gernet, and J. Sorensen, "Marginal and internal fits of fixed dental prostheses zirconia retainers," *Dental Materials*, vol. 25, no. 1, pp. 94–102, 2009.
6. D. Edelhoff, H. Spiekermann, and M. Yildirim, "Metal-free inlay-retained fixed partial dentures," *Quintessence International*, vol. 32, no. 4, pp. 269–281, 2001.
7. D. Re, G. Pellegrini, P. Francinetti, D. Augusti, and G. Rasperini, "In vivo early plaque formation on zirconia and feldspathic ceramic," *Minerva stomatologica*, vol. 60, no. 7-8, pp. 339–348, 2011.
9. Y. Zhang, J. J. Lee, R. Srikanth, and B. R. Lawn, "Edge chipping and flexural resistance of monolithic ceramics," *Dental Materials*, vol. 29, no. 12, pp. 1201–1208, 2013.
10. S. Rinke and C. Fischer, "Range of indications for translucent zirconia modifications: clinical and technical aspects," *Quintessence International*, vol. 44, no. 8, pp. 557–566, 2013.
11. C. A. Mohsen, "Fracture resistance of three ceramic inlay retained fixed partial denture designs. An in vitro comparative study," *Journal of Prosthodontics*, vol. 19, no. 7, pp. 531–535, 2010.