

Case Management of Ectodermal Dysplasia: A Journey from Agony to Gratification

Abstract:

Ectodermal dysplasia are congenital disorders affecting two or more ectodermal structures. The management can be challenging for pedodontist as each patient represent different amalgamation of deformities. The purpose of this paper is to describe the prosthetic management of 7- year old female with anhidrotic ectodermal dysplasia with the presence of primary molars in both maxillary and mandibular arches and compromised alveolar ridges. The impressions were made with elastomeric impression materials to enhance stability and retention of prosthesis.

Key words: Anhidrotic Ectodermal dysplasia, Congenital disorders, Elastomeric impression

Introduction:

Ectodermal dysplasia(ED) is an umbrella term used to describe a heterogeneous group of genetic disorders characterized by diminution or absence of more than one ectodermally derived anatomical structures. It is a very rare condition occurring in an estimated [1] per 100,000 live births.[2] The diagnostic approach has been described by Virginia P Sybert. Based on the number and functionality of sweat glands, it is classified as hidrotic/ hypohidrotic (christ-siemens-touraine syndrome) or anhidrotic (clouston syndrome) and further subdivision can be made considering the involvement of other ectodermally or non-ectodermally derived structure.[3]

Freire-Maia and Pinheri described 117 varieties of ED with multiple combinations of abnormal ectodermally derived structures.[4] The X-linked hypohidrotic form is the frequently occurring one and is characterized by the classical triad of hypodontia, hypohidrosis, and hypotrichosis.[5]

Management of such patients can be troublesome for the clinician because of plethora of clinical manifestations such as large number of congenitally missing teeth, or even anodontia, atrophied alveolar ridges and also the age when they usually present for rehabilitation.[6]

The main aim of the treatment is to improve the facial appearance, enhance the masticatory efficiency and accelerate the psychological development as well as improved and more rapid social integration of the child in new environment.

Case Report:

A 7 year old female patient presented to the department of Pediatric dentistry, KDCRC, Moradabad, India with the chief complaint of bad appearance due to the absence of front teeth in her oral cavity since 3 years. An initial evaluation of the patient indicated a history of delayed eruption of teeth. There was no history of birth complications, and no other live family member presented similar condition. Physically, she exhibited several of the classical features of ED: hypohidrosis; hypotrichosis; prominent forehead; sparse eyebrows and saddle nose. Intraorally, the alveolar ridges were compromised.

¹SARISH MAHAJAN, ²NAVEEN MANUJA,
³SEEMA CHAUDHARY

¹⁻³Department of Pedodontics and Preventive Dentistry
Kothiwal Dental College and Research Centre, Moradabad

Address for Correspondence: Dr. Sarish Mahajan
MDS,
Pedodontics and Preventive Dentistry
Kothiwal dental college and research centre, Moradabad
Email : Sarishmahajan786@gmail.com

Received : 8 April, 2021 **Published :** 31 August, 2021

How to cite this article: Mahajan, Sarish, Manuja, Naveen, & Chaudhary, Seema. (2021). Case Management of Ectodermal Dysplasia: A journey from agony to gratification. UNIVERSITY JOURNAL OF DENTAL SCIENCES, 7(2):. 74-77


Access this article online	
Website: www.ujds.in	Quick Response Code 
DOI: https://doi.org/10.21276/ujds.2021.7.2.15	

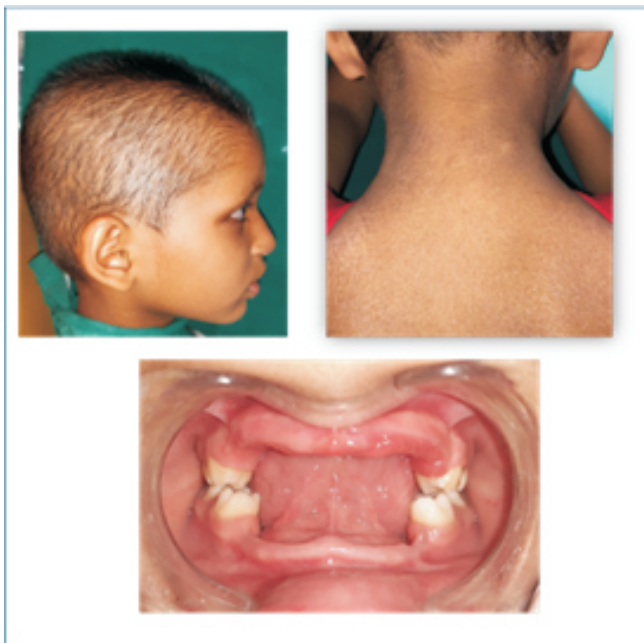

Figure 1: Patient exhibiting classic features of Hypohydrotic Ectodermal Dysplasia

So with the intraoral and extra oral clinical findings regarding the complaint of absence of sweat, a diagnosis of Hypohydrotic Ectodermal Dysplasia was made. The OPG and CBCT revealed Missing teeth 11,12,53,16,21,22,63,26,31, 32,73,36,41,42,83,46 and tooth bud of molars and premolars were seen.

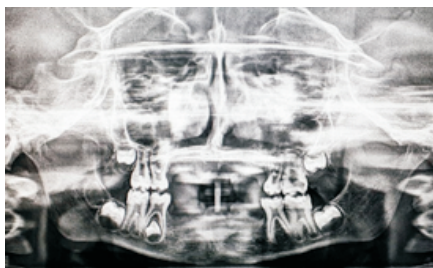


Figure 2: OPG of the patient showing primary molars on both maxillary and mandibular arches

The treatment plan made out was Removable Partial Denture in both maxillary and mandibular anterior region. Primary impressions were taken with alginate. Primary cast were made. Special trays were fabricated for both upper and lower arches. Border moulding was done with medium body elastomeric material. Final impressions were made with light body elastomer and pickup impression was taken with alginate.

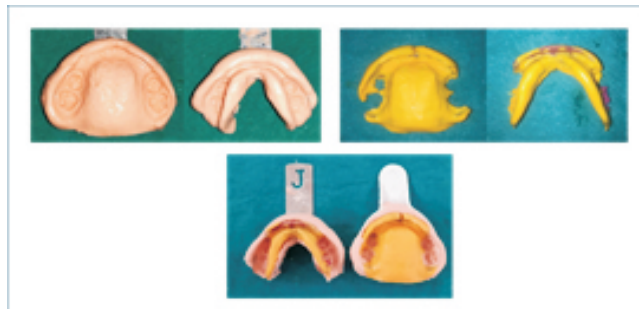

Figure 3: Impression making with elastomeric impression materials.

Wax rims were prepared for the maxillary and mandibular denture base, and proper vertical height was established. A trial denture base was made from auto polymerizing acrylic resin, and the selected denture teeth were adjusted in size and set in wax.

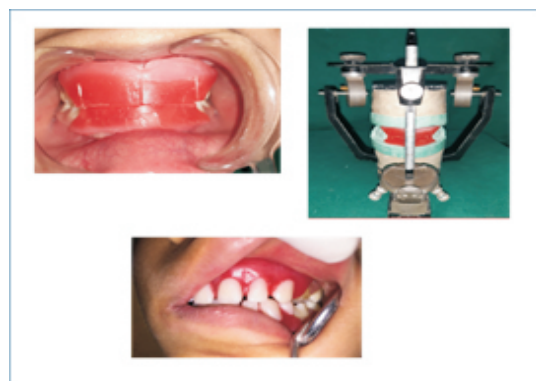


Figure 4: Jaw relations and Try-in

After try-in, the dentures were processed in heat-polymerizing acrylic resin in a usual manner and delivered.

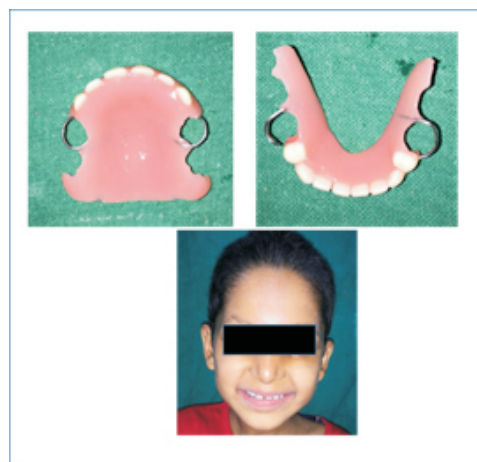

Figure 5: Showing processed denture and Post insertion photograph

The importance of oral and prosthetic hygiene was explained to the patient. The patient is kept on follow-up.

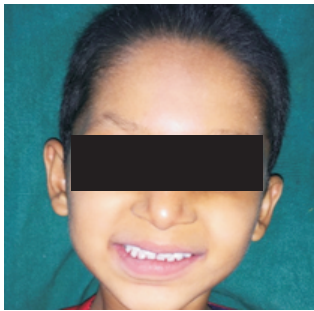

Figure 6: After 1 year follow-up

Discussion :

Hypohidrotic ED/Christ-Siemens-Touraine syndrome is the genetic disorder caused by mutations in the gene ectodysplasin (EDA or EDA1) mapped to Xq12-13.[7] Being an X - linked recessive phenotype, it severely affects males, although females may also display milder symptoms.[8] The clinical manifestations may range from mild to severe forms and include ectodermal structures (skin, hair, nails, teeth, eccrine sweat glands) patient may present oligodontia or even anodontia.[9] Although the cognitive development remains unaffected, the physiognomy may affect their mental state as well as peer integration. Hence various introductory sessions and behavior modification techniques may be required to develop rapport with the patient. Removable partial or complete dentures are the establish treatment modality for young children with missing teeth because of its availability and afford ability.[10] Proper understanding of growth and development is important for pedodontist as continuing changes in maxillofacial skeleton in young ED patients might require prosthesis modification.[11] Thus, periodic recalls and maintenance of oral hygiene is also important. Implants placed after age15 years for girls and 18 years for boys, provided the most predictable prognosis.[12] The impressions of compromised ridges require special considerations towards the fabrication of successful prosthesis. [13] Elastomers offer practitioner a simple method to perform pediatric impressions. They provide ease in manipulation , dimensional stability and excellent patient acceptance.[14] The objectives of prosthetic treatment in young patients with ectodermal dysplasia are bone

preservation, enhance masticatory efficiency, swallowing, speaking and restoring good facial support with improved temporomandibular joint function facilitating development of normal emotional and psychological profile.

Conclusion:

Early diagnosis and prompt treatment are the key to successfully manage the clinical manifestations associated with ectodermal dysplasia as it not only restore the esthetics, phonetics and masticatory functions, but also provides psychosocial rehabilitation.

References:

1. Visinoni ÁF, Lisboa-Costa T, Pagnan NAB, et al. Ectodermal dysplasias: Clinical and molecular review. *Am J Med Genet Part A* 2009; 149: 1980–2002.
2. Manuja N, Passi S, Pandit IK, et al. Management of a case of ectodermal dysplasia: a multidisciplinary approach. *J Dent Child (Chic)* 2011; 78: 107–10.
3. Chokshi K, Chokshi A, Chokshi R, et al. Chokshi A et al.: Ectodermal Dysplasia Ectodermal Dysplasia: A Review. *Int J Oral Heal Med Res* 2015; 2: 101–104.
4. Prashanth S, Deshmukh S. Ectodermal Dysplasia: A Genetic Review. *Int J ClinPediater Dent* 2012; 5: 197–202.
5. Chee S, Wang C, Lin W, et al. Case report Ectodermal dysplasia (ED) syndrome. 2014; 4: 42–43.
6. Teixeira Marques NC, Gurgel CV, Fernandes AP, et al. Prosthetic Rehabilitation in Children: An Alternative Clinical Technique. *Case Rep Dent* 2013; 2013: 1–5.
7. Clarke A, Phillips DIM, Brown R, et al. Clinical aspects of X-linked hypohidrotic ectodermal dysplasia. *Arch Dis Child* 1987; 62: 989–996.
8. Gupta S, Tyagi P. Prosthodontic management of anhidrotic ectodermal dysplasia. *Indian J Dent Res* 2011; 22: 348–351.
9. Minocha N, Chatterjee R, Shrikhande D. Ectodermal dysplasia, anhidrotic. *PravaraMed Rev* 2012; 4: 22–23.
10. Bajpai M, Agarwal D, Lavania A, et al. Prosthodontic treatment strategy for patients with ectodermal dysplasia: A literature review. *SRM J Res Dent Sci* 2014; 5: 46.
11. Alcan T, Basa S, Kargül B. Growth analysis of a patient with ectodermal dysplasia treated with endosseous

- implants: 6-Year follow-up: Case report. *J Oral Rehabil* 2006; 33: 175–182.
12. Arun T, Arangannal P, Jeevarathan J, et al. Dental implants in pediatric dentistry: A review. *Eur J Mol Clin Med* 2020; 7: 6497–6501.
 13. Tanvir H, Kumar N, Singh K, et al. An Innovative Wire Impression Technique of Highly Resorbed Mandibular Ridge. *Periodontics Prosthodont* 2017; 03: 1–3.
 14. Smith DE, Toolson LB, Bolender CL, et al. One-step border molding of complete denture impressions using a polyether impression material. *J Prosthet Dent* 1979; 41: 347–351.