

Imaging approach to find Osteoporosis in Post-Menopausal Females in Urban & Rural Areas

ABSTRACT:

Background: The number of women with osteoporosis i.e. with reduced bone mass and disruption of bone architecture is gradually increasing in the Indian subcontinent and has been reported throughout the country. This condition majorly affects the post-menopausal females and very often remains undiagnosed leading to various complications later. This study was therefore planned to ascertain the role of panoramic radiographs as a screening tool for osteoporosis using radio morphometric indices in postmenopausal women.

Materials and Methods: The study comprised of a study group of 60 post-menopausal women, divided into 2 sub-groups (Urban & Rural), each comprising of 30 individuals, depending on their occupation and domicile. The panoramic radiographs of all the study subjects were recorded for evaluation of 3 radiomorphometric indices viz. Mandibular Cortical Index (MCI), Mental Index (MI) & Panoramic Mandibular Index (PMI).

Result: Statistical analysis revealed higher significant values for all the radiomorphometric indices in rural than in urban postmenopausal woman.

Conclusion: The study suggests that panoramic radiograph can be used as an effective screening tool for osteoporosis using various radiomorphometric indices.

Keywords: Bone Mineral Density, Osteoporosis, Panoramic Radiograph, Mandibular Cortical Index, Mental Index, Panoramic Mandibular Index

Introduction:

Osteoporosis is defined as “a progressive systemic skeletal disorder characterized by consequent increase in bone fragility and susceptibility to fracture”. Osteoporosis has a tremendous impact on the lives of many post menopausal women[1].the major risk factors for osteoporosis include smoking, alcohol consumption , physical inactivity , genetics, low calcium intake. The hormonal changes that accompany menopause are the most cause of decrease in bone mass in woman[2]. Osteoporosis, which is characterized by compromised bone strength, is frequently not detected until a fracture occurs. It is considered to be a silent disease that entails significant social and economic burden. The risk factors for the development of osteoporosis include ageing, menopause, reduced dietary intake of calcium and decreased physical activity. Currently osteoporosis is considered to be a serious public health concern for elderly populations, and postmenopausal women still represent the highest fracture risk group[3]. Bone density (or bone mineral density) is a medical term normally referring to the amount of mineral matter per square centimetre of bones. Bone mineral density (BMD) is used in medicine is an indirect indicator of osteoporosis and fracture risk[4]

Osteoporosis results in reduced jaw bone mass, as well as alterations of the mandibular structure, especially of the inferior border. The gold standard procedure for assessment of bone mineral density is the dual energy x-ray absorptiometry (dxa). However, such a scan is impossible to use in all situations due to limitations of availability and economy[5].

¹SABA NASREEN ²SHUBHAM KUMAR ³PRAMOD YADAV ⁴RAUNAQUE SABA ⁵DEVLEENA BHOWMICK ⁶HAIDER IQBAL

^{1,2}Dept. of Dentistry, Sri Krishna Medical College & Hospital, Muzaffarpur, Bihar

³Department of Periodontics and Community Dentistry, Dr Z.A.Dental College AMU, Aligarh, UP, India


⁴Dept. of Dentistry, Jawahar Lal Nehru Medical College & Hospital, Bhagalpur, Bihar

⁵Dept. of Oral Medicine & Radiology, PDM Dental College & Research Institute, Bahadurgarh, Jhajjar, Haryana

⁶Dept. of Oral Medicine & Radiology, Sardar Patel Post Graduate Institute of Dental & Medical Sciences, Lucknow,

Address for Correspondence : Dr. Shubham Kumar
BDS, MDS (Periodontics) Senior Resident,
Department of Dentistry, Sri Krishna Medical College
Hospital, Muzaffarpur, Bihar

Received : 18 Dec. 2020, **Published :** 30 April 2020

Access this article online	
Website: www.ujds.in	Quick Response Code 
DOI: 10.21276/ujds.2021.7.1.6	

How to cite this article: Saba Nasreen, Shubham Kumar, Pramod Yadav, Raunaque Saba, Devleena Bhowmick, Haider Iqbal., Imaging approach to find Osteoporosis in Post-Menopausal Females in Urban & Rural Areas. UNIVERSITY JOURNAL OF DENTAL SCIENCES, 7(1) 29-34

Panoramic radiographs are routinely used in dental practice for the diagnosis of dental pathologies. Qualitative and quantitative indices such as Mandibular Cortical Index [MCI], Mental Index [MI], & Panoramic Mandibular Index [PMI] have been used in panoramic radiographs to assess alveolar bone quality and to observe signs of resorption and osteoporosis. Cortical height on radiographs and mineral density seems to follow a similar pattern as seen in general mineral status of skeleton[6]. The occurrence of osteoporosis in postmenopausal women is very common problem especially in Indian who are exposed to many of the risk factors like family history of osteoporosis, low calcium diet, vitamin d deficiency, history of anorexia. The pathogenesis of postmenopausal osteoporosis involves the interplay of many factors like nutritional, environmental and genetic factors. Ideally biomarkers should be available that assess fragility fracture risk with high accuracy. The limitations of bone mass/density measurements in these two fields have driven the development of novel imaging biomarkers focusing on bone quality. In addition to these quantitative techniques dedicated to bone mass and quality assessment, standard imaging techniques need be used to diagnose prevalent osteoporotic fractures, as this will affect therapy recommendations and may prevent future fractures. Correctly diagnosing and interpreting fragility fractures with all available imaging modalities is one of the major responsibilities we have as oral physicians and oral radiologists[7]. Hence the study was planned to estimate and to evaluate alveolar bone mass using various radiomorphometric indices.

Material and Methods:

This observational study was conducted by the Department of Dentistry, Sri Krishna Medical College & Hospital, Muzaffarpur, Bihar. Dentulous post-menopausal women in good general health, not suffering from any systemic disorder or condition willing to participate in the study were included. Edentulous/Partially dentulous patients taking hormone replacement therapy and patients suffering from diseases (Paget's Disease, Parathyroid dysfunction etc) or taking drugs (Vitamin D, lithium, thiazide diuretics, thyroxine etc) likely to affect calcium metabolism were excluded from the study.

A total of 60 post-menopausal female patients from the outpatient department were selected for the study. The selected sample was divided into 2 groups, each consisting of 30 individuals, depending on their occupation and domicile:

- Group 1 - Urban Postmenopausal Women
- Group 2 - Rural Postmenopausal Women

A detailed history was obtained for bone pain and weakness, and thorough screening examination was performed for proximal muscle weakness (difficulty in climbing stairs, inability to rise from squatting position). History of bone

tenderness for each subject included menstrual history (also including years since menopause).

Digital panoramic radiographs were recorded for all the study subjects from a single machine by a single operator using standard specifications for patient positioning which involves positioning the mid-sagittal plane laser beam for a central alignment, the Frankfort plane positioning laser beam for a Frankfort plane alignment, the canine plane positioning laser for a canine alignment. The exposure parameters included total exposure time: 13.89 seconds, magnification factor: 1.27 ($\pm 10\%$), default KVP factor: 75 MV and current: 10 MA.

All the digital panoramic radiographs were viewed on a flat viewing box under dim lighting. The landmarks were traced on a 36-matte acetate tracing sheet. Measurement of each index was made bilaterally on both sides. One qualitative index namely Mandibular Cortical Index [MCI] and two quantitative indices viz. Mental Index [MI] and Panoramic Mandibular Index [PMI] were measured.

1. Mandibular Cortical Index (MCI): MCI refers to the inferior mandibular cortical thickness and is categorized into three groups according to the criteria described by Klemetti et al. [8]. The index was used to assess the appearance of inferior cortex of mandible. The inferior cortex of mandible is classified as:

C1: the endosteal margin of the cortex is even and sharp [Figure 1a]

C2: the endosteal margin presents semilunar defects (lacunar resorption) or appears to form endosteal cortical residues [Figure 1b]

C3: the cortical layer forms heavy cortical residues and is clearly porous [Figure 1c].

2. Mental Index (MI): This index was used to measure cortical width at the mental foramen region and is assessed according to the technique described by Ledgerton et al. [9]. Accordingly, the mental foramen was identified and a line was traced that passed perpendicular to the tangent of the lower border of the mandible and through the center of the mental foramen bilaterally and an average was taken as a final measurement. The cortical width was measured at this point. [Figure 2].

3. Panoramic Mandibular Index (PMI): PMI as described by Benson et al. [10] is the ratio of the thickness of mandibular cortex to the distance between the mental foramen and the inferior mandibular cortex. Two measurements were made: one from the superior border of mental foramen to the inferior border of mandible, and the other from the inferior border of the mental foramen to the inferior border of mandible and an average was taken as the final measurement (h) [Figure 3]. The ratio was measured using this final bilateral value.

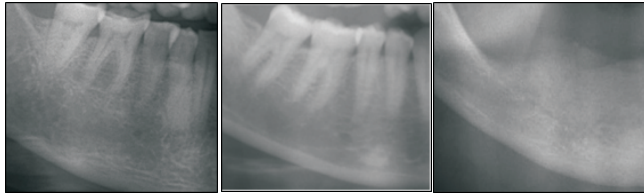


Figure 1: Radiographs depicting qualitative MCI. 1a: C1 category, 1b: C2 category, 1c: C3 category

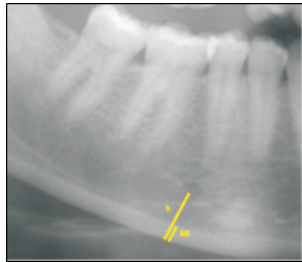


Figure 2: Calculation of MI

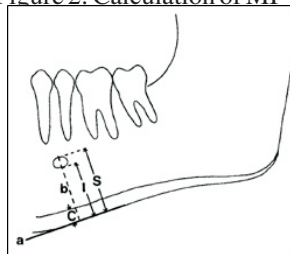


Figure 3: Calculation of PMI

Data was analyzed using SPSS version 20 (SPSS Inc., Chicago, IL). Unpaired t-test was used to ascertain the significance of differences between mean values of two continuous variables. Chi-square test was performed to test for differences in proportions of categorical variables between two or more groups. The level $P < 0.05$ was considered statistically significant.

Result:

The mean value of Panoramic Mandibular Index (PMI) in Group-1 was 0.24 and that for Group-2 patients was 0.32. Comparison was done by using unpaired t test. It was found to be highly significant and t value was found to be 6.00 and p value < 0.001 (Table-1).

Table 1: Comparison of {Mean (SD)}of (PMI) among both the groups using unpaired t test.

	No of participants	Mean (SD)
Group-1	30	0.24 (0.1)
Group-2	30	0.32 (0.1)
t value	-	6.000
P value	-	<0.001**

($p < 0.05$ - Significant*, $p < 0.001$ - Highly significant**)

The mean value of Mental Index (MI) in Group-1 was 2.88 and that for Group-2 was 3.82. Comparison was done by using unpaired t test. It was found to be highly significant and t value was found to be 6.417 and p value < 0.001 [Table-2].

Table 2: Comparison of {Mean (SD)}of (MI) among both the groups using unpaired t test.

	No of participants	Mean (SD)
Group-1	30	2.88 (0.6)
Group-2	30	3.82 (0.5)
t value	-	6.417
P value	-	<0.001**

($p < 0.05$ - Significant*, $p < 0.001$ - Highly significant**)

The assessment of Mandibular Cortical Index (MCI) revealed that amongst the urban study subjects (Group-1), out of 30 subjects none (0.0%) subjects in the C1 category, 12 (40.0%) subjects were in C2 category and 18 (60.0%) subjects in the C3 category. Amongst the rural study subjects (Group-2), out of 30 subjects 14 (46.7%) subjects were in the C1 category, 13 (43.3%) subjects in the C2 category, and 3 (10%) subjects to the C3 category. The comparison was done by chi square test and highly significant difference was found between their indices $p < 0.001$ [Table 3].

Table 3: Cross tabulation of both the groups with lower border cortex of the mandible as viewed on panoramic radiographs

		CI			Total	
		C1	C2	C3		
Group	Urban	Count	0	12	18	30
		% within Group	0.0%	40.0%	60.0%	100.0%
Group	Rural	Count	14	13	3	30
		% within Group	46.7%	43.3%	10.0%	100.0%
Total		Count	14	25	21	60
		% within Group	23.3%	41.7%	35.0%	100.0%
		Chi square value: 24.754	p value: <0.001**			

($p < 0.05$ - Significant*, $p < 0.001$ - Highly significant**)

Based on the above statistical results, the sensitivity and specificity of the significant indices was determined and Receiver Operator Curve (ROC) was plotted to determine the cut off value for each of these indices {co-ordinates of ROC-PMI and ROC-MI}. The sensitivity and specificity of Panoramic Mandibular Index was 90% and 100% respectively at PMI value of 0.176 and the p value was 0.000 (Chart 1, Table 4).

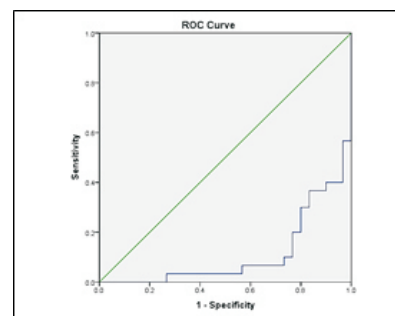


Chart 1: Sensitivity & Specificity Analysis PMI

Area Under the Curve				
Test Result Variable(s): PMI				
Area	Std. Error ^a	Asymptotic Sig. ^b	Asymptotic 95% Confidence Interval	
			Lower Bound	Upper Bound
.111	.041	.000	.030	.192

Table 4: Table showing confidence Interval for PMI

For the Mental Index, the sensitivity and specificity values are 90% and 100% respectively at a MI value of 2.025 and p value was 0.00 (Table 5, Chart 2).

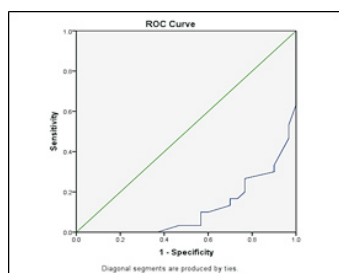


Chart 2: Sensitivity & Specificity Analysis MI

Area Under the Curve				
Test Result Variable(s): MI				
Area	Std. Error ^a	Asymptotic Sig. ^b	Asymptotic 95% Confidence Interval	
			Lower Bound	Upper Bound
.116	.041	.000	.035	.196

Table 5: Table showing confidence Interval for MI

Discussion:

The term osteoporosis is derived from classical greek word “osteon” meaning bone and “pores” meaning a small passage or pore, and osis meaning condition. According to the definition of the World Health Organization (WHO), osteoporosis is a systemic disease characterized by low bone mineral density (BMD), deterioration of bone structure and increased bone fragility[11]. In India 1 out of 8 males and 1 out of 3 females suffer from osteoporosis, making India one of the largest affected country of the world[12]. To detect early signs of osteoporosis and to select those women who can benefit most from therapy would require bone mineral density testing of all post-menopausal women at risk[13].

Because many women are involved this would require extensive facilities and high costs. Moreover, this would again require the time of both the women and the medical personnel. Therefore, there is a need for less expensive alternative methods of assessing the skeletal status that can be used on a large scale. Dental radiographs are relatively inexpensive and has already been in use among a large part of the adult population. Because osteoporosis is a systemic disease involving all skeletal bones and because dental radiographs always depict some mandibular or maxillary bone, dental radiograph may offer an opportunity for a screening tool for osteoporosis[14].

Panoramic radiography has been an important component of dental diagnostic radiology for over 40 years. It is a technique that produces an image of the teeth and jaws on a single film. Nowadays there is a great tendency among researchers to use panoramic radiograph for detecting calcification of the branches of the external carotid artery and osteoporosis.[8] Various methods have been used to assess bone density. These include single photon absorptiometry, dual photon absorptiometry, dual energy x-ray absorptiometry and quantitative computed tomography. All these techniques use ionizing radiations to measure bone mineral density (bmd). quantitative ultrasound uses sound waves rather than ionizing radiation to assess properties of bone that are. Related to density and bone strength and it is noninvasive. The gold standard for the assessment of bone mineral density is dual energy x-ray absorptiometry[9].

The aim of the present study was to assess alveolar bone mass using radiomorphometric indices in urban and rural postmenopausal women. In the present study three radiomorphometric indices were measured viz. PMI, MI and MCI. The study revealed that the mean values of PMI decrease as the age of the subject increases and within groups the highest mean value [0.32] was observed in group-2 and the lowest value in group-1 [0.24], also a highly statistically significant difference among both these groups were noted. These results were similar to those carried out by C S Valerio et al. (2013) wherein the morphology of the mandibular cortex was evaluated using the mandibular cortical index (MCI) and the inferior mandibular cortex width was evaluated using the mental index (MI) in 64 female patients who had undergone dual energy x-ray absorptiometry assessment, and the authors concluded that there were significant differences between the normal and lower bone mineral density groups (osteopenia and osteoporosis) for MCI(p<0.01)[15].

In the present study, when visual estimation of the width of the mandibular cortex was assessed, the following results were amongst the subjects with urban and rural postmenopausal woman. In urban postmenopausal women out of 30 subjects no (0.0%) subject showed a maximum thickness C1 of the mandibular cortex, 12 (40%) subjects had C2 intermediate mandibular cortical thickness and 18 (60%) subjects C3 showed thin mandibular cortical thickness and in the rural postmenopausal women out of 30 subjects, 14 (46.7%) had maximum mandibular cortical thickness C1, 13 (43.3%) subjects had intermediate mandibular cortical thickness C2 and 3 (10%) subjects had thin mandibular cortical thickness C3.

In the present study, there was a highly statistically significant correlation between visual estimation of the width of the mandibular cortex and the BMD. This result was identical to a research which documented that the bone mineral density determined at different sites was significantly lower in patients with thinning and resorption of mandibular cortex identified by the visual estimation of the width of the mandibular cortex. ($p < 0.05$)[16]. A study to evaluate the significance of panoramic radiomorphometric indices (Mandibular Cortical Index [MCI], Mental Index [MI] and Panoramic Mandibular Index [PMI]) as useful tools for identifying osteoporosis was done by mansour et al. (2013) which concluded that panoramic indices (mi, pmi, and mci) were positively correlated with the t-score and BMD of the lumbar spine and the MCI was found to be the most reproducible index[17].

Similar results are evident from the present study which emphasizes the alveolar bone mass loss identified by all the three indices (i.e) PMI, MI, MCI with a statistical significant difference. Klemetti had first proposed the mandibular cortical index. He suggested that a thin or eroded inferior cortex of the mandible detected on dental panoramic radiographs, an indicator of alterations of the mandible, is useful for identifying postmenopausal women with undetected low skeletal BMD or osteoporosis[6]. In the present study when the MCI was evaluated, it was found that C1 category was highest in Group 2 (postmenopausal women of rural region) followed by a highly statistically significant difference among the two groups urban and rural postmenopausal woman [p value < 0.001].

These are identical to the results of a study by Taguchi et al. (2008), in which the authors evaluated the detection of an eroded mandibular cortex on panoramic radiographs and questionnaire-based screening tools as diagnostic efficacies

for identifying osteoporosis in post-menopausal women and they concluded that panoramic radiography is superior to questionnaire-based screening for identifying women who are at high risk of fracture[18]. Renvert et al. (2011) evaluated the mandibular cortex in the panoramic radiographs of 778 individuals (53% women) in the age of 59-96 years. The researchers observed the endosteal margin of the mandibular cortical bone, if presented in full or image, showed lacunar resorption and related to bmd previously assessed by dxa. The results were significant, with relationship between low bmd and lacunar resorption in mandibular cortical bone[19].

The present study showed significant correlation between MCI and BMD and demonstrated that none of the patients with osteoporosis was classified as C1 and there was a prevalence of C3 (60%) in Group 1.

MI (mental index) is measurement of the cortical width at the mental foramen region, as described by et al[20]. A study done by Egle Jagelavince et al. (2016), evaluating the relationship between panoramic radiomorphometric indices of the mandible and calcaneus [heel bone] bone mineral density in postmenopausal women revealed that a statistically significant correlation was found between the mental index and bone mineral density in the [21]. ($r = 0.356$, $p < 0.001$) and between the panoramic mandibular index and bone mineral density in the calcaneus ($r = 0.397$, $p < 0.001$)21. These findings are similar to present study in which MI and PMI measured alveolar bone loss to be highly statistically significant in both the groups.

Conclusion:

This study shows that panoramic radiography could be used as a screening tool for detection of osteoporosis by using various radiomorphometric indices and could also be used to assess the sensitivity and specificity of the individual panoramic radiomorphometric indices in the screening of osteoporosis. Further studies involving larger sample size with inclusion of direct estimation of serum Vitamin-D3 levels among post-menopausal women in rural and urban areas along with information on daily sun exposure could further validate the findings of this study.

References:

1. Nasreen S , Ramesh DNSV, Thriveni R, Bayatnal A, Chowdhury RM, Kattimani S, et al. Assessment of alveolar bone mass using radio morphometric indices in urban and rural postmenopausal women and their correlation with serum vitamin D3 level. Indian J Dent Res 2019;30:722-30.

2. Khojastehpour L, Mogharrabi S, Dabbaghmanesh MH, Iraj Nasrabadi N. Comparison of the mandibular bone densitometry measurement between normal, osteopenic and osteoporotic postmenopausal women. *J Dent (Tehran)*. 2013;10(3):203-9.
3. Leite AF, Figueiredo PT, Guia CM, Melo NS, de Paula AP. Correlations between seven panoramic radiomorphometric indices and bone mineral density in post menopausal women. *Oral Surg Oral Med Oral Pathol Oral Radiol Endod* 2010; 109(3):449
4. McCormick RK .Osteoporosis: integrating biomarkers and other diagnostic correlates into the management of bone fragility. *Altern Med Rev* 2007; 12:113–145.
5. Ramesh A, Mahajan K, Thomas B, Shenoy N, Bhandary R. Alveolar bone mass in pre- and postmenopausal women with serum calcium as a marker: a comparative study. *Indian J Dent Res*. 2011;22(6):878.
6. Sadat-Ali M, Al Elq AH, Al-Turki HA, Al-Mulhim FA, Al-Ali AK. Influence of vitamin D levels on bone mineral density and osteoporosis. *Ann Saudi Med*. 2011;31(6):602-608.
7. Link TM. Osteoporosis imaging: state of the art and advanced imaging. *Radiology*. 2012;263(1):3-17.
8. Alapati S, Reddy RS, Tatapudi R, Kotha R, Bodu NK, Chennouju S. Identifying risk groups for osteoporosis by digital panoramic radiography. *Contemp Clin Dent*. 2015;6(Suppl 1):S253-S257.
9. Njeh CF, Genant HK. Bone loss. Quantitative imaging techniques for assessing bone mass in rheumatoid arthritis. *Arthritis Res*. 2000;2(6):446-450.
10. Barclay L. Guidelines issued for screening men for osteoporosis. *Ann Intern Med* 2008;148:680-4.
11. Vijay G, Chitroda PK, Katti G, Shahbaz S, Baba I, Bhuvaneshwari. Prediction of osteoporosis using dental radiographs and age in females. *J Midlife Health*. 2015;6(2):70-75.
12. Nikose S, Singh P, Khan S, Arora M, Taywade S, Gudhe M et al. Prevalence of Osteoporosis in Female Population in Rural Central India [By Calcaneal Ultrasound]. *J Women's Health Care* 2015;4: 262.
13. Osteoporosis: review of the evidence for prevention, diagnosis and treatment and cost-effectiveness analysis. Executive summary. *Osteoporos Int*. 1998;8 Suppl 4:S3-6.
14. Verheij JG, Geraets WG, van der Stelt PF, Horner K, Lindh C, Nicopoulou-Karayianni K, Jacobs R et al. Prediction of osteoporosis with dental radiographs and age. *Dentomaxillofac Radiol*. 2009;38(7):431-7.
15. Valerio CS, Trindade AM, Mazzeiro ET, Amaral TP, Manzi FR. Use of digital panoramic radiography as an auxiliary means of low bone mineral density detection in post-menopausal women. *Dentomaxillofac Radiol*. 2013;42(10):20120059.
16. Jin H, Ralston SH. Genetics of Osteoporosis. *Curr Rheumatol Rep* 2005; 7: 66-70.
17. Horner K, Devlin H, Alsop CW, Hodgkinson IM, Adams JE. Mandibular bone mineral density as a predictor of skeletal Osteoporosis. *Br J Radiol* 1996; 69: 1019-1025.
18. Taguchi A, Ohtsuka M, Nakamoto T, Naito K, Tsuda M, Kudo Y, et al. Identification of post-menopausal women at risk of osteoporosis by trained general dental practitioners using panoramic radiographs. *Dentomaxillofac Radiol*. 2007;36:149–54.
19. Renvert S, Berglund J, Persson RE, Persson GR. Osteoporosis and periodontitis in older subjects participating in the Swedish National Survey on Aging and Care (SNAC-Blekinge). *Acta Odontol Scand* 2011;69:201-7.
20. Ledgerton D, Horner K, Devlin H, Worthington H. Panoramic mandibular index as a radiomorphometric tool: An assessment of precision. *Dentomaxillofac Radiol* 1997;26:95-100.
21. Jagelaviciene E, Kubilius R, Krasauskiene A. The relationship between panoramic radiomorphometric indices of the mandible and calcaneus bone mineral density. *Medicina (Kaunas)*. 2010;46(2):95-103.