

Excision of Lower Lip Mucocele Using Scalpel and Diode Laser: Two Case Reports

Abstract:

The term "Mucocele" originates from Latin words 'mucus' which means 'fluid' and 'coele' which means 'cavity'. It is defined as the accumulation of mucus in the oral cavity's subepithelial tissue secreted from salivary glands and their ducts. It is a frequently occurring salivary gland lesion which is seen in the oral cavity. They occur as mucus extravasation and mucus retention type. They may be obstructive in nature and occur due to trauma to a minor salivary gland duct which results in pooling in the epithelial tissue. Clinically, a mucocele appears as a typical blue colored dome shaped swelling which is soft in consistency and contains salivary fluid. It lies superficial or deeply attached to the tissues.

Management of mucocele includes surgical excision, marsupialization, micro marsupialization, cryosurgery, laser vaporization, and laser excision. Recently, high - intensity lasers have been proven to be more beneficial than conventional surgery as it causes prompt hemostasis, minimal blood loss and reduced healing time of the site.

Keywords: Soft Tissue Laser; Mucocele; Lower Lip; Surgical Excision; Recurrence; Minor Salivary Gland

Introduction

Mucoceles (derived from latin words 'mucus' means 'fluid' and 'coele' means 'cavity') are defined as mucus-filled cavities that can appear in the oral cavity, appendix, gallbladder, paranasal sinuses or lacrimal sac. [1] It is the most common minor salivary gland disorder and the second most frequent benign soft-tissue tumors.[2] Mucoceles are divided into retention mucocele and extravasation mucocele. They may be obstructive in nature and occur due to trauma to a minor salivary gland duct. Clinically, a mucocele appears as a typical blue colored dome shaped swelling which is soft in consistency and contains salivary fluid. It lies superficial or deeply attached to the tissues. They are painless, unless ulcerated due to trauma and have a tendency to return back once treated. [2]

Treatment options include medication (gamma-linolenic acid), cryosurgery, intralesional corticosteroid injection, micro-marsupialization, conventional surgical removal of the lesion and laser ablation. Conventional surgical removal is the most common method used to treat mucocele by extirpating the surrounding mucosa and glandular tissue. Currently, laser assisted excision is reported in various literatures for its advantages over the conventional one such as: bloodless field- for better visualization, no

need for suture placement and lesser chances of recurrence. [3] It is also reported that the patterns of healing and epithelialization were early with laser than surgical excision.

This case series aimed to evaluate and compare the potential of laser excision over surgical approach for treating mucocele.

Case Report 1

A 09 year old female patient reported to the Department of Pedodontics and Preventive Dentistry, with a chief complaint of painless swelling on the left side of lower lip since last one month. The swelling was small initially and had gradually increased to the present size. The patient gave history of lip biting. The medical and family history was not relevant.

¹MD AJMAL, ²ROLI DUREHA, ³SULEMAN A KHAN, ⁴SAUMYA NAVIT,
1,2,3,4,Department of Pediatric and Preventive Dentistry, Saraswati Dental college; Lucknow

Address for Correspondence : Dr. Md Ajmal
Flat No. 103, 45 Waqas Tower, Sec 10 Indira Nagar, Lucknow
Email: mdajmal1990@gmail.com

Received : 123 Feb. 2021, **Published :** 30 April 2021

How to cite this article: Md Ajmal, Roli Dureha, Suleman A Khan, Saumya Navit, (2021). Excision of Lower Lip Mucocele Using Scalpel and Diode Laser: Two Case Reports. UNIVERSITY JOURNAL OF DENTAL SCIENCES, 7(1).

Access this article online	
Website: www.ujds.in	Quick Response Code 
DOI: https://doi.org/10.21276/ujds.2021.7.1.20	

On intraoral examination solitary and round swelling of approximately 01 cm diameter was seen over the left lower labial mucosa extending from inner border of the vermilion border to 3-4 mm above labial vestibule at the tubercle of lower lip. (Fig. 1) The color of the lesion was the same as the adjacent mucosa. Swelling was non tender and fluctuation test was positive.

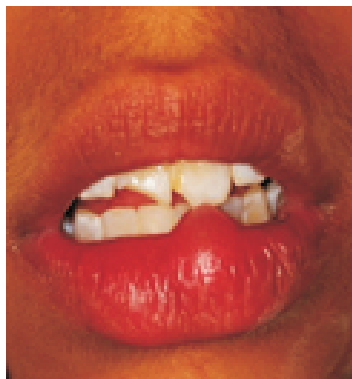

Fig. 1- Swelling on the left labial mucosa region

On the basis of history and clinical examination, a provisional diagnosis of mucocele was made whereas the differential diagnoses were oral lymphangioma, oral hemangioma, lipoma and a soft tissue ulcer.

Various treatment modalities such as surgical excision, cauterization, and laser excision were explained to the patient's parent. They opted for surgical excision because of affordability. The treatment procedure was explained and informed consent was taken. Routine blood investigations were done.

Before start of procedure, lesion and surrounding areas was sterilized with betadine solution. Local infiltration was administered around lesion using 2% lignocaine with 1:10000 epinephrine (NEON Laboratories, Mumbai, India). Superficial incision was placed with the help of bard parker blade no. 15 over the lesion involving the superficial layers. Then tissue was separated on either side with the help of blunt pointed mosquito forceps and the lesion was excised [Fig.-2,3]. Minor salivary glands around the lesion were also excised to prevent recurrence. Suturing was done using 3-0 vicryl suture. The excised tissue was sent for the histopathological analysis for the confirmation of the diagnosis of the mucocele. Histopathological examination showed thick fibrous capsule lined the cystic cavity and mucin, foamy macrophages and chronic inflammatory cells contained by cystic lumen. With all this histopathological confirmation final diagnosis of mucous extravasation cyst was made. Analgesic and antibiotic was prescribed for 5 days and post-operative instructions was given to the patient for maintaining the suture site, taking soft diet and maintenance of oral hygiene. Suture was removed after 1 week and healing was uneventful. Patient was again recalled after 2 months, there was no sign of recurrence of mucocele [Fig.-3].

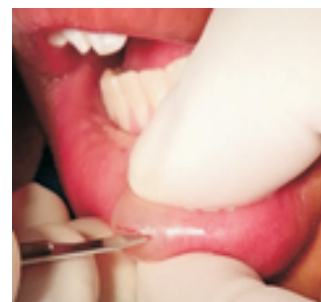


Fig.2- Intra-operative

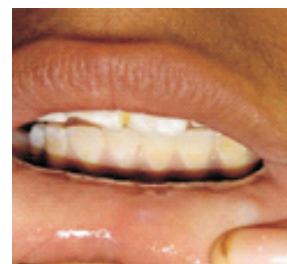

Fig.3- Post-operative after 6 weeks

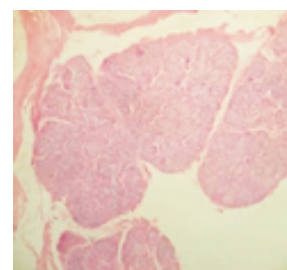


Fig.4- Histopathological aspect of mucocele

Case Report 2

A 14 year old male patient reported to the Department of Pedodontics and Preventive Dentistry, with a chief complaint of painless swelling on the left side of lower lip since last two months. The patient gave history of trauma 4 month back. The medical and family history was not relevant

On intraoral examination painless, raised, well circumscribed, semitranslucent, confined lesion of 1.2x0.7x0.6 cm was seen, located on right lower labial mucosa extending from inner border of the vermilion border till 2-3 mm above labial vestibule at the tubercle of the lower lip the patient's right side of lower lip.

On the basis of history and clinical examination provisional diagnosis of mucocele was made whereas the differential diagnoses were oral lymphangioma, oral hemangioma, lipoma and a soft tissue ulcer.

Various treatment modalities such as surgical incision, cauterization and laser excision were explained to the patient and guardian, they opted for laser excision. An informed consent was obtained and routine blood investigation was done.

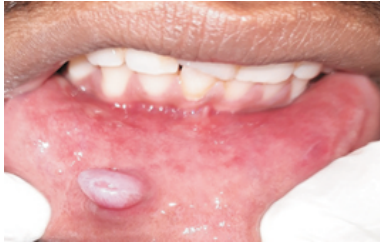

Fig.5- swelling seen on right side of lower lip

Before start of the procedure, lesion and the surrounding areas were sterilized with betadine solution and local infiltration was administered around the lesion with 2% lignocaine with 1:10000 epinephrine (NEON Laboratories, Mumbai, India). To start, the mucocele was pulled upward with forceps to create tension and circumferential incision was made initially with the help of diode laser [fig.-6]. Then lesion was excised using soft diode laser (Intense Medical & Dental Systems Limited, New Delhi, India) in wavelength of 980 nm with 300 micron tip diameter at 1.5 W in continuous mode there was immediate hemostasis with minimal bleeding. The postoperative field was treated with a defocused beam for enhanced surface hemostasis and coagulation [Fig.7]. The excised tissue was then sent for the histopathological analysis to confirmation of mucocele. Histopathological examination showed thick fibrous capsule lined the cystic cavity and foamy macrophages and chronic inflammatory cells contained by cystic lumen. With all this histopathological confirmation final diagnosis of mucous extravasation cyst was made. Sutures were not used and the wound was left for secondary healing. Instructions were given to the patient that included maintenance of the surgical site, soft diet and maintenance of oral hygiene and analgesic was prescribed. Patient was recalled after 1 week to monitor the healing. Healing progressed with no complications [Fig.10]. Healing was uneventful on 6 weeks of follow-up [Fig.11].

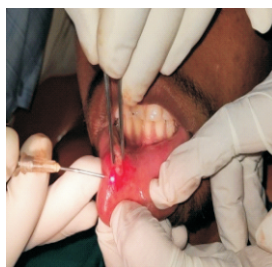

Fig.6- Intra operative photograph : mucocele excision with laser

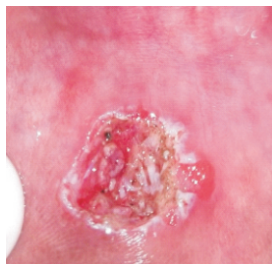


Fig.7- Immediate post-operative site after laser excision

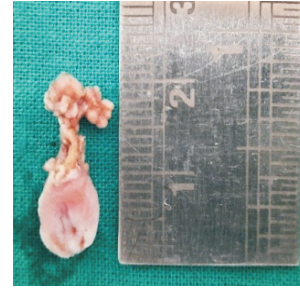


Fig.8- Excised lesion

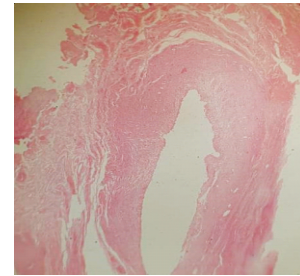


Fig.9- Histopathological aspect of mucocele

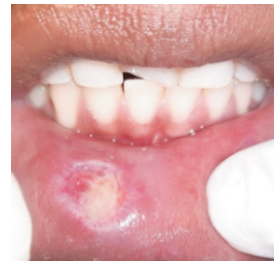

Fig.10- Post-operative site after 1 week

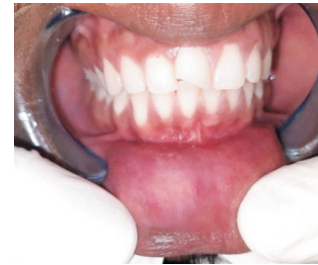

Fig.11-Post-operative after 6 weeks

Discussion:

Mucoceleles are seen in 0.4% to 0.8% of the general population with minimal difference between males and females [3]. They are asymptomatic painless swellings that are fluctuant because of mucinous contents. It is the most common salivary gland disorder and is second most common benign soft tissue tumor in the oral cavity [2]. According to Cohen et al. 82% of the lesions are prevalent on the lower lip followed by 8% in the buccal mucosa and 3% in the retromolar area [4].

Mucoceles are divided into retention mucoceles and extravasation mucoceles.[5] Both types may rupture spontaneously in a few hours after formation, releasing a viscous mucoid fluid. Though the lesion may decrease in size afterward, it usually relapses once the small perforation heals, because secretions are able to accumulate again.[6] The lesion may become more nodular and firmer in response to palpation.

Extravasation mucoceles most frequently occur on the labial mucosa (45-70%) where trauma is most common, but are also common on the buccal mucosa, tongue, floor of the mouth and retromolar region. [6]

Retention mucoceles occur most commonly on the floor of the mouth and palate. [4] Retention mucoceles are caused by the obstruction of minor salivary gland ducts by calculus or the formation of scar tissue around injured ducts. [7] As a result, saliva is blocked in the duct and accumulates, leading to swelling. Retention mucoceles are less common than extravasation mucoceles and occur more frequently in older populations. [2]

The differential diagnosis of mucocele include pathologies associated with the adipose tissue, blood vessels, nerves, connective tissue and salivary glands, namely, mucocele, fibroma, lipoma, mucus retention cyst, sialolith, phlebolith, salivary gland neoplasm, haemangioma and varices, specially when present in the lower lip region [8].

There are various treatment modalities such as cryosurgery [Twetman and Isaksson, 1990; Marcushamer et al., 1997; Yeh, 2000], intra-lesion injection of corticosteroids [Wilcox JW, History JE, 1978] [Luiz AC, 2008] and micro-marsupialisation [Delbem AC, 2000], marsupialization to prevent damage to neighboring anatomical structures [Baumash, 1992], conventional surgical removal of the lesion [Baumash, 2003] and laser ablation [Cecconi and Achilli, 2010].[9] Scalpel, laser and electro surgery techniques have been used for mucocele excision with variable success.[10] Patterns of healing were studied in rodent soft tissue, and wounds epithelialized fastest when treated by a laser, less quickly when treated by a scalpel and slowest when done by cryosurgery.[11]

The most common treatment modality is surgical excision for treating a mucocele. Surgical excision with removal of the involved accessory salivary gland has been suggested as the treatment of choice in many cases since it does not require extensive equipment, is cost-friendly, and can be performed by most of the trained dentists. Drawback of this procedure, it requires great control of the instrument with accurate tactile awareness. The chances for post-operative bleeding is also higher than with certain other treatment modalities such as the laser, as is the possibility of a more ulcerative appearance and possibly a longer healing time. [11,12]

Recently, soft tissue lasers have been recommended for the treatment of mucoceles. They provide satisfactory results with low recurrence rates and are well tolerated by the patients. The main

advantages of soft tissue lasers are minimal intra-operative bleeding due to laser intensely absorbed in hemoglobin, results in elevating the temperature and thus promoting coagulation and carbonization of soft tissues, such as the oral mucosa and results in minimum discomfort and scarring, reduced surgical time and accelerated healing time. This procedure does not require suturing due to protein denaturation caused during the contact of laser with the soft tissues.[13]

The excised tissue should always be submitted to the histopathological investigations to confirm the diagnosis and rule out the salivary gland tumors. Histologically, extravasation mucoceles are pseudocysts without defined walls. The extravasated mucus is surrounded by a layer of inflammatory cells and then by a reactive granulation tissue made up of fibroblasts caused by an immune reaction. Even though there is no epithelial covering around the mucosa, this is well encapsulated by the granulation tissue.[14]

Conclusion

Mucocele is a one of the most common benign lesion of the oral cavity. It is self limiting in nature. Most commonly it is associated with trauma and removal of the cause is an important aspect in the management of it to avoid relapse. In this case report we have talked about both kind of treatment modalities one case was treated with traditional method by surgical excision and second one treated by soft tissue diode laser excision. Surgical excision of mucocele by surgical blade is procedure sensitive contrasted with soft tissue laser because during the process bleeding from incision area occurs and visibility is compromised whereas in soft tissue laser excision the whole surgical process is blood less and healing period in soft tissue laser surgery is shorter when compared to scalpel excision. Thus, it can be concluded that the laser excision does have advantage over the traditional method in terms of healing and intra-operative.

References:

1. Baumash HD. Mucoceles and ranulas. *J Oral Maxillofac Surg.* 2003;61:369-78.
2. Yngue-Garcia J, Espana -Tost AJ, Berini-Aytis L, Gay-Escoda C. Treatment of oral mucocele-scalpel versus CO2 laser. *Med Oral Parol Oral Cir Bucal.* 2009 Sep 1;14(9),469-74.
3. Navya LV., et al. "Excision of Mucocele by Using Diode Laser: A Case Report". *Journal of Dental Sciences* 6.2 (2016).
4. Ellis GL., et al. "Obstructive disorders". In: *Surgical pathology of the salivary glands.* Philadelphia (PA): W.B. Saunders Co 1991:26-38.
5. Harrison JD. Salivary mucoceles. *Oral Surg Oral Med Oral Pathol.* 1975;39:268-78.
6. Burket LS, Greenberg MS, Glick M, Ship J. *Burket'S Oral Medicine.* Hmnilson, ON: BC Decker inc. 2008;11:202-3.
7. Reddy KMP, Hunasigi P, Varma AC, Kumar NHP, Kumar V. Mucocele on the lower lip treated by scalpel excision method: A Case Report. *JOADMS* 2015;1(3):62-66.

8. Daley TD. "The canalicular adenoma: considerations on differential diagnosis and treatment". *Journal of Oral and Maxillofacial Surgery* 1984;42(11):728-30
9. Bahadure R N, Fulzele P, Thosar N, Badole G, Baliga S. Conventional surgical treatment of oral mucocele: A series of 23 cases. *Europ Jour of Paed Dent* 2012;13(2):143-46
10. Pogrel MA, Yen CK, Hansen LS. A comparison of carbon dioxide laser, liquid nitrogen cryosurgery, and scalpel wounds in healing. *Oral Surg Oral Med Oral Pathol.* 1990; 69:269- 73.
11. Harris DM, Gregg RH II, McCarthy DK, et al. Laser-assisted new attachment procedure in private practice. *Gen Dent.* 2004; 52:396-403.
12. Cobb CM. Lasers in periodontics: a review of the literature. *J Periodontol.* 2006; 77:545-564.
13. Romanos G, Nentwig GH. Diode laser (980 nm) in oral and maxillofacial surgical procedures: Clinical observations based on clinical applications. *J Clin Laser Med Surg* 1999;17:193-7.
14. Baurmash HD. Mucoceles and ranulas. *J Oral Maxillofac Surg* 2003;61:369-78.