

Disease in Disguise: The Mystic Extra Oral Sinus-A Case Report.

Abstract :

Extra oral sinus tracts of odontogenic origin may be confused with a wide variety of diseases. Thus, the differential diagnosis of this clinical dilemma is of utmost importance in providing definitive treatment. Misdiagnosis of such condition may result in unnecessary treatments attributing to patient agony. For this reason, a dental origin must always be considered for any cutaneous lesion on the face or neck. Once the correct diagnosis is made, appropriate treatment, either through tooth extraction or endodontic therapy to eliminate the source of infection, is simple and effective.

Keywords Extra-oral sinus, Sinus tract, Cutaneous lesions, Endodontic Therapy, Diagnosis, Calcium Hydroxide

Introduction:

A sinus tract 'refers to a tract leading from an enclosed area of inflammation to an epithelial surface'.[1]

Cutaneous sinus tracts when occurring due to dental infection are often initially misdiagnosed because of their extra oral location, uncommon occurrence and the absence of acute symptoms in approximately half the individuals affected.[2] As a result, patients tend to seek medical care first and are given unnecessary medications, sometimes even surgical excisions, biopsies are done but all results in a failure. Thus accurate diagnosis is of paramount importance to achieve complete resolution and healing of such lesions.[3]

A chronic inflammation occurring from an infected or necrotic pulp is one of the major reasons for such extra oral cutaneous lesions of odontogenic origin.[4] This inflammation when spreads into the surrounding periodontal ligament and bone leads to bone resorption. Initially a localized periapical abscess is formed, but if left untreated at this stage, it can spread to deeper tissues and might perforate the cortical plate with the infection draining onto the mucosal or cutaneous surface along the path of least resistance.[5] Depending on the location of the perforation in the cortical plate and its relationship to facial muscle attachments, a sinus tract will drain intraorally or extraorally. When the apices of the teeth are above the maxillary muscle attachments and below the mandibular muscle attachments, the infection may drain extraorally.[6]

This case report presents a case of a patient having an extra-oral cutaneous sinus tract in the sub-mental region, which was initially misdiagnosed and was recurring. After being correctly diagnosed as a lesion occurring from a necrotic pulp, its management by conservative nonsurgical endodontic therapy of the offending teeth led to its complete healing.

Case Report:

A 22-year-old female patient reported with a chief complaint of persistent pus drainage from the chin region from past 1 year. Patient also presented with a CT scan of the head and neck region which revealed periapical pathology evident of bone loss in association with mandibular central incisors. (Figure 1)

Past dental history revealed that patient had a trauma to the chin region 8 years back. Medical history was non contributory.

On further enquiring about the past dental history it was revealed that patient had undergone surgical treatment for the lesion, twice in a

¹DEEKSHA KHURANA, ²DEEPAK RAISINGANI,
³ASHWINI B. PRASAD, ⁴SALONI GATTANI
¹⁻⁴Mahatma Gandhi Dental College & Hospital, Sitapura,
Jaipur

Address for Correspondence : Dr. Deeksha Khurana
Mahatma Gandhi Dental College & Hospital, Sitapura,
Jaipur
Email : Khurana.deeksha297@gmail.com

Received : 18 Nov. 2020, **Published :** 30 April 2021

Access this article online	
Website: www.ujds.in	Quick Response Code 
DOI: https://doi.org/10.21276/ujds.2021.7.1.19	

How to cite this article: Deeksha Khurana, Deepak Raisingani, Ashwini B. Prasad & Saloni Gattani. (2021). Disease in Disguise: The Mystic Extra Oral Sinus-A Case Report. UNIVERSITY JOURNAL OF DENTAL SCIENCES, 7(1) 102- 105

period of 1 year, by a general surgeon but the lesion was recurring. So she visited the general hospital where a CT scan of the head and neck region was advised and then was referred to the dental college.

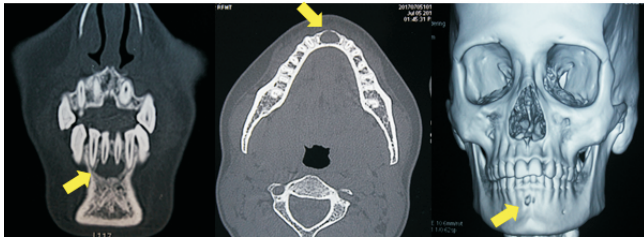


Figure 1: CT Scan Images showing bone loss in association with mandibular central incisors (marked with yellow arrow)

On clinical examination it was found that mandibular central incisors (teeth no. 31 & 41) were tender to percussion and on vitality testing they were found to be non vital. An extraoral sinus was present on the chin region (Figure 2). Radiographic examination revealed an ill-defined radiolucency in the periapical region of these teeth, suggestive of a periapical abscess (Figure 3). Thus a diagnosis of pulp necrosis with apical periodontitis was made. Treatment plan decided was non surgical root canal therapy in relation to these teeth. Patient was explained about the treatment procedure and an informed consent was obtained.

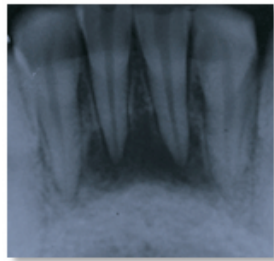
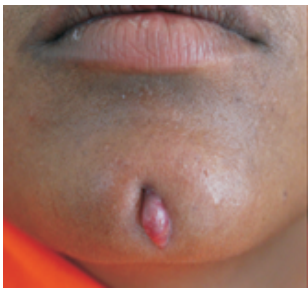

Fig. 2: Pre-operative Clinical image Fig. 3: Pre-operative IOPA

In the first appointment, under rubber dam isolation, access cavity was prepared in relation to teeth no. 31 & 41 and canal patency was established using #10 K SS file. Working length was determined using radiograph (Figure 4) and further confirmed with apex locator (J Morita). Shaping and cleaning was done till F1 Protaper files (Dentsply Maillefer) along with copious irrigation with 5.25% sodium hypochlorite. An interappointment dressing of calcium hydroxide was placed for 1 week and access cavity was closed. After a week when patient reported, the lesion on the chin had reduced in size indicative of healing (Figure 8a). On this visit, thorough irrigation with 2% chlorhexidine was done and a closed metapex dressing was given for 15 days (Figure 5). On 3rd visit i.e after 15 days when patient reported, she was completely asymptomatic, lesion on the chin has healed significantly (Figure 8b) and clinically the tooth was not tender, canals were dry, so the obturation was done with F1 cone using lateral compaction and resin sealer (figure 6a,b). Post endodontic restoration was done with restorative composite.

Patient was recalled after a week for evaluation. There were considerable signs of healing of the extra oral lesion with complete resolution of signs and symptoms.

At 1 year of follow up patient was found to be asymptomatic, healing of extraoral sinus had occurred with a minimal scar (Figure 8c). Radiographic examination also revealed repair of the periapical tissues (Figure 7)

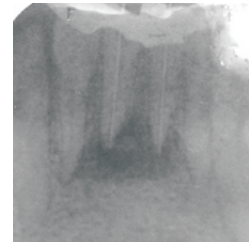


Figure 4: working length determination

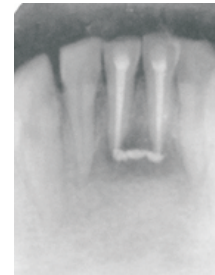


Figure 5: Metapex dressing given

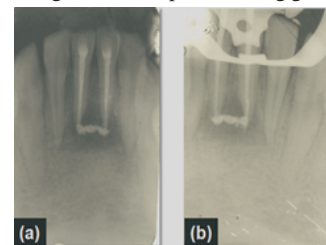


Figure 6: (a) Master cone (b) Obturation

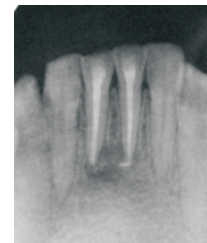


Figure 7: (a) IOPAR at 1 year of follow up

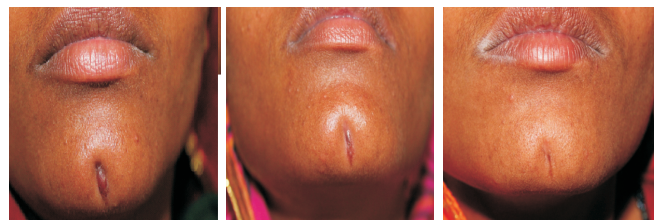

Figure 8: Healing of extra oral sinus : (a) after 7 days (b) after 15 days (c) after 1 year

Discussion:

Chronic infection around the apex of a dental root generally drain intraorally but in rare cases they appear as cutaneous lesions draining on the skin of face and neck through a sinus tract. However, these lesions can present a diagnostic dilemma because they often have a clinical appearance similar to other facial lesions and dental symptoms are not always present.[7]

In this present case also patient had undergone surgical excision of the lesion twice by a general surgeon but recurrence of the lesion had occurred. And only after the CT scans it was found that lesion is odontogenic in origin.

Thus for all the draining lesions on the facial skin, odontogenic origin should always be considered and evaluation must begin with a thorough patient history and awareness that any cutaneous lesion on the face and neck could be odontogenic in origin.[5]

If the sinus tract is patent, sinus tracing must be carried out with a gutta-percha point, or a similar radiopaque tracer. In addition, accurate pulp sensitivity tests must be performed to determine if the sinus tract is pulpal in origin. When correctly performed and adequately interpreted these tests will aid in arriving at an accurate diagnosis at an early stage. Thus will prevent unnecessary treatments and enhance healing.[8]

For differential diagnosis of such cutaneous sinus tract suppurative apical periodontitis, osteomyelitis, congenital fistula, pyogenic granuloma, infected cyst, salivary gland fistula, , and deep mycotic infection should be considered.[9]

The various case reports have suggested that approximately 80% of the cases are associated with mandibular teeth occurring in chin and submental region and 20% with maxillary teeth. The other uncommon locations are the cheek, canine space, nasolabial fold, nostrils, and inner canthus of the eye.[10]

In 1961, Bender and Seltzer reported that these sinus tracts are lined with granulation tissue and not epithelium , thus when correctly diagnosed and treated, a sinus tract is expected to disappear within 7 to 14 days.4 However, it has also been reported that when these sinus tract persists for longer, they are more likely to have an epithelial lining.[11]

The key principle to manage such lesions is to remove the source of dental infection. Thus conservative Nonsurgical Root Canal therapy is considered as the first choice of treatment, if the offending tooth is restorable. Appropriate cleaning, shaping, asepsis, sterilization of the root canal, and periradicular region and filling of the root canal determine the success of the treatment and good periapical healing.[12]

In the present case to achieve complete disinfection 5.25% sodium hypochlorite and 2% chlorhexidiene were used for irrigation and an interappointment dressing of calcium hydroxide was used as intracanal dressing. Complete healing of the extraoral sinus indicates the adequacy of the disinfection procedure and confirms the existing opinion for the management of such endodontic infections.

Dimpling and hyperpigmentation of the skin usually diminish slowly, and sometimes it remains on the face as a scar. In such cases surgical revision can be done for esthetic reasons.[13]

Conclusion:

Accurate diagnosis is the key to treat cutaneous sinus tracts. Dental origin must always be considered in differential diagnosis for all cutaneous sinus tracts occurring in head and neck region. Once identified as occurring from a necrotic pulp, endodontic therapy is the treatment of choice. The present case report demonstrates successful management of the cutaneous sinus tract of dental origin with minimal scar formation by non surgical conservative endodontic therapy.

References:

1. Cohenca N, Karni S, Rotstein I. Extraoral sinus tract misdiagnosed as an endodontic lesion. *J Endod* 2003; 29: 841-3.
2. Cantatore JL, Klein PA, Lieblch LM. Cutaneous dental sinus tract, a common misdiagnosis:A case report and review of the literature. *Cutis* 2002; 70: 264-7.
3. Sammut S, Malden N, Lopes V. Facial cutaneous sinuses of dental origin – A diagnostic challenge. *Br Dent J* 2013; 215 : 555-8.
4. Bender IB, Seltzer S. The oral fistula: Its diagnosis and treatment. *Oral Surg Oral Med Oral Pathol.* 1961; 14: 1367-76
5. Padhye L, Jagan IN, Unnikrishnan P, Mandke L, Kulkarni R, Toprani N. Management of extraoral sinus via nonsurgical root canal treatment. *Indian J Oral Health Res* 2018;4:66-9
6. Mittal, N., & Gupta, P. (2004). Management of Extra Oral Sinus Cases: A Clinical Dilemma. *Journal of Endodontics*, 30(7), 541–54
7. Abuabara A, Schramm CA, Zielak JC, Baratto-Filho F. Dental infection simulating skin lesion. *An Bras Dermatol* 2012; 87: 619-21.
8. JoseJA, Kumar RM,Jayasree S. Non Surgical Management of Long Standing Extra Oral Sinus in Submental Region –A Case Report. *IOSR Journal of Dental and Medical Sciences.*2016;15:117-20
9. Shweta Bansal, Ruchi Juneja, Gyanendra Mishra, & Akshay Nambiar. (2018). Significance of Correct Diagnosis of Odontogenic Extraoral Sinus: A Report Of Two Cases. *International Healthcare Research Journal*, 1(11), 334-338.

10. Dincol ME, Yilmaz B, Ersev H, et al. Treatment of extraoral cutaneous sinus tracts with non-surgical endodontic intervention: report of six cases. *J Istanbul Univ Fac Dent*. 2015;49(2):35–40.
11. Tian, J., Liang, G., Qi, W. et al. Odontogenic cutaneous sinus tract associated with a mandibular second molar having a rare distolingual root: a case report. *Head Face Med* 11, 13 (2015).
12. Goomer P, Jain R L. Non-surgical endodontic treatment of extraoral sinus with triple antibiotic paste and mineral trioxide aggregate obturation. *Indian J Oral Sci* 2013;4:95-8
13. Singh AK, Saxena A. Treatment of extraoral submental sinus tract associated with large periapical lesion of traumatized lower central incisors teeth by periapical surgery and demineralized freeze-dried bone allograft. *Natl J Maxillofac Surg* 2019;10:260-6