

## Conserving A Tooth In Esthetic Way: A Case Report

### ABSTRACT

Esthetics are the main concern for everyone in today's world. Clinicians nowadays are in a constant search for a durable as well as an esthetic restorative treatment. Tooth-colored restorations made from composite or ceramic material has solved many of these esthetic concerns. All ceramics with high strength are better alternative to composite, amalgam and gold for posterior tooth restoration. This case report presents a durable and conservative esthetic treatment for a broken tooth with BruxZir inlay

**Keywords:** BruxZir; Ceramics; Esthetic Treatment; Inlay

### Introduction:

Aesthetic treatment is one of the most required dental treatments in conservative dentistry. Aesthetics play an increasingly important role in the choice of dental restorations. Re-creating the original tooth as faithfully as possible is a challenging task for the operator. Colour, shape and the surface texture are very important in aesthetic characterization and personalizing a smile [1].

Various materials used are Glass ionomer cement, Composite resin, ceramic bonded to metal and All Ceramic. All ceramic material with high strength is becoming popular as aesthetic restoration [2]. The survival rate of Ceramic restoration and ceramic inlay shows 94 % for 4-5 years and 91 % up to 7 years respectively [1].

All ceramic material with high strength is a better alternative to composite, amalgam and gold. The introduction of tooth-colored restorations made from composite resin or ceramic has solved many of the esthetic concerns that patients have expressed over silver amalgams or gold alloys. These materials depend on an adhesive interface between the restoration and the remaining tooth structure and are therefore subject to the durability of that interface. In addition to dependence on an adhesive interface, these restorative

materials have unique characteristics that must be considered when restoring stress-bearing areas of the oral cavity [3].

The durability of the adhesive interface with enamel is very predictable. while, the adhesive attachment to dentin is not as predictable. Tooth-colored restorative systems are, therefore, technique sensitive and require greater attention to detail than restorative systems that do not require an adhesive interface [2].


BruxZir® is indicated for crowns, bridges, veneers, inlays and onlays, screw-retained implant crowns and full-arch implant prostheses. It is an esthetic alternative to PFM metal occlusal/lingual or full-cast restorations. BruxZir restorations are also ideal for patients lacking the preparation space for a PFM [4].

<sup>1</sup>POONIA, L., <sup>2</sup>RAISINGANI, D., <sup>3</sup>MITAL, P., <sup>4</sup>MITTAL, N.

<sup>1-4</sup>Department of Conservative Dentistry and Endodontics, Mahatma Gandhi Dental College and Hospital, Sitapura, Jaipur.

**Address for Corresponding :** Dr. Lalita Poonia  
Mahatma Gandhi Dental College and Hospital,  
Sitapura, Jaipur.  
Email : lalitapoonia000@gmail.com

**Received :** 31 August 2020, **Published :** 31 Dec. 2020

Access this article online	
<b>Website:</b> www.ujds.in	<b>Quick Response Code</b> 
<b>DOI:</b> https://doi.org/10.21276/ujds.2020.6.3.20	

**How to cite this article:** Poonia, L., Raisingani, D., Mital, P., & Mittal, N. (2021). Conserving a tooth in esthetic way - A case report. UNIVERSITY JOURNAL OF DENTAL SCIENCES, 6(3).

BruxZir® is a new category of dental zirconia made possible by years of research & development at Glidewell Dental. Advanced colloidal processing animates BruxZir zirconia with high-performing strength and lifelike translucency, and superior shading technology renders enhanced shade matching and consistency for even more beautiful results [4].

General performance trends can be assessed in terms of retention, color match, marginal discoloration (interfacial staining), recurrent caries, wear (loss of anatomical form or contour), marginal adaption (integrity), postoperative sensitivity, or other failures [2].

### Case Report

A 36-year-old female patient came to Department of Conservative Dentistry and Endodontics with the chief complaint of broken filling in right lower back tooth region (fig 1). Patient's medical history was noncontributory. Patient was interested in aesthetical durable restoration; it was decided to give all ceramic inlay with cusp capping as restoration.

The selected tooth was prepared according to the accepted tooth preparation principles using tapered diamond bur with rounded design(847KR018). For BruxZir Esthetic restorations, a minimum occlusal reduction of 0.7mm; 1.25mm is ideal, 1-1.5mm axial preparation and greater than 2-5° divergence per wall was given. For all walls, a 90-degree cavosurface margin was given because ceramic inlays are fragile in thin cross-section, also cleared the adjacent tooth by 0.2 to 0.5 mm.

After the cavity preparation impressions were made with polyvinyl siloxane impression material (Express 3M ESPE Dental Product St. Paul, MN, USA) (fig 3) and send to laboratory, where BruxZir zirconia prosthesis was prepared (fig 5). In laboratory – Image was scanned from the master cast (fig 4), milling of ceramic inlay was done with BruxZir CAD block (Ivoclarvivadent, Europe). After that BruxZirinlay were tried in mouth and any necessary adjustments to contacts and occlusion were done.

Zirconia primer, such as Z-Prime Plus (Bisco) or Monobond Plus (Ivoclar) were placed in the internal surface of BruxZir restoration and dried for 3-5 seconds with an air syringe. Restoration was cemented with RelyX plus luting cement and cleanup was done [6], radiograph was taken to confirm the proper cementation [7].

The patient was observed clinically after one month for restoration for pain, sensitivity, marginal adaptation, crack formation, fracture and discoloration (fig 8)

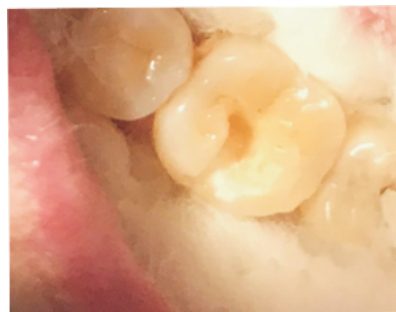

Fig:1- pre-operative

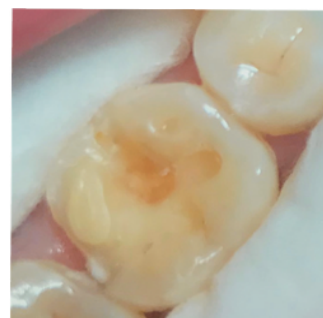

Fig:2- After preparation

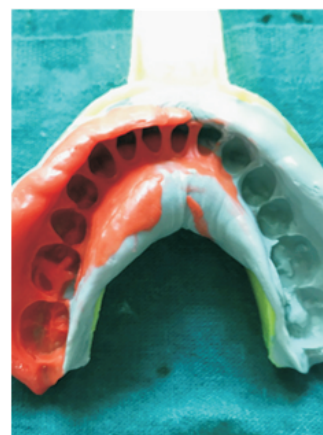

Fig:3- silicone impression



Fig:4- master cast

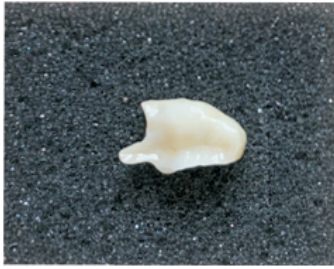

Fig:5- BruxZir prosthesis

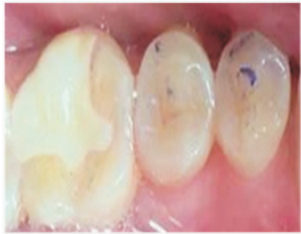

Fig:6- cementation of prosthesis

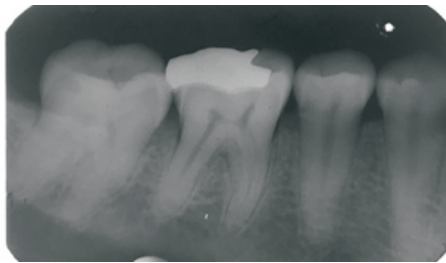


Fig:7- Radiograph after cementation of prosthesis

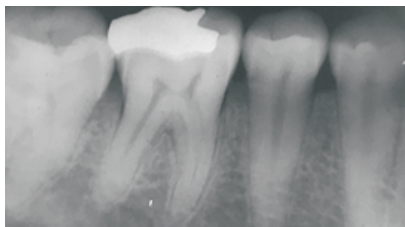

Fig: 8- After 1 month

### Discussion:

As the aesthetic aspect of dental care becomes important to patients, aesthetics is playing an increasingly important role in their choice for dental restorations. There are various options of aesthetic restoration for anterior teeth but aesthetic restoration for posterior teeth is a challenge for dental practitioner. Various aesthetic materials for posterior teeth include direct composite restoration, indirect composite restoration, metal ceramic restoration, all ceramic restoration [1]. All ceramic material with high strength provides good restorative alternative to moderate to large size carious lesion. Cavity preparation is also simple for example the line angles and point angles are rounded, floor and gingival seat area is

smooth and flat, cavo-surface angle is 90°, walls are diverging, isthmus is wide, if any undercuts are present can be blocked with glass-ionomer cement, 0.5mm clearance from adjacent teeth and all cavity walls should have the same path to draw [3].

In one study clinical assessment and survival rate ceramic inlay showed that the lack of recurrent caries, the only slight changes in marginal discoloration and color match, combined with the excellent longevity prove that ceramic inlays are a valuable tool for the restoration of posterior teeth [5].

Zirconia materials (BruxZir) has been developed with the aim of providing a stronger material for prosthetic dentistry. Ideal restorative materials should exhibit wear properties similar to those of human enamel and should not cause excess antagonist wear. Studies showed that monolithic polished zirconia prosthesis caused less wear on antagonist enamel than glazed ceramic metal crowns [4].

Currently, the Cerec system is the only commercially available CAD-CAM system which fabricates inlays, onlays, and veneers. The Cerec system (ceramic reconstruction) consists of a self-contained mobile unit with a miniature three-dimensional intraoral video camera, a monitor, keyboard, and a computer that controls the three-axis diamond-coated milling device. The inlay is milled from a homogenous, quality-controlled, factory-prepared standardized ceramic block within 4-7 minutes; the margins are then checked and the occlusal surface manually ground in. The advantages of Cerec inlays include long-lasting esthetic appearance and at least a 3-year material stability. Impressions of cavity preparations are unnecessary and laboratory procedures are not needed. In addition, as the restorations are cemented in one visit, the placing of temporary restorations is unnecessary. The unit is fully mobile from one dental office to another, and the number and duration of visits are less for the placement of Cerec inlays compared with other conventional direct and indirect inlay systems [5].

### Conclusion:

All ceramic restorations overcome the weakness of other esthetic restorative materials like Glass ionomer, composite resin and give good esthetic as well as function. Ceramic inlay is a better alternative as esthetic restoration compared to direct and indirect composite resin restoration for medium to large size carious lesion. Among different All ceramic material,

BruxZir monolithic zirconia inlay is best for marginal adaptation and function. When used in the correct circumstances, ceramic inlays may offer an attractive alternative to non-tooth-colored restorative materials.

### References

1. Priti Desai, Pathik Patel, Khyati Shah and Pankaj Patel. All Ceramic Inlay: A Case Report. *J Res Adv Dent* 2014;3(2):72-77
2. Lee w. Boushell and Andre v.Ritter. Ceramic Inlays: A Case Presentation and Lessons Learned from the Literature. *J EsthetRestorDent* 2000;21(2):77-88
3. Iysha Cawthon and Mary Anne S Melo. Esthetic Achievement with All-Ceramic Onlay Restorations for Rehabilitation of Compromised Fluorotic Permanent Molars. *EC Dental Science* 2017;11(5):177-183.
4. Sarikaya and Hyran. Effects of dynamic rasing on the wear and fracture strength of monolithic zirconia restorations. *BMC oral health* 2018;18(4):146
5. Mormann, Barbakow et al. CAD-CAM ceramic inlays and onlays: a case report after 3 years in place. *JADA* 1990;120(2):517-20