

“Clinical Versatility of Posterior Conservative Indirect Restorations- Case Series”

Abstract:

Molars in both the maxillary and mandibular arches are frequently subjected to heavy masticatory forces, making them more susceptible to cusp fractures—especially of the functional cusps, which bear the greatest load. In cases where these load-bearing areas are compromised, conventional direct restorations like amalgam or composite may prove inadequate. In such cases, dental inlays are valuable in preserving teeth damaged by extensive caries or mechanical preparation. Inlays are custom-crafted in the laboratory using materials like metal, composite resin, or ceramic & are then precisely bonded to the prepared tooth to restore its natural form, strength, and function. Present case series describe 3 cases of metal, composite & zirconia inlays respectively, patients presented with chief complaints of food lodgement & sensitivity to cold. The radiographic finding showed defect extended till dentin with no pulpal involvement. Diagnosis of reversible pulpitis and asymptomatic apical periodontitis was made. Treatment plan of metal, composite and zirconia inlays in 3 different cases was planned based on preferred esthetic needs and occlusion of the patients. This case series presents the use of inlays as a minimally invasive, indirect posterior restorations, highlighting their effectiveness in achieving long-lasting, well-fitting, and functional outcomes.

Key-words: Zirconia inlays, Composite inlays, Indirect restorations, metal inlays

Introduction:

Dental caries is a widespread public health problem influenced by diet, fluoride exposure, socioeconomic factors, age, health status, and access to dental care. Patients affected by dental decay or tooth loss often prefer treatment options that restore their teeth using the most durable materials & functionality along with aesthetics. [1] Dental inlays play a vital role in restorative dentistry, offering effective solutions for repairing and preserving damaged teeth.

Inlays are indirect restorations bonded to a tooth to replace lost structure. Traditionally, they are defined as intracoronal restorations that fit within the tooth cavity and restores one or more but not all of the cusps. [2] They are particularly preferred in cases such as posterior teeth with large proximal cavities and failed direct fillings involving multiple cusps. [3]

Gold inlays are the earliest form of dental castings, gold foil were employed for inlay fabrication. [4] Other common types

include cast metal inlays—fabricated from base metal alloys like nickel-chromium (Ni-Cr) and are highly valued for their exceptional mechanical strength, making them particularly suitable for posterior restorations that endure heavy occlusal forces [5]

Composite resin is another material used in inlay fabrication. According to Jose et al., the initial use of indirect composite

¹ANSHUM JAIN, ²CHARU THANVI,
³DEEPAK RAISINGANI, ⁴KHUSHI BHARGAVA
¹KM Shah Dental College and Hospital, Vadodara, Gujarat
^{2,3,4}Department of Conservative Dentistry and Endodontics,
Mahatma Gandhi Dental College and Hospital, Jaipur

Address for Correspondence: Dr. Khushi Bhargava
MDS (II Year)
Department of Conservative Dentistry and Endodontics,
Mahatma Gandhi Dental College and Hospital,
IICO Institutional Area, Sitapura,
Jaipur –302022, Rajasthan, India.
Email : khushibhargava99@gmail.com

Received : 13 Oct., 2025, **Published :** 31 March, 2026

Access this article online

Website:
www.ujds.in

DOI:
<https://doi.org/10.21276/ujds.2026.12.1.19>

How to cite this article: Anshum Jain, Charu Thanvi, Deepak Raisingani & Khushi Bhargava (2026); Clinical Versatility of Posterior Conservative Indirect Restorations- Case Series". UNIVERSITY JOURNAL OF DENTAL SCIENCES, 12(1).

resin dates back to the early 1980s.[6] They provide good wear resistance, and can be etched for micromechanical retention and silanated to improve bond strength. When composite resin is polymerized in the laboratory, most shrinkage occurs before placement in the tooth. As a result, only the thin luting layer undergoes contraction at the tooth–restoration interface, leading to smaller marginal gaps and a reduced risk of leakage, sensitivity, secondary caries, and discoloration.[7]

Indirect resin composites (IRCs) offer superior esthetics, better color stability, and less postoperative sensitivity. Adhesive cementation with dual-cure cements helps minimize marginal gaps and offsets polymerization shrinkage.[8]

Ceramic restorations have become increasingly popular for their esthetic appeal, durability, and biocompatibility. Adhesive cementation and acid-etch techniques enable strong bonding to tooth structures. Modern ceramics—hot-pressed, machinable, and feldspathic—offer mechanical and physical properties similar to enamel, excellent wear resistance, and thermal expansion compatible with natural teeth. Advances in fabrication methods, including CAD/CAM milling, pressable ceramics, and lost-wax techniques, have further improved their clinical performance and esthetic outcomes.[9]When the preparation margins are confined to enamel, they can significantly reduce microleakage.[10]

Despite their numerous advantages, the long-term success and durability of these restorations are highly dependent on proper case selection, the clinician's expertise, and the precision of the laboratory technician's work.[6]

Clinical Procedure:

CASE 1

A 21-year-old female patient presented to the Department of Conservative Dentistry and Endodontics with a chief complaint of food impaction in the lower left back tooth region since 1 month. Her medical and past dental histories were non-contributory. Intraoral examination revealed distoproximal caries in relation to tooth #36.(fig 1a)Pulp sensibility testing with a cold stimulus (Roeko Endo-Frost, Coltene) elicited a normal response. Radiographic assessment showed disto-proximal caries involving enamel and dentin irt tooth #36,(fig 1 b). Diagnosis of reversible pulpitis was made. The proposed treatment plan included an indirect cast metal inlay for tooth #36. The procedure was explained in detail, and informed

written consent was taken from the patient.

Caries was excavated, and an inlay cavity preparation was carried out [Figure 1c)maintaining a depth of 1–1.5 mm to ensure adequate resistance and retention form. Tapered fissure bur 169L (MANI, Inc., Tochigi, Japan) was used to achieve a wall divergence of 2-5 degrees, and finishing bur no. 8862 (Komet USA) was used to create bevels along the cavosurface margins. Following the preparation, an impression was made using polyvinyl siloxane material. The lab fabricated inlay was try- in to assess fit and occlusion, and subsequently luted by Glass ionomer cement type I (FujiCEM (GC)(fig 1 d). A postoperative radiograph was taken to evaluate the adaptation and marginal integrity of the

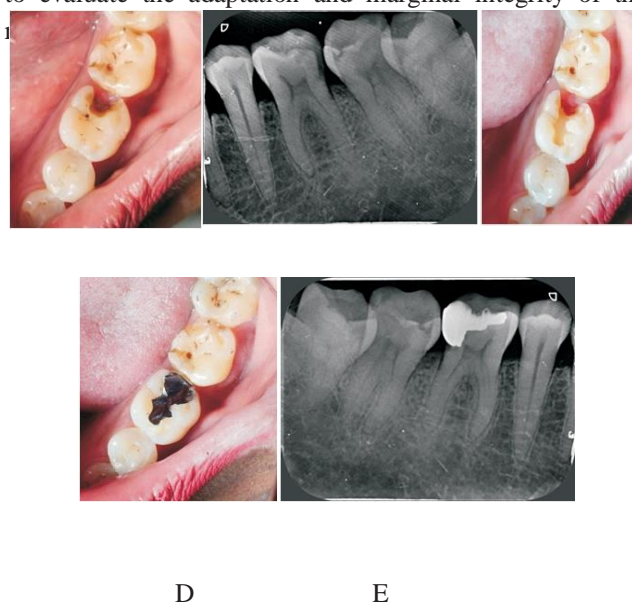

Figure 1: (a) pre-operative clinical picture #36(b) Pre op radiograph (c) Metal inlay cavity preparation (d) post-cementation clinical picture (e) Post cementation periapical radiograph

Case -2

A 24-year-old male reported to the Department of Conservative Dentistry and Endodontics with the chief complaint of food lodgment in the lower left posterior region since 20 days. His medical and past dental histories were non – contributory. Intraoral examination revealed distal-proximal caries in relation to tooth #36. Pulp sensibility testing with a cold stimulus (Roeko Endo-Frost, Coltene) elicited a normal response. Radiographic assessment showed disto-proximal caries involving enamel and dentin irt tooth #36.According to American Association of Endodontists a diagnosis of reversible pulpitis was made. The proposed treatment plan included an indirect composite resin inlay for tooth #36 The procedure was explained in detail, and

informed written consent was taken from the patient.

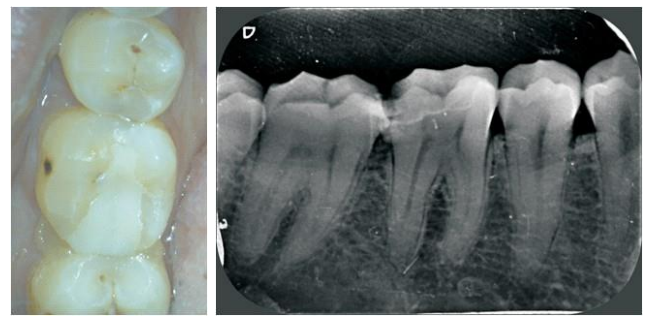
On first appointment:

Shade selection was done using the VITA Classical shade guide. Caries was excavated and cavity preparation was carried out following standard composite inlay preparation principles: internal angles were rounded, and the cavity walls were slightly flared at an angle of approximately 8–10 degrees. Minimum depth of 1.5 mm was maintained throughout. Areas with cavity walls approaching within 0.5 mm of the pulp were lined with calcium silicate cement for pulpal protection. Undercuts were blocked out using a suitable base or liner to facilitate proper inlay adaptation. Immediately after cavity preparation, the exposed dentin was sealed to establish a hybrid layer, ensuring protection against microbial penetration and reducing postoperative sensitivity during the provisional phase. Once dentin sealing was completed, impressions of both upper and lower arches were taken using polyvinylsiloxane material. After wards a direct provisional restoration was placed using temporary light cured resin based cement Clip “VOCO”.

On Second appointment:

The provisional restoration was removed and the cavity was cleansed

A total-etch technique was employed using 37% phosphoric acid gel, applied for 15 seconds, followed by thorough rinsing and gentle air drying. A uniform coat of primer (OptiBond FL Primer, Kerr/Sybron) was applied using a microbrush for 30 seconds and then gently air-dried. This was followed by the application of an adhesive layer (OptiBond FL, Kerr/Sybron), which was light-cured for 20 seconds. [Figure 2]. Same adhesive was applied on the internal aspect of composite inlay without being polymerized. Then the cementation was carried out by applying thin layer of resin luting cement (Variolink Esthetic LC, Ivoclar Vivadent) which was then light-cured through the restoration. The finishing and polishing was done using a composite finishing kit (shofu). The patient was informed about the limitation of the technique and was asked



C

D

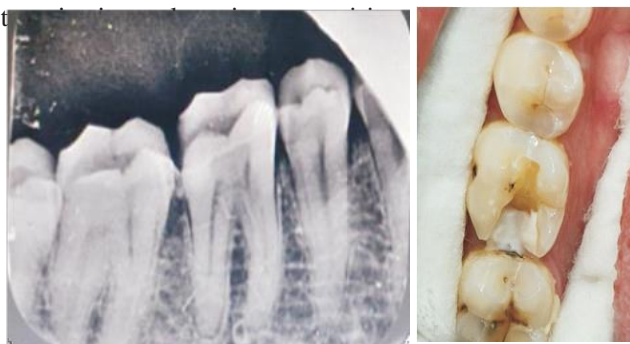Figure 2: (a) Pre- op radiograph #36 (b) Cavity preparation (c) Post-operative picture (d) Postcementation radiograph

Case - 3

A 32-year-old male reported to the Department of Conservative Dentistry and Endodontics with the chief complaint of food lodgment in the lower left posterior region since 15 days. His medical history and past dental history were non – contributory. Intraoral examination revealed distal-proximal caries in relation to tooth #36. Pulp sensibility testing with a cold stimulus (Roeko Endo-Frost, Coltene) elicited a normal response. Radiographic assessment showed mesio- proximal caries involving enamel and dentin irt tooth #36 [figure 3a]. A diagnosis of reversible pulpitis was made. The proposed treatment plan included an indirect zirconia inlay for tooth #36 The procedure was explained in detail, and informed written consent was taken from the patient

Caries was excavated and cavity was then prepared including smooth, rounded internal line angles to minimize stress concentration and well-defined margins placed in sound enamel [figure 3b]. An occlusal reduction of 1.5–2 mm was provided to ensure sufficient material thickness for strength. No bevels were placed on the cavosurface margins to ensure accurate seating and marginal adaptation of the zirconia inlay. A wall divergence of approximately 6–10° was maintained to provide mechanical retention, while a secondary flare was created on the proximal walls to facilitate smooth insertion and adaptation.

An elastomeric impression was made using Addition Silicone (Aquasil Ultra, Dentsply). The prepared tooth was cleaned and isolated, and the inlay was luted using light cure resin cement (RelyX U200, 3M ESPE). Tac curing was done for 1 second and then excess cement was removed after curing, followed by light polymerization for 40 seconds on all sides.



The zirconia inlay [figure 3d] demonstrated excellent marginal adaptation, strength, and esthetics. Although zirconia restorations can be technique-sensitive, difficult to adjust intraorally, and less translucent than glass ceramics, they remain a dependable and conservative option for restoring posterior teeth with proximal caries.

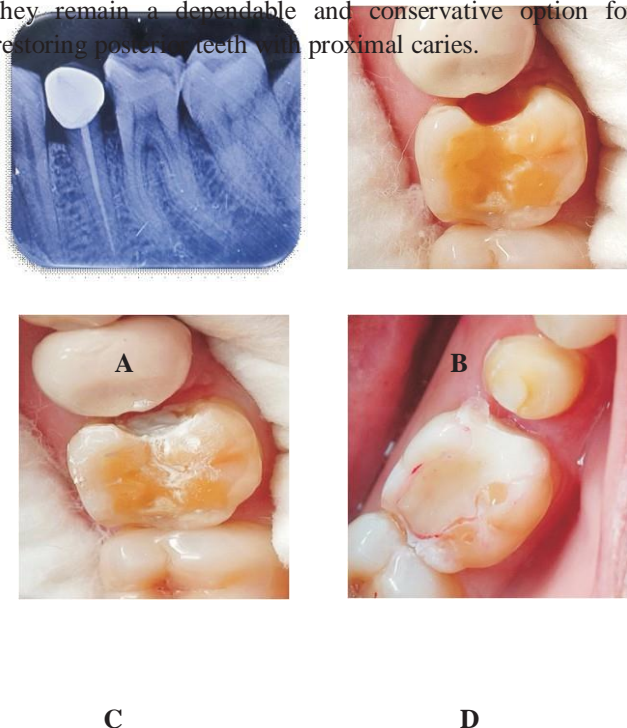


Fig 3 a) Pre op irt 36 b)Inlay cavity preparation c) MTA applied d) Zirconia inlay.

Discussion:

When cavities are excessively large, i.e. > ¼ of intercuspal distance or when bucco-lingual width of the restoration exceeds 50% of the intercuspal width of the tooth[11]direct composite restorations may not be a viable option due to their limited strength and potential for failure under functional stress. In such cases, indirect restorative techniques are often preferred, as they offer enhanced durability and structural support.[12]

Cast metal inlays are considered highly effective due to their superior compressive strength and precise marginal adaptation, allowing them to withstand significant occlusal forces with long-term reliability.[13] Though mechanically superior, they present certain limitations such as their metallic appearance, which restricts their use in esthetically demanding regions, and the requirement for greater tooth reduction[14]

An in vitro study by Magne et al.[15]highlighted that indirect inlays are a preferred option for managing extensive

restorations, particularly when cusp coverage is required in teeth with intact vitality. Indirect resin composites offer favorable mechanical characteristics and are capable of distributing occlusal stresses more evenly. According to Mandikos et al. [16], despite differences in wear resistance and material hardness, indirect resin composites have demonstrated reliable performance under simulated clinical wear conditions.

However, there are chances of potential wear and staining over time which should be considered in long term evaluations[14]

An ideal, customized smile depends on carefully matching the shade, contour, and surface texture of the restorative material, all while preserving as much healthy tooth structure as possible. Ceramic inlays have gained widespread popularity and acceptance in esthetic dentistry due to their ability to meet both functional and aesthetic demands.[17]

Modern ceramics are less brittle, demonstrate improved tensile strength, and exhibit reduced susceptibility to stress-related failures, making them highly suitable for long-term restorations. A few zirconia-based types are commonly used in dental practice. These include 3 mol% yttria-stabilized tetragonal zirconia polycrystals (3Y-TZP), magnesium-partially stabilized zirconia (Mg-PSZ), and zirconia toughened with alumina (ZTA). While zirconia typically appears as a dull white material and is relatively opaque—making it effective at masking discolored underlying tooth structures—many commercial systems incorporate structural shading to enhance its visual appeal. In terms of mechanical properties, zirconia is recognized for its exceptional strength and high fracture toughness, positioning it as one of the most reliable materials for dental restorations.[18]

The clinical performance of inlays varies with the material used: metal inlays provide excellent durability, composite inlays offer good esthetics, and zirconia inlays combine strength with superior esthetic outcomes. Material selection should therefore be guided by the balance between functional demands and esthetic requirements to achieve predictable long-term results.

Conclusion:

The choice of restorative material and technique plays a critical role in the long-term success of dental treatments, particularly in cases requiring significant structural

rehabilitation. While direct composite restorations offer a conservative approach, their mechanical limitations make them less suitable for extensive restorations. Indirect options—including cast metal inlays, resin-based inlays, and ceramic restorations—provide enhanced strength, durability, and esthetic outcomes. Ultimately, material selection should be guided by the specific clinical situation, occlusion, balancing the need for durability, esthetics, and preservation of natural tooth structure to ensure optimal patient outcomes.

References:

1. Tarek Y, AlDeghaishem N, AlNassar R, AlKhamisan A, Alzahrani KT. Indirect restorative materials and techniques selection and use by general dentists in Riyadh, Kingdom of Saudi Arabia. *Int J Innov Res Med Sci (IJIRMS)*. 2020 Dec;5(12).
2. S. Laghzaoui, A. Chafii, B. Maftouh, S. El Matoui, A. Bennani, and C. Author, "Stechnolock Journal of Dentistry Inlay, Onlay: Indication and Principle of Preparation Stechnolock J Dent," 2021. [Online]. Available: www.stechnolock.com
3. A. Jain, B. Rajkumar, S. Dubey, and P. S. Samant, "Indirect Restoration," *Acta Scientific Dental Sciencs*, pp. 113–120, Aug. 2022, doi: 10.31080/asds.2022.06.1441.
4. A. Jain, B. Rajkumar, S. Dubey, and P. S. Samant, "Indirect Restoration," *Acta Scientific Dental Sciencs*, pp. 113–120, Aug. 2022, doi: 10.31080/asds.2022.06.1441.
5. R. Rajput, A. Rawat, R. Babu, and A. Dhingva, "A Comparative Review of Cast Metal vs Composite Inlays: Which One Should I Prefer?," *Acta Scientific Dental Sciencs*, pp. 27–28, Jan. 2024, doi: 10.31080/asds.2024.08.1758.
6. J. Dubey, V. Rungta, R. Saini, A. Dutta, and P. Agrawal, "Replacement of Defective Restorations in Posterior Teeth: An Inlay Case Series," 2023. [Online]. Available: www.ijss-sn.com
7. D. Astekar, H. Vagarali, M. Pujar, V. Uppin, and M. Kittur, "Indirect Restorations-A Review," 2020. [Online]. Available: <https://cabidigitallibrary.org>
8. J. Mandlik, B. Vidyapeeth, M. Desai, R. Modak, and N. Shah, "Composite Inlay for Posterior Teeth: Few Case Reports Title: Composite Inlay for Posterior Teeth: Few Case Reports," *Article in IOSR Journal of Dental and Medical Sciences*, vol. 15, pp. 113–117, 2016, doi: 10.9790/0853-150402113117.
9. A. Mungee, N. Kararia, and S. Agrawal, "All Aspects Of Indirect Metal Free Restorations-A Review Article," *IOSR Journal of Dental and Medical Sciences (IOSR-JDMS) e-ISSN*, vol. 23, pp. 55–63, 2024, doi: 10.9790/0853-2307075563.
10. C. and L. M. Hopp, "Considerations for ceramic inlays in posterior teeth: A review," *Clin Cosmet Investig Dent*, vol. 5, pp. 21–32, Apr. 2013.
11. D. H. Ward, "Learning Objectives," 2003.
12. S. Pawar *et al.*, "Ceramic Inlays: A Case Report," *Cureus*, Sep. 2022, doi: 10.7759/cureus.29043.
13. A. Ray, K. Shetty, A. Garg, and S. Pradeep, "MANAGEMENT OF FRACTURED FUNCTIONAL CUSP OF MAXILLARY FIRST MOLAR: A CASE REPORT," *Int J Adv Res (Indore)*, vol. 8, no. 02, pp. 318–322, Feb. 2020, doi: 10.21474/IJAR01/10468.
14. R. and R. A. and B. R. Rajput, "{A Comparative Review of Cast Metal vs Composite Inlays: Which One Should I Prefer?," *{Acta Scientific Dental Sciencs}*, pp. 27–28, Jan. 2024.
15. belser U. magne pascal, "Porcelain versus composite inlays/onlays: effects of mechanical loads on stress distribution, adhesion, and crown flexure ," *international journal of periodontics & restorative dentistry*, vol. 23, no. 6, pp. 543–555, Dec. 2003
16. M. G. D. E. B. P. C. J. Mandikos MN, "A comparison of wear resistance and hardness of indirect composite resins," *journal of prosthetic dentistry*, vol. 85, no. 4, pp. 386–395, Apr. 2001.
17. V. L. C. M. F. M. D. A. F. V. M. D. M. D'Arcangelo C, "Adhesive Cementation of Indirect Composite Inlays and Onlays: A Literature Review," *Compend Contin Educ Dent.*, vol. 36, no. 8, pp. 570–577, Sep. 2015.
18. S. Kartika Sari, K. Ismiyatin, B. Aji Wibowo, and R. Amorita Miranda, "Case Report Zirconia Inlay on Vital Teeth with Profunda Caries." [Online]. Available: <https://e-journal.unair.ac.id/CDJ>