

Evaluation of Regenerative Endodontic Procedures in Mature Permanent Teeth with Necrotic Pulp and Periapical Radiolucencies: A clinical study

Abstract :

Aim: The aim of this study was to analyze the possibility of regenerative endodontic procedures (REPs) in mature permanent teeth with necrotic pulps and periapical radiolucencies compared to conventional root canal treatment (CRCT).

Methods: Sixty necrotic mature teeth having single root canals and periapical radiolucencies were randomized to one of two groups (n=30): REP and CRCT. During a 24-month period, clinical and radiological outcomes were evaluated. For statistical analysis, the unpaired or independent t-test and chi-square tests were utilized (all $p < .05$).

Results: After a 24-month period of follow-up, 11 teeth in the REP group were declared healed, and 12 teeth showed healing, 15 teeth in the CRCT group were declared healed, and 8 teeth exhibited healing, and difference was not statistically significant ($p > .05$). At follow-up visits, both groups showed absence and reduction in clinical signs/symptoms, with no significant difference ($p > .05$). At the end of 12 months, 42.3% of teeth in the REP group responded positively to sensibility tests with a significant difference compared to CRCT group ($p < .05$).

Conclusions: In the current study, a modified regenerative technique was utilized and according to the findings of this study, REPs may be employed as a potential therapeutic modality for necrotic mature teeth with periapical radiolucencies.

Key-words: Mature permanent teeth, Necrotic pulp, periapical radiolucencies, regenerative endodontic treatment, sensibility tests.

Introduction:

REPs were primarily pioneered by Nygaard- Ostby and Hjørtdal, who documented the possibility of repair when root canal bleeding was caused by overinstrumentation beyond the apex.[1,2] Previous research has revealed that the goal of REPs is to replace lost cells without claiming that this replacement is a complete replication of the once lost tissue.

The preservation of natural teeth remains a fundamental goal in the practice of endodontics. REPs are a feasible method for treating necrotic immature teeth ; this technique has a good survival and success rate.[3,4] REPs have recently been employed with effectiveness to treat necrotic mature teeth with apical periodontitis. [5-7] That led to the withdrawal of symptoms as well as the recovery from periodontitis. As a result, REPs have a similar primary goal to CRCT. The difference between CRCT and REP is that in the former, the sterile canals are filled with biologically compatible, non-vital

foreign type materials, whilst in the latter, the canals are filled with vital pulp like tissue. Innate immunity within the canal, which is suppressed following CRCT and can be regained following REPs.[8]

Previous research and the most recent findings support the utilization of REPs in mature permanent teeth . We compared the clinical and radiological outcomes of REPs to that of CRCT in the current study. There have not been many studies


¹VIVEK THAKUR, ²VISHAL SHARMA,
³ANSHU MINOCHA, ⁴SANJEEV CHAUHAN

Department of Conservative Dentistry and Endodontics,
Himachal Pradesh Government Dental College and
Hospital, Shimla

Address for Correspondence: Dr. Vivek Thakur
MDS,

Department of Conservative Dentistry and Endodontics,
Himachal Pradesh Government Dental College and
Hospital, Shimla-171001, Himachal Pradesh, India
Email : vtivekthakur421@gmail.com

Received : 1 August, 2024, **Published :** 30 June, 2025

Access this article online	
Website: www.ujds.in	Quick Response Code 
DOI: https://doi.org/10.21276/ujds.2025.v11.i2.7	

How to cite this article: Thakur, V., Vishal Sharma, Anshu Minocha, & Sanjeev Chauhan. (2025). Evaluation of Regenerative Endodontic Procedures in Mature Permanent Teeth with Necrotic Pulp and Periapical Radiolucencies: A clinical study. UNIVERSITY JOURNAL OF DENTAL SCIENCES, 11(2)

that directly compare them utilizing these modified regenerative methods that use induction of blood in combination with PRF as a scaffold, and the limited number of studies which have been done are not conclusive.

Methods And Materials:

The ethical committee of the institute approved the research protocol [HFW(GDC)B(12)50/2015-1048 dated January 1,2020]. The study included 60 teeth from 60 patients who reported to the Department of Endodontics (between January 2020 and December 2023).

The following criteria were used to select patients:

- 1) Patient of age group 15 to 35 years.
- 2) Necrotic mature teeth (anterior or premolars) encasing single root canal and periapical radiolucency more than 4 mm and less than 8 mm in diameter as judged using IOPA radiographs (E-SPEED; Carestream Health, New York, USA) in different angulation. The ultimate diagnosis of the patients selected for the study was necrosis of pulp with symptomatic or asymptomatic apical periodontitis with periapical radiolucencies. A negative response to electric pulp testing (EPT) [PARKELL; Farmingdale, New York, USA] followed by thermal (cold) testing (Endo-Frost; Coltène/Whaledent, Langenau, Germany) validated the diagnosis of pulpal necrosis.

The following were among the exclusion criteria:

1. Females who are pregnant.
2. A patient suffering from systemic medical conditions.
3. Tooth mobility.
4. Patients suffering from generalized chronic periodontitis.
5. Teeth that have previously treated with conventional root canal therapy.
6. Teeth with curved canals.
7. A periodontal pocket that is deeper than 3 mm.
8. Teeth having developmental anomalies (such as dense invaginatus or a palatogingival groove).

A sample number has been determined by the G*POWER 3.1.9.2 software. The overall sample number of 60 teeth was obtained using 5% alpha error and 80% power for the study. Once eligibility was established, block randomization was used to divide the teeth into two study groups (30 in each): group 1 (REP-group), while group 2 (CRCT-group). The person who carried out the randomization was blinded. Due to the different clinical methods used in each interventional group, patient and operator blinding was not achievable. Another person who worked on the data analysis was also blinded.

Patients were asked to comply with general directions and sign a form of written consent which described the purpose of the research and the procedure that would be performed. Before the procedure, IOPA radiograph was obtained for each selected tooth.

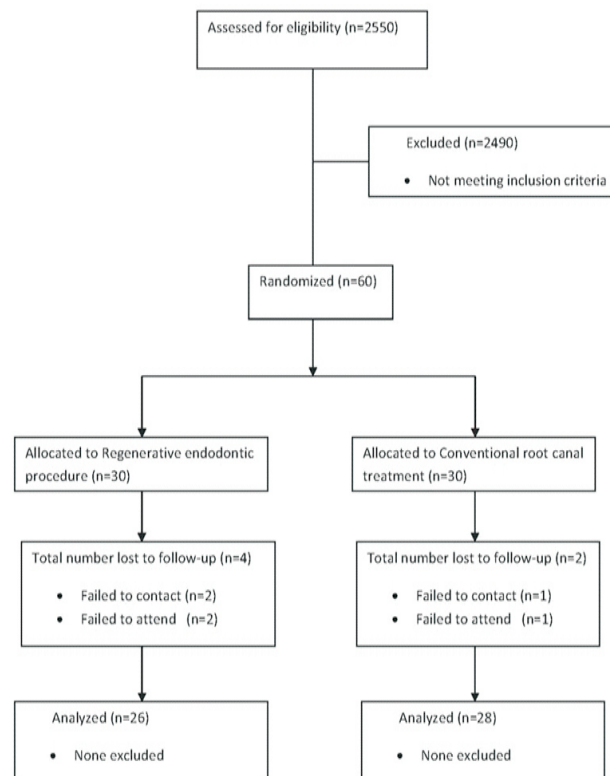


FIGURE 1:- The flow chart for this study

Rep Group:

The tooth was anesthetized using 2% lignocaine with 1:100,000 epinephrine (LOX 2%; Neon, Mumbai, India). Following isolation with rubber dam, a straight path to the root canal was obtained. The working length was calculated by an apex locator (iPex; NSK, Tochigi, Japan) and validated with an IOPA radiograph. By using the step-back approach, the canal was prepared with Ni Ti hand K-files (NITIFLEX; Dentsply, Ballaigues, Switzerland). The diameter of the apical foramen was increased to K-file size #60-80. The root canal was irrigated with 2.5 mL 1.5% sodium hypochlorite (NaOCL) solution after every file. After the final irrigation with 5.0 ml of 1.5% NaOCl (HYPOSOL; Prevest DenPro, Jammu, India) followed by the same amount of 17% EDTA (NEOEDTA; Orikam, Haryana, India), then paper points (COLTENE, Altstätten, Switzerland) was used to dry the canal. All irrigation was done using irrigation needles (25 and 30-G) with two side vents (RC Twents; Prime Dental, Maharashtra, India). The root canal was disinfected for one week with paste form of calcium hydroxide (RC Cal; Prime Dental), and the cavity was closed with provisional restoration (NEOTEMP; Orikam).

After 1 week, the tooth was asymptomatic, a local infiltration anesthesia without vasoconstrictor (LOXICARD 2%; Neon, Mumbai, India) was injected at the site. A rubber dam was applied and medicament was completely removed with 1.5% NaOCl solution irrigation. The canal was then irrigated with a 17% EDTA for 1 minute, then dried with paper points. With the intention of causing bleeding into the canal, a pre-curved K-file #20-#40 (MANI, Tochigi, Japan) was utilized 3 mm over the apical end into the periapical area.

The file was carefully turned 2 to 3 times in a clockwise direction before being removed in a counterclockwise direction. When bleeding was apparent in the canal, a sterile cotton ball was put 3 mm into the canal for 4 minutes to promote the construction of blood clot.

PRF was made with the method pioneered by Dohan et al. in France.[9] A sterile scissor was used to separate this freshly made PRF gel. PRF gel was compressed into a fibrin membrane with sterile gauge and cut into small fragments. Using a finger plugger, these fragments were placed slowly and carefully inside the canal beneath the CEJ. MTA (MTA Angelus; Londrina, Brazil) covering of 3 mm thickness was placed above a collagen barrier (Colo Plug; Cologenesis Healthcare Pvt. Ltd, Salem, India), the collagen barrier was placed on PRF as an internal matrix. A damp cotton ball was used to cover the MTA, and the cavity was temporized. The intermediate restoration and cotton ball were replaced after 1-2 days with a resin-based composite restoration (NT Premium; Coltene, Altstätten, Switzerland).

CRCT Group:

On the first appointment, the same root canal treatment strategies described in the REP group were applied. If no indication of infection was seen after 1 week, the medicament was taken out by irrigating the canal with 5 ml of 1.5% NaOCl then 17% EDTA solution for about 1 minute. After that to obturate the root canals, gutta-percha points (Dentsply, Switzerland) and a eugenol-based sealer were utilized, followed by replacement with a with a resin based composite restoration. The patients in both groups were monitored up to 24 months (6, 12,18 and 24 months), and the tooth was assessed clinically and radiographically in accordance to following criteria:

Postoperative Assessment Clinical Assessment:

Pain level, pain on palpation and percussion, swelling, sinus tract, tooth discoloration (color change during follow-up time). Pain levels before and after procedure, were assessed using a numerical visual analog scale (VAS). At the conclusion of the 1 year follow-up period, EPT and thermal (cold) tests were utilized to determine if the teeth in the REPs group had regained responsiveness or not.

Radiographic Assessment:

The pre-operative and post-operative IOPA radiographs for each tooth were obtained utilizing a paralleling approach with an X-ray film positioner, an exposure period of 0.14 seconds, and an exposure dose of 1.22 mGy. All radiographs were processed under similar conditions in the automatic X-ray processor. As previously mentioned, Image J software (Version 1.53e; National Institutes of Health, USA) was utilized to calculate the difference in lesion size from pre-operative and post-operative radiographic images.[10] As the tooth crown dimensions remains constant and not affected by healing of the perapical lesion. Thus, for standardization instead of measuring periapical lesion area, the ratio of periapical lesion area to tooth crown area was measured which was referred to as periapical lesion area score hypothetically.

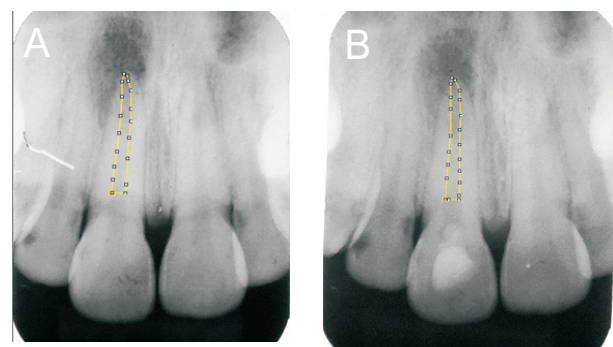
Mathematically, Periapical lesion area score = periapical lesion area in sq. mm ÷ tooth crown area in sq. mm

In addition, the periapical lesion scores were assigned using the following criteria:[11,12]

1. The periapical lesion was absent ; if the radiographic periodontal gap was less than 0.5 mm postoperatively.
2. Decrease in the periapical lesion; if postoperatively radiographic radiolucency was less than 20% preoperatively.
3. Increase in the periapical lesion; if postoperatively radiographic radiolucency was greater than 20% preoperatively.
4. Uncertain: if the situation cannot be described as the absence, diminution, or increase of radiolucency.

Cases with no or reduced radiolucencies (score 1 or 2) and no clinical symptoms were regarded successful. If a case had a radiographic score of 3 or 4, or if the tooth remained symptomatic, the case was considered failed.

The positive response to sensibility tests (EPT and cold tests) for the REP group was assessed at the completion of the 1 year follow-up period to assess regeneration.



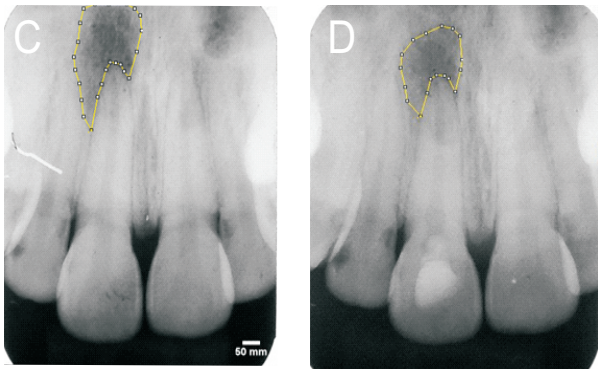


Figure 2. (A) Preoperative pixel measurement of root space dimension using image J software (B) Pixel measurement of root space dimension after regenerative endodontic procedure. Root space dimension remain unchanged after REP (C) Preoperative pixel measurement of lesion using image J software (D) Pixel measurement of lesion after regenerative endodontic procedure.

Statistical Analysis:

The data were tabulated using Excel (Microsoft, Redmond, USA). All statistical tests were done at a level of confidence of 95%, and p-values less than 0.05 ($p < 0.05$) were taken to be significant. SPSS Version 25.0 software (IBM, Armonk, USA) and MedCalc software (Ostend, Belgium) were used for the statistical analysis. Age, pain level, pain level on percussion and periapical lesion area score (periapical lesion area in sq. mm ÷ tooth crown area in sq. mm) were analyzed statistically with the unpaired or independent *t*-test.

All clinical signs and symptoms, sex, tooth number, post-operative radiographic outcome, sensibility testing response and success rate of both procedures (REPs and CRCT) were evaluated using chi-square tests. We hypothesized that statistically REPs success rate will have a non-significant difference compared to CRCT success rate in necrotic mature teeth with periapical radiolucencies.

Results;

Out of 60, 54 patients successfully completed the follow-up clinical and radiological examination, 26 teeth for regenerative endodontic treatment and 28 teeth for conventional root canal treatment (Figure-1). Three teeth in the REP group (tooth #9, #11, and #26) and five teeth in the CRCT group (tooth #10, 2 samples of #8, and 2 samples of #9) were considered failed (according to the periapical lesion criteria, score 1 or 2-successful and score 3 or 4-failed) due to persistent sinus tract and no healing throughout the duration of the follow-up, with no statistically significant differences ($P > .05$) among groups (Table 1).

TABLE 1 - Demographic Data, Swelling, Sinus Tract, Pain on palpation, Pain Level, and Pain Level on Percussion for Both the Groups

Group	Regenerative endodontic procedures	Conventional root canal treatment	P value
n	26	28	
Age	23.15 ± 4.71	24.04 ± 5.41	>.05
Sex, n (%)			
Male	15(57.7)	13(51.9)	>.05
Female	11(42.3)	15(48.1)	
Tooth number, n (%)			
6	1(3.8)	0(0)	>.05
7	4(15.4)	2(7.1)	
8	5(19.2)	7(25)	
9	3(11.5)	3(10.7)	
10	3(11.5)	7(25)	
11	2(7.7)	1(3.6)	
20	0(0)	1(3.6)	
22	1(3.8)	0(0)	
24	3(11.5)	2(7.1)	
25	2(7.7)	5(17.9)	
26	1(3.8)	0(0)	
27	1(3.8)	0(0)	
Swelling, n (%)			
Pre-operative	9(34.6)	14(50)	>.05
After procedure	0(0)	2(7.1)	>.05
Sinus tract, n (%)			
Pre-operative	9(34.6)	6(21.4)	>.05
After procedure	5(19.2)	3(10.7)	>.05
Pain on palpation, n (%)			
Pre-operatively	9(34.6)	14(50)	>.05
7 th day post-operatively	0(0)	0(0)	>.05
Pain level			
Pre-operatively	3.50 ± 2.75	3.25 ± 2.59	>.05
7 th day post-operatively	0.00 ± 0.00	0.00 ± 0.00	>.05
Pain level on percussion			
Pre-operative	3.50 ± 2.86	3.18 ± 2.57	>.05
7 th day post-operative	0.00 ± 0.00	0.00 ± 0.00	>.05

TABLE 2 - Findings of the Study Groups both clinically and radiographically

Group	Regenerative endodontic procedures	Conventional root canal treatment	P value
n	26	2	
Success cases n (%)	23(88.5)	23(82.1)	>.05
Failed cases n (%)	3(11)	5(17.9)	>.05
The total number of teeth responded to EPT and cold test n (%)	11(42.3)	0(0)	<.05
Post-operative radiographic findings as per scoring criteria, n (%)			
Absence of the periapical lesion	11(42.3)	15(53.6)	>.05
Decrease in the periapical lesion	12(46.2)	8(28.6)	
Increase in the periapical lesion	0(0)	0(0)	
Uncertain	3(11.5)	5(17.9)	

*EPT, electric pulp testing

Results :

Out of 60, 54 patients successfully completed the follow-up clinical and radiological examination, 26 teeth for

regenerative endodontic treatment and 28 teeth for conventional root canal treatment (Figure-1). Three teeth in the REP group (tooth #9, #11, and #26) and five teeth in the CRCT group (tooth #10, 2 samples of #8, and 2 samples of #9) were considered failed (according to the periapical lesion criteria, score 1 or 2-successful and score 3 or 4-failed) due to persistent sinus tract and no healing throughout the duration of the follow-up, with no statistically significant differences ($P > .05$) among groups (Table 1).

The absence of the periapical lesion and decrease in the periapical lesion were detected in 42.3% and 46.2% of REP-treated teeth, respectively. The periapical lesion was absent or decreased in 53.6% and 28.6% of the CRCT-treated teeth, respectively. The difference in postoperative radiographic results between the REP and CRCT groups was not statistically significant ($P > .05$) (Table 2). Clinical and radiographic evaluations determined that, 82.1% of CRCT-group teeth and 88.5% of REP-group teeth were categorized as successful ($P > .05$) (Table 2) and (Figure 3A-I). In REP-group, 42.3% of teeth responded positively to EPT and cold tests. There was no such findings reported in CRCT-group.

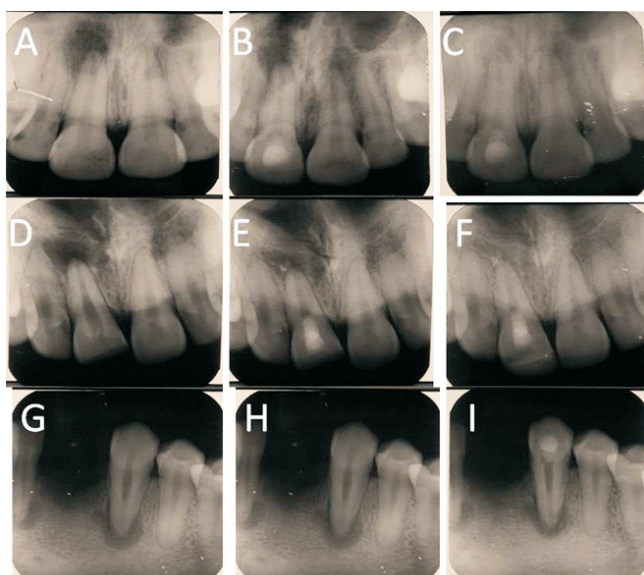


FIGURE 3. (A) A maxillary central incisor (#8) with periapical radiolucency in an 23-year old man. (B) The 6-month follow-up period reveal a significant decrease in periapical radiolucency after REPs. (C) The 24-month follow-up period revealed complete resolution of periapical radiolucency. Furthermore, the tooth responded to sensibility tests (EPT and cold) at the conclusion of 12-month follow-up period. (D) A maxillary central incisor (#8) with periapical radiolucency in an 19-year old man. (E) The 6-month follow-up periods reveal a significant decrease in periapical

radiolucency after REPs. (F) The 24-month follow-up period revealed complete resolution of periapical radiolucency. In addition, the tooth responded to sensibility tests at the conclusion of 12-month follow-up period. (G) A mandibular canine (#22) with periapical radiolucency in an 24-year old man. (H) The 6-month follow-up periods reveal a significant decrease in periapical radiolucency after REPs. (I) The 24-month follow-up period revealed complete resolution of periapical radiolucency. However, the tooth not responded to sensibility tests at the conclusion of 12-month and 24-month follow-up period.

Discussion:

Traditional root canal therapy has been utilized in the past to treat necrotic mature teeth, with predictable results.[13] The current study compared healing results clinically and radiographically to determine whether REPs provide an alternate therapeutic option to CRCT for necrotic mature permanent teeth.

Petrino et al.[14] observed difficulty in initiating blood to flow into the root canal even after the administration of local anesthetic without vasoconstrictor, and failure regeneration treatments were linked to the difficulty of causing bleeding inside the canal reported by Ding RY et al.[3] In the present research, improved regenerative endodontic technique was conducted using both induced bleeding to generate a blood clot (BC) in the canal combined with PRF as a scaffold and source of growth factors. This was reinforced by a previous study by Zhou et al.[15] in which BC + PRF as scaffolds demonstrated effective periapical healing in REPs.

Mature permanent teeth have narrower apical cell movement pathways than immature teeth. However, El-Kateb et al.[16] using MRI assessment, found that the widening of the foramen had no impact on the ingrowth of pulp-like tissues in mature teeth utilizing REPs. In addition, Shah N et al.[5] increased the foramen to a #30 K-file in REP investigations of necrotic mature teeth, Paryani K et al.[6] to a #60 K-file, and Saoud TMA et al.[7] to a #35 K-file. On the basis of these findings, it was suggested that foramen widths between 0.3 to 1.0 mm may enhance the movement of new cells inside the canal following REPs.

Because mature permanent teeth exhibit more complicated root canal characteristics, so adequate disinfection is more challenging. According to Martin et al.[17] more NaOCl concentrations have a detrimental effect on the viability and growth of stem cells of the apical papilla (SCAPs). This outcome can be avoided by utilizing 1.5% NaOCl, followed by 17% EDTA. In addition, the administration of 17% EDTA showed enhanced SCAP longevity as well as substantially correcting the adverse effects of NaOCl. Furthermore, Zeng Q

et al.[18] concluded that irrigation of root sections with 1.5% NaOCl combined with 17% EDTA released a much larger amount of transforming growth factor- β 1. As a result, this irrigation approach could be useful in regenerative endodontic procedures.

According to the study by Sjogren et al, canals were medicated with Ca(OH)_2 for only one week in both groups.[19] Furthermore, Althumairy et al.[20] showed that it promotes SCAP survival at all tested concentrations. Furthermore, calcium hydroxide is beneficial as an intracanal medication for growth factor release and cell survival.[21]

The most effective endodontic treatment is incomplete unless a bacteria-tight coronal seal is created to prevent reinfection. In the present study, MTA was placed over a collagen barrier that covered the scaffolds and control the placement of coronal MTA. MTA is biologically compatible, forming a bacteria-free coronal seal as well as a bioactive material with hard-tissue conductive and inductive capabilities.[22] MTA-angelus was preferred for this study because of its shorter setup time (15 minutes approx.) and improved handling characteristics.[23]

Discoloration following REPs is a significant patient-oriented consequence. The cause of crown discoloration following REPs is multifaceted. The inclusion of minocycline in antimicrobial intracanal medication, the bleeding induced during procedures, and the use of MTA as a coronal barrier can all contribute to it. In the current study, calcium hydroxide was employed for the intracanal medication rather than antibiotic mixture. Studies showed that both white and gray MTA can induce some amount of color change in tooth structure.[24] In the current study, 38.5% of REP-treated teeth showed discoloration. To minimize the risk of discoloration, use of Biodentine could have been beneficial instead of MTA, [25] which is a limitation of the current study.

Radiographic assessment is of critical significance to visualize periapical bone lesions for interpreting the progression of bone healing. In the present study, IOPA (intraoral periapical) radiographs were used to evaluate the periapical lesion size. They offer two-dimensional knowledge of three-dimensional structures, which is also a shortcoming of this study. Further research using CBCT is needed in this area.

The initial result evaluation of REPs in necrotic mature teeth, however, was primarily relied on healing of periapical lesions radiographically and clinical symptoms before teeth started to respond positively to sensibility tests. Vital tissues are generally vascularized, nerve-innervated, and responsive to sensibility tests, although this does not always imply

regeneration of more structured vital pulp tissue. In the present study, at the conclusion of the 1 year follow-up period, 11 of 26 REP-group cases (42.3%) restored tooth sensibility by using blood clot (BC) and PRF-based regenerative endodontic treatment, showing the presence of host's innate vital tissues into the root canal.

This is consistent with the outcomes of El-Kateb et al.^[16] and Arslan et al.^[10], who found that more than 60% and 50% of their patients, respectively, responded to sensibility tests at the conclusion of a follow-up period of 12-month in mature teeth.

Despite positive clinical outcomes for mature teeth treated with REPs and CRCT, some cases reported failure. In this study, 3 of 26 REP-treated (11.5%) teeth failed, compared to 5 of 28 CRCT-treated (17.9%) teeth. A systematic analysis revealed that in 79% of cases, sustained infection were the primary manifestation of REPs failure[26] To preserve the viability of SCAPs, a lower concentration of different medications and irrigants is indicated in REPs.[18] Therefore, the disinfecting approach for REPs should be meticulously reviewed in order to create a suitable equilibrium between root canal system disinfection and stem cell survival, which may lead to a beneficial long-term outcome. Further studies are warranted in this area.

Conclusion:

Within the scope of the current study, it is possible to conclude that REPs provide a favorable treatment outcome equivalent to CRCT and possess the capability to be considered as feasible alternative treatment options for mature permanent teeth with necrotic pulp and periapical radiolucencies. Further research with bigger sample sizes and prolonged periods of follow-up are needed to support the outcomes of present study before widespread clinical applicability in mature permanent teeth.

References:

1. Ostby BN. The role of the blood clot in endodontic therapy. An experimental histologic study. *Acta Odontol Scand* 1961;19:324–53.
2. Nygaard-Ostby B, Hjortdal O. Tissue formation in the root canal following pulp removal. *Eur J Oral & Sci* 1971;79:333–49.
3. Ding RY, Cheung GS, Chen J, et al. Pulp revascularization of immature teeth with apical periodontitis: a clinical study. *J Endod* 2009;35:745–9.

4. Li L, Pan Y, Mei L, Li J. Clinical and radiographic outcomes in immature permanent necrotic evaginated teeth treated with regenerative endodontic procedures. *J Endod* 2017;43:246–51.
5. Shah N, Logani A. SealBio: a novel, non-obturation endodontic treatment based on concept of regeneration. *J Conserv Dent* 2012;15:328–32. 23.
6. Paryani K, Kim SG. Regenerative endodontic treatment of permanent teeth after completion of root development: a report of 2 cases. *J Endod*. 2013 Jul;39(7):929-34. 24.
7. Saoud TMA, Sigurdsson A, Rosenberg PA, et al. Treatment of a large cystlike inflammatory periapical lesion associated with mature necrotic teeth using 76 regenerative endodontic therapy. *J Endod* 2014;40:2081–6.
8. Saghiri MA, Asatourian A, Sorenson CM, Sheibani N. Role of angiogenesis in endodontics: contributions of stem cells and proangiogenic and antiangiogenic factors to dental pulp regeneration. *J Endod* 2015;41:797–803.
9. Dohan DM, Choukroun J, Diss A, et al. Platelet-rich fibrin (PRF) : a second generation platelet concentrate—part I: technological concept and evolution. *Oral Surg Oral Med Oral Pathol Oral Radiol Endod* 2006;101:E37-44.
10. Arslan H, Ahmed HMA, Şahin Y, Doğanay Yıldız E, Gündoğdu EC, Güven Y, Khalilov R. Regenerative Endodontic Procedures in Necrotic Mature Teeth with Periapical Radiolucencies: A Preliminary Randomized Clinical Study. *J Endod*. 2019 Jul;45(7):863-872.
11. Liang YH, Jiang LM, Jiang L, et al. Radiographic healing after a root canal treatment performed in single-rooted teeth with and without ultrasonic activation of the irrigant: a randomized controlled trial. *J Endod* 2013;39:1218-25
12. Liang YH, LiG, Wesselink PR, Wu MK. Endodontic outcome predictors identified with periapical radiographs and cone-beam computed tomography scans. *J Endod* 2011;37:326-31.
13. Ng YL, Mann V, Gulabivala K. Outcome of primary root canal treatment: systematic review of the literature—part 1. Effects of study characteristics on probability of success. *Int Endod J* 2007;40:912–39.
14. Petrino JA, Boda KK, Shambarger S, Bowles WR, McClanahan SB. Challenges in regenerative endodontics: a case series. *J Endod*. 2010 Mar;36(3):536-41.
15. Zhou R, Wang Y, Chen Y, Chen S, Lyu H, Cai Z, Huang X. Radiographic, histologic, and biomechanical evaluation of combined application of platelet-rich fibrin with blood clot in regenerative endodontics. *J Endod*. 2017 December;43(12):2034-2040.
16. El-Kateb NM, El-Backly RN, Amin WM, Abdalla AM. Quantitative Assessment of Intracanal Regenerated Tissues after Regenerative Endodontic Procedures in Mature Teeth Using Magnetic Resonance Imaging: A Randomized Controlled Clinical Trial. *J Endod*. 2020 May;46(5):563-574.
17. Martin DE, De Almeida JF, Henry MA, Khaing ZZ, Schmidt CE, Teixeira FB, Diogenes A. Concentration-dependent effect of sodium hypochlorite on stem cells of apical papilla survival and differentiation. *J Endod*. 2014 Jan;40(1):51-5.
18. Zeng Q, Nguyen S, Zhang H, Chebroly HP, Alzebdeh D, Badi MA, Kim JR, Ling J, Yang M. Release of Growth Factors into Root Canal by Irrigations in Regenerative Endodontics. *J Endod*. 2016 Dec;42(12):1760-1766.
19. Sjögren U, Figdor D, Spångberg L, Sundqvist G. The antimicrobial effect of calcium hydroxide as a short-term intracanal dressing. *Int Endod J*. 1991 May;24(3):119-25.
20. Althumairy RI, Teixeira FB, Diogenes A. Effect of dentin conditioning with intracanal medicaments on survival of stem cells of apical papilla. *J Endod*. 2014 Apr;40(4):521-5.
21. Galler KM, Buchalla W, Hiller KA, Federlin M, Eidt A, Schiefersteiner M, Schmalz G. Influence of root canal disinfectants on growth factor release from dentin. *J Endod*. 2015 Mar;41(3):363-8.
22. Torabinejad M, Parirokh M. Mineral trioxide aggregate: a comprehensive literature review--part II: leakage and biocompatibility investigations. *J Endod*. 2010 Feb;36(2):190-202.
23. Oliveira MG, Xavier CB, Demarco FF, Pinheiro AL, Costa AT, Pozza DH. Comparative chemical study of MTA and Portland cements. *Braz Dent J*. 2007;18(1):3-7.
24. Belobrov I, Parashos P. Treatment of tooth discoloration after the use of white mineral trioxide aggregate. *J Endod*. 2011;37(7):1017-20.
25. Marconyak LJ Jr, Kirkpatrick TC, Roberts HW, et al. (2016) A Comparison of Coronal Tooth Discoloration Elicited by Various Endodontic Reparative Materials. *Journal of Endodontics* 42, 470 - 3. 25.
26. Almutairi W, Yassen GH, Aminoshariae A, Williams KA, Mickel A. Regenerative Endodontics: A Systematic Analysis of the Failed Cases. *J Endod*. 2019 May;45(5):567-577.